CARDIOMIOPATÍAS:

Enfermedades del músculo cardiaco

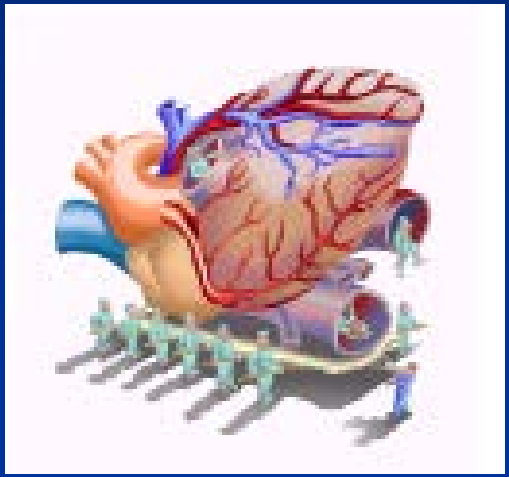

Dr. Ramiro Lara R.

CARDIOMIOPATIAS:

Enfermedades de músculo cardiaco de causa desconocida.

GOODWIN

CARDIOMIOPATIAS

CLASIFICACION FUNCIONAL:

1.- CARDIOMIOPATIA DILATADA

2.- CARDIOMIOPATIA HIPERTROFICA

3.- CARDIOMIOPATIA RESTRICTIVA

CARDIOMIOPATIA DILATADA:

- ALCOHOLISMO CRÓNICO
- ETAPA TARDÍA INFECCION VIRAL
- LATINOAMÉRICA: ENF. CHAGAS
- ENFERMEDAD AUTO-INMUNE SIDA
- CMD POSTPARTO
- TIROTOXICOSIS
- TOXOPLASMOSIS

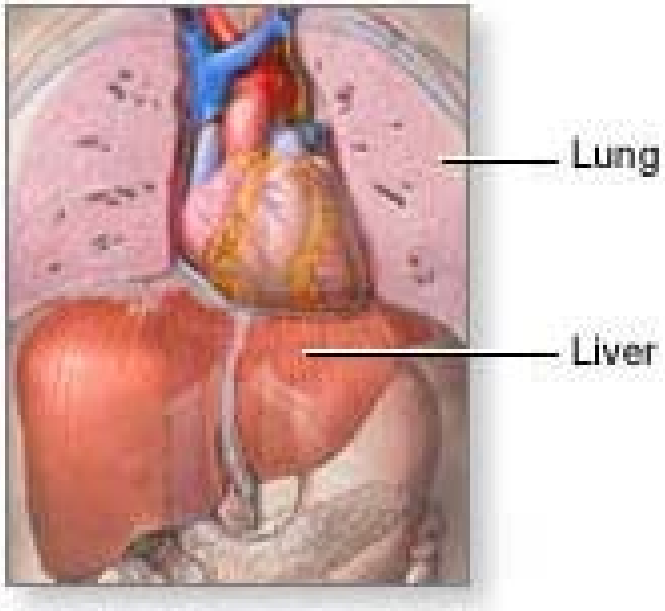
Lung
Liver

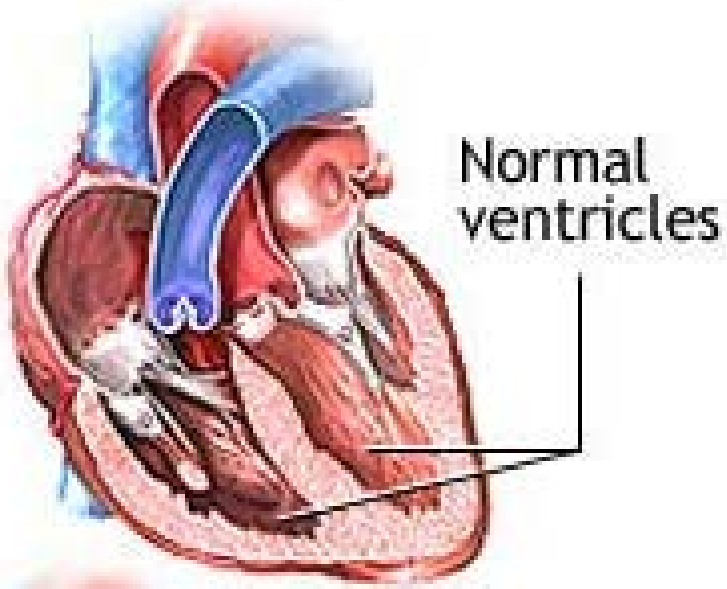
Normal ventricles

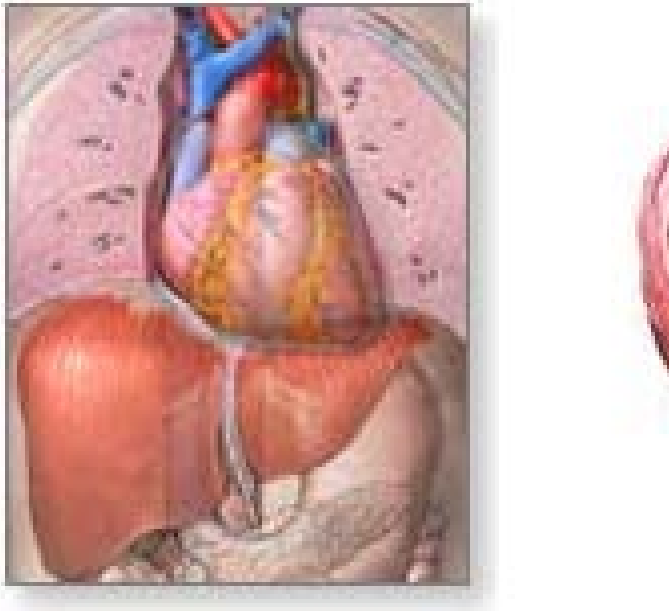

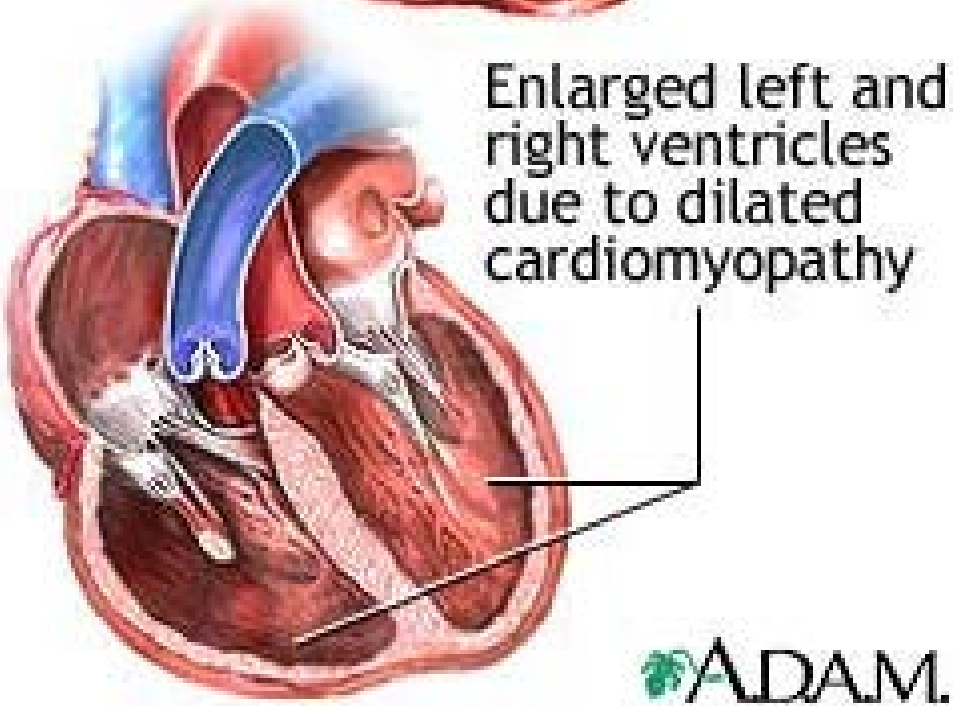
Enlarged left and right ventricles due to dilated cardiomyopathy

A.D.A.M.

20 mm

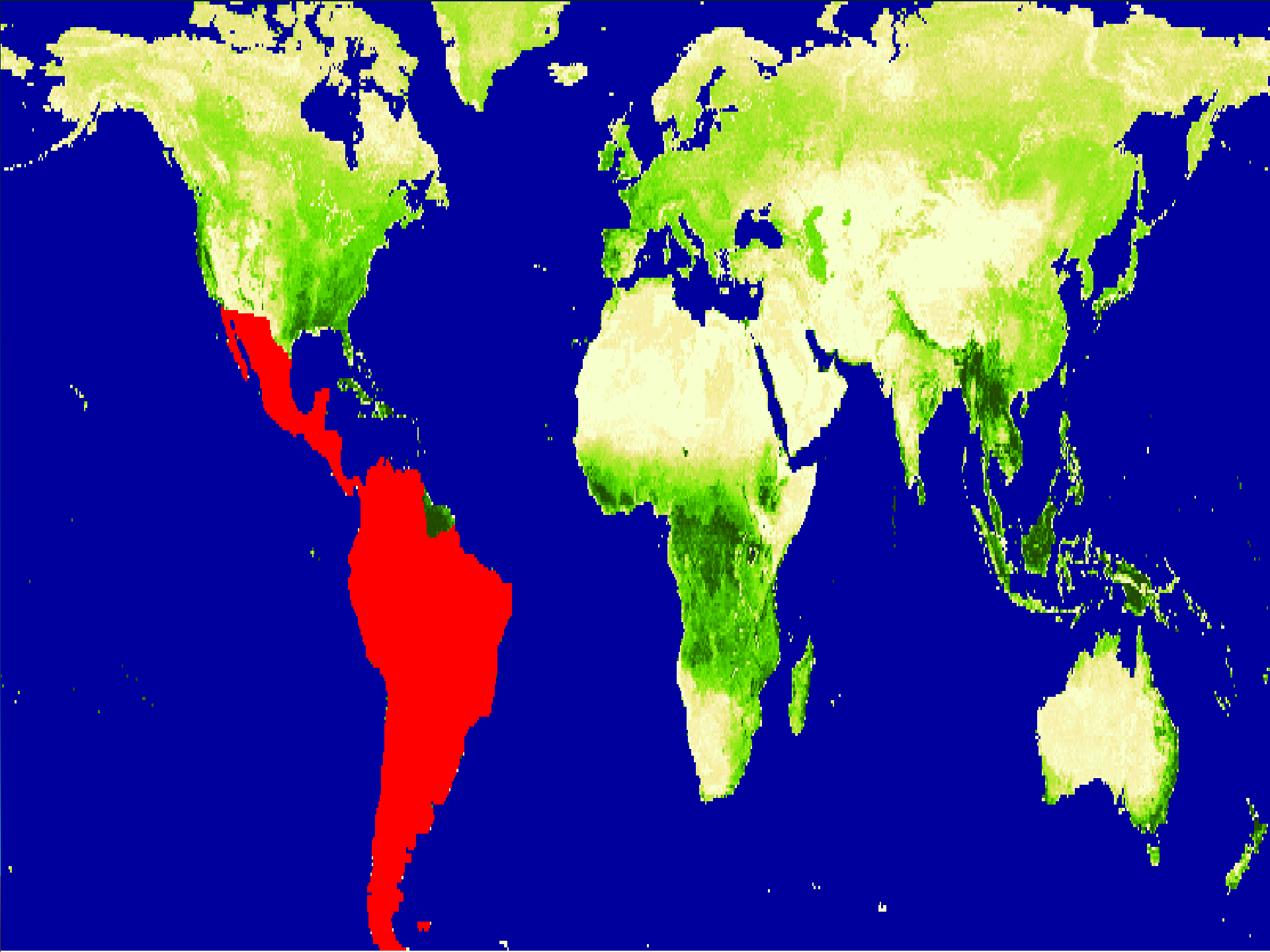

FISIOPATOLOGÍA:

- DISFUNCIÓN SISTÓLICA O FALLA EN LA CONTRACTILIDAD.
- FRACCIÓN DE EXPULSIÓN <50%

CARDIOMIOPATIA DILATADA:

CUADRO CLÍNICO:

INSUFICIENCIA CARDIACA CON CARDIOMEGALIA, TROMBOEMBOLISMO

EXAMEN FÍSICO:

- INSUFICIENCIA MITRAL Y/O TRICUSPÍDEA
- S3 (Galope ventricular)
- HIPERTENSIÓN VENOCAPILAR P.
- HIPERTENSIÓN VENOSA SISTÉMICA (Edema, Hepatomegalia, PVY)

ELECTROCARDIOGRAMA:

- ALTERACIONES REPOLARIZACIÓN Y CONDUCCIÓN
- FIBRILACION AURICULAR
- TAQUICARDIA VENTRICULAR

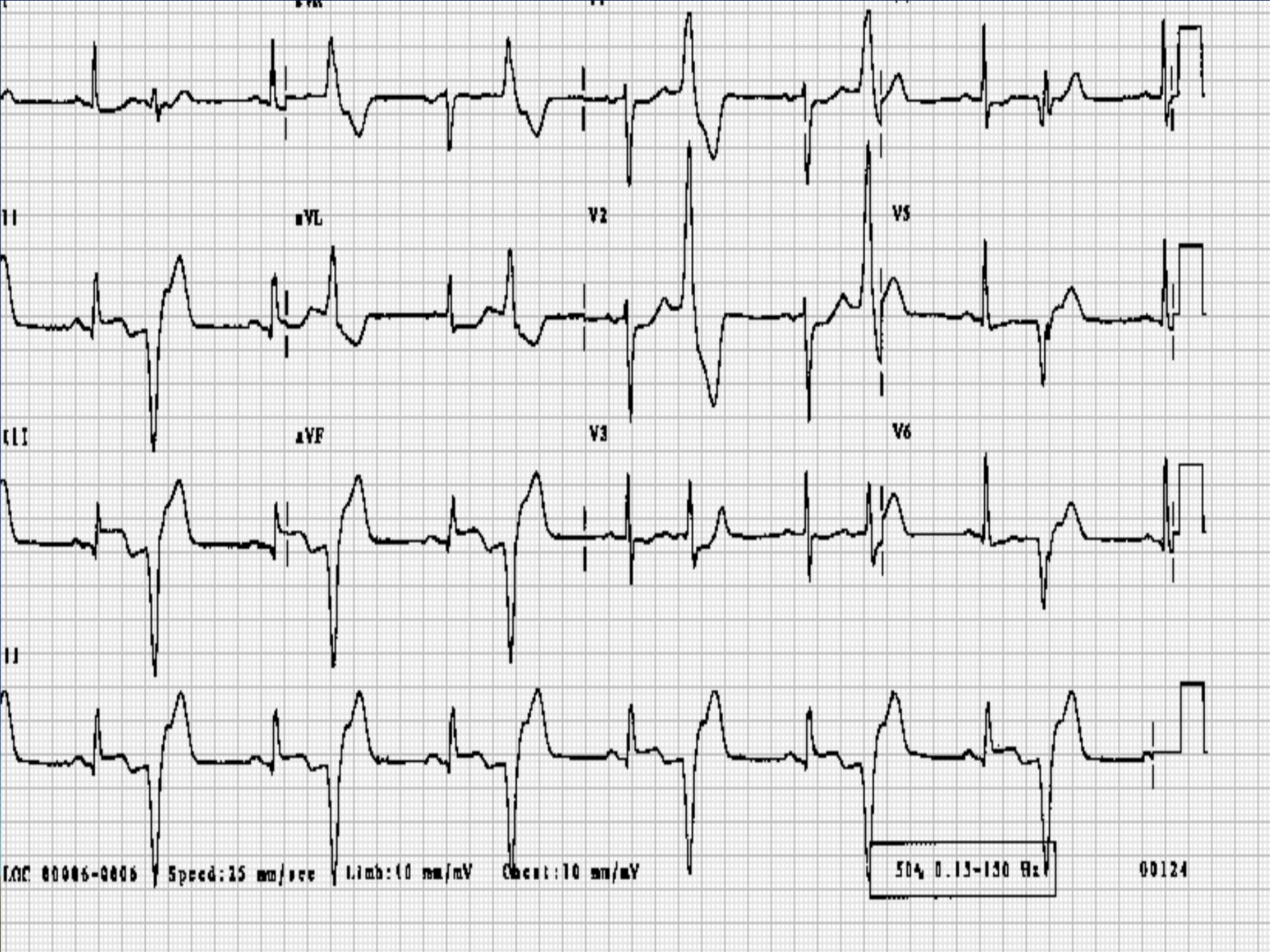
aVR
V1
V4
I
aVL
V2
V5
II
aVF
V3
V6
III
Speed:25 mm/sec
Limb:10 mm/mV
Chest:10 mm/mV
50Hz 0.15-150 Hz
00124

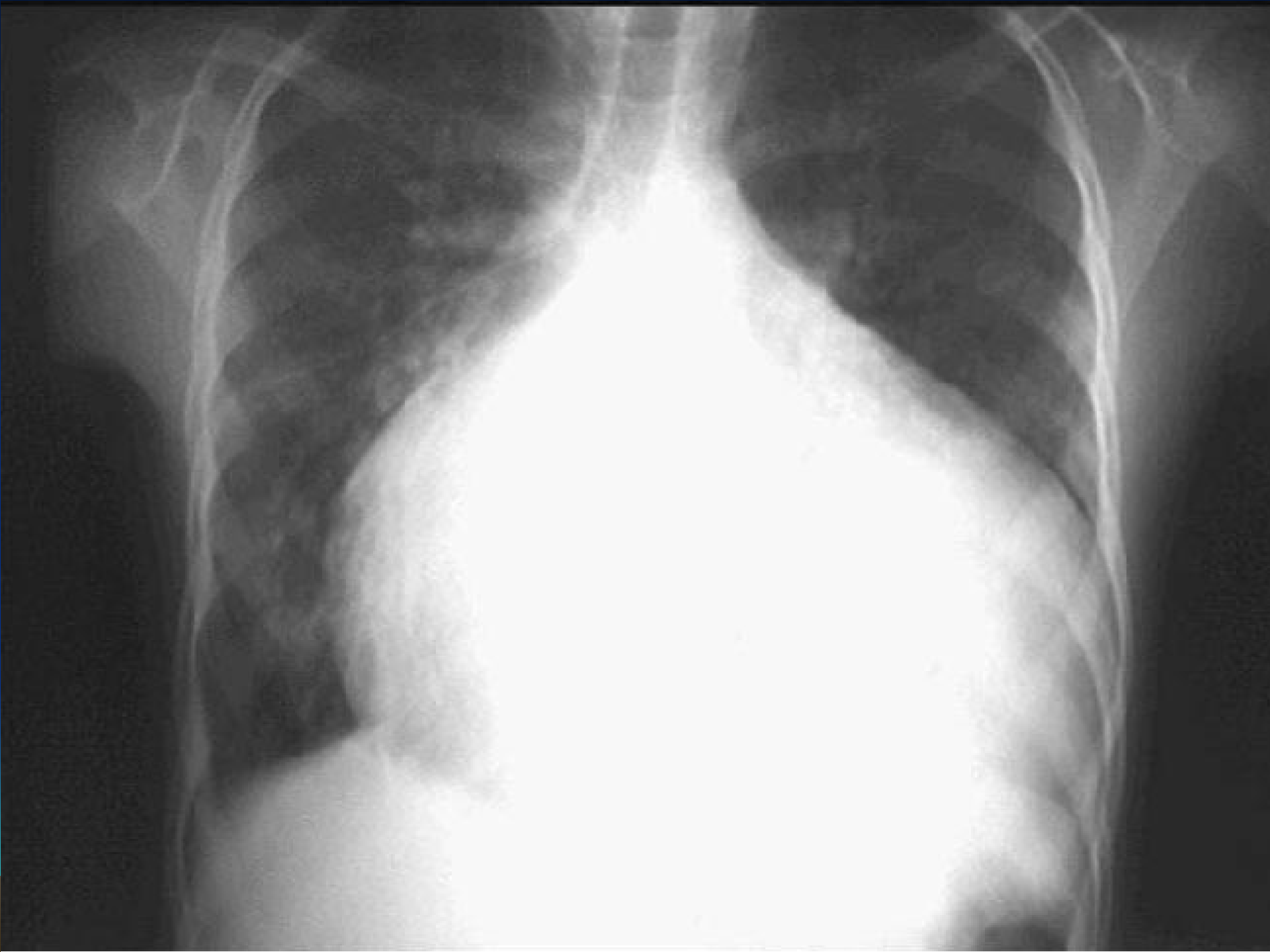

CARDIOMIOPATIA DILATADA:

ECOCARDIOGRAFIA:

- CRECIMIENTO BIVENTRICULAR
- HIPOKINESIA
- DERRAME PERICARDICO
- FRACCION EXPULSION <50%
- TROMBOS

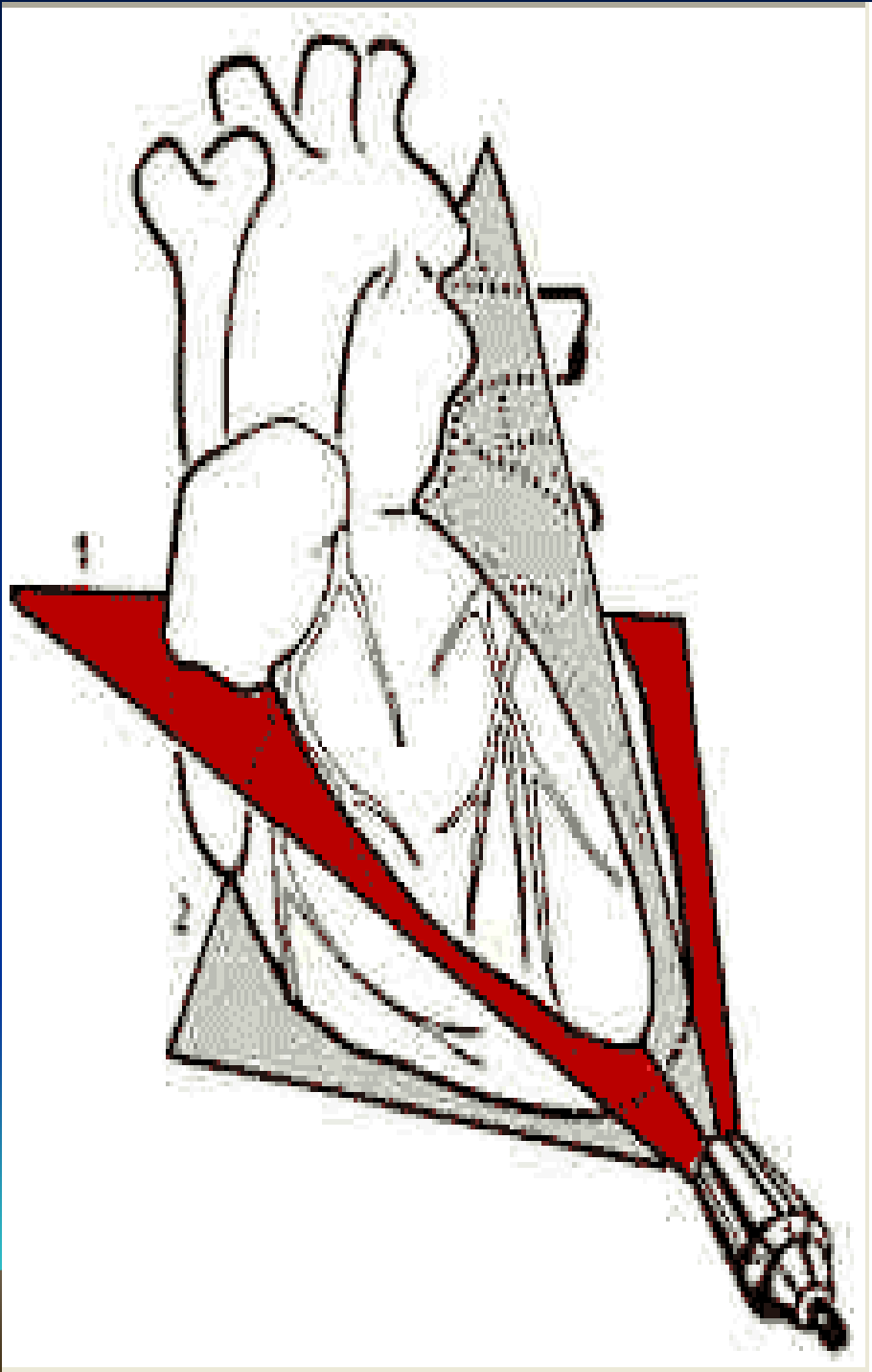
1
2

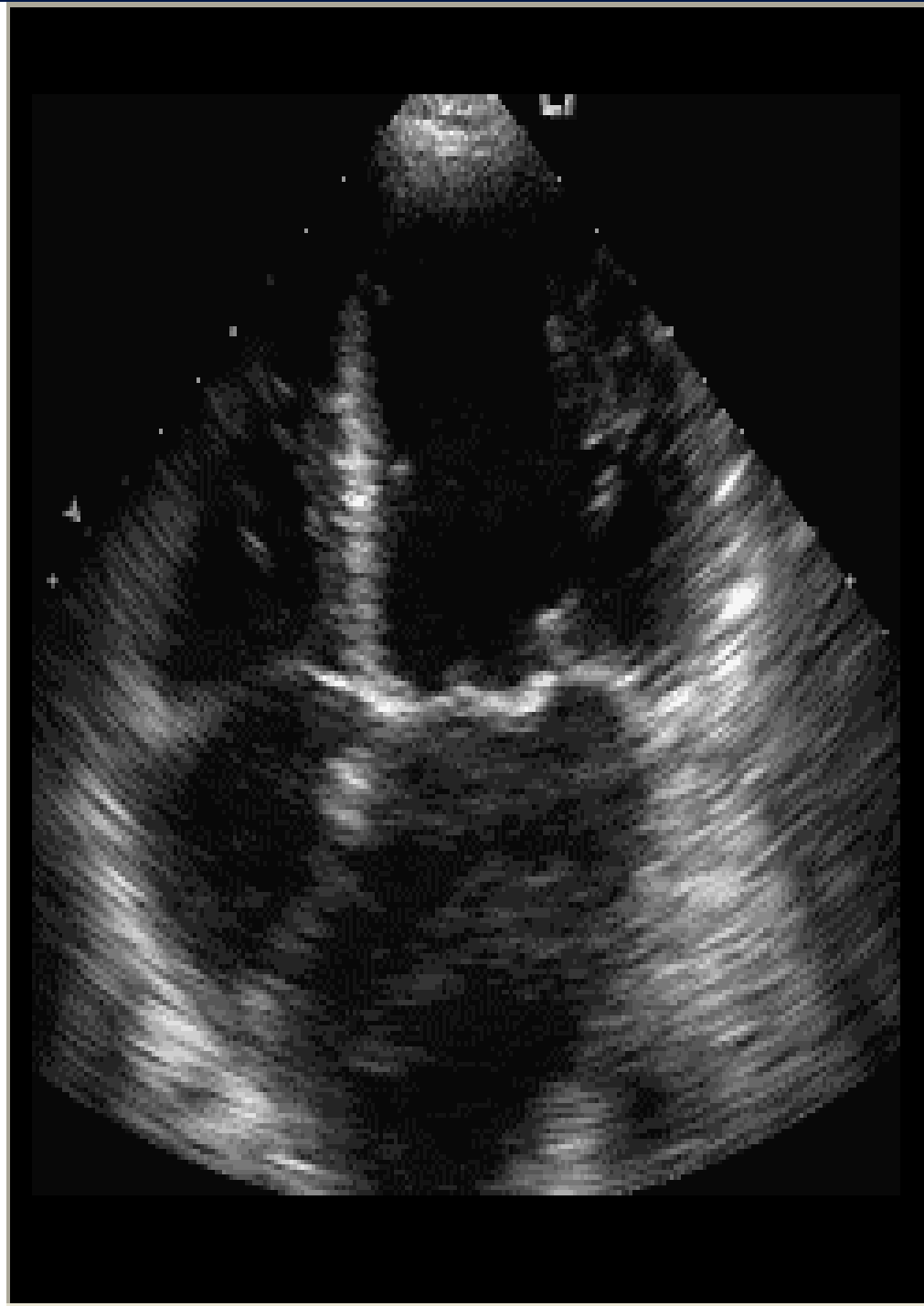

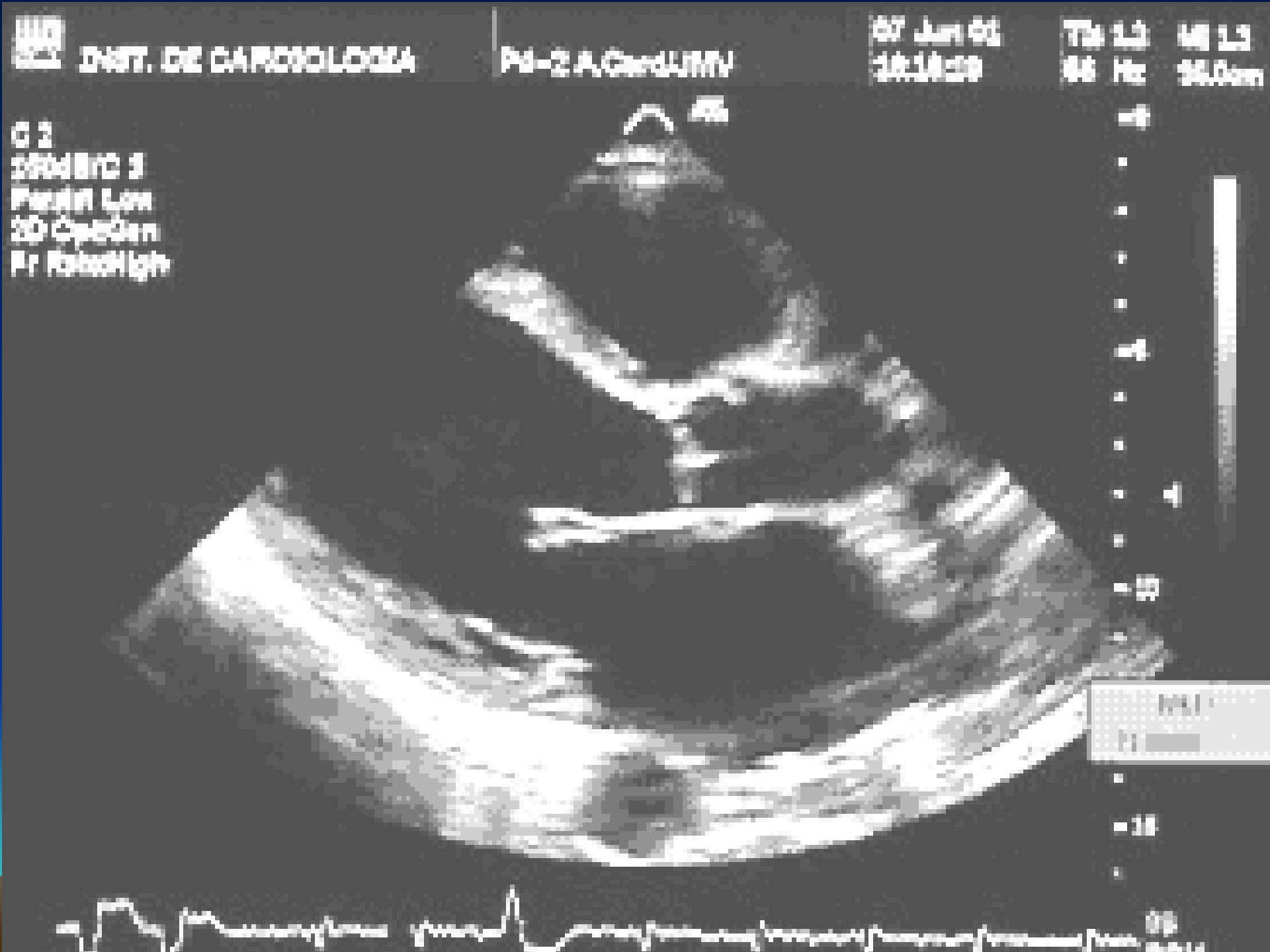
INST. DE CARDIOLOGIA
C 2
Persist Low
2D Opt/Gen
Fr Hi/Lo/High

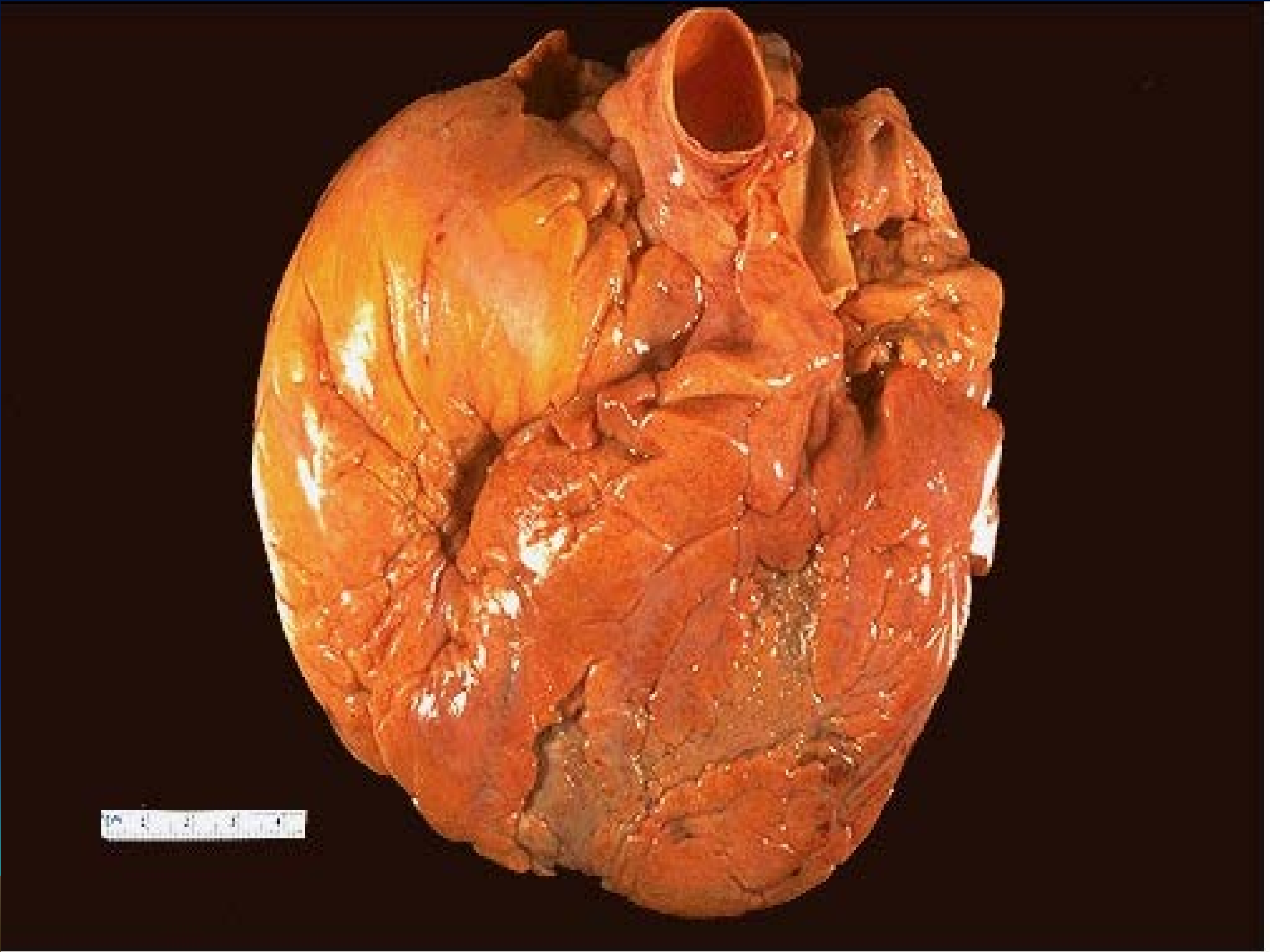

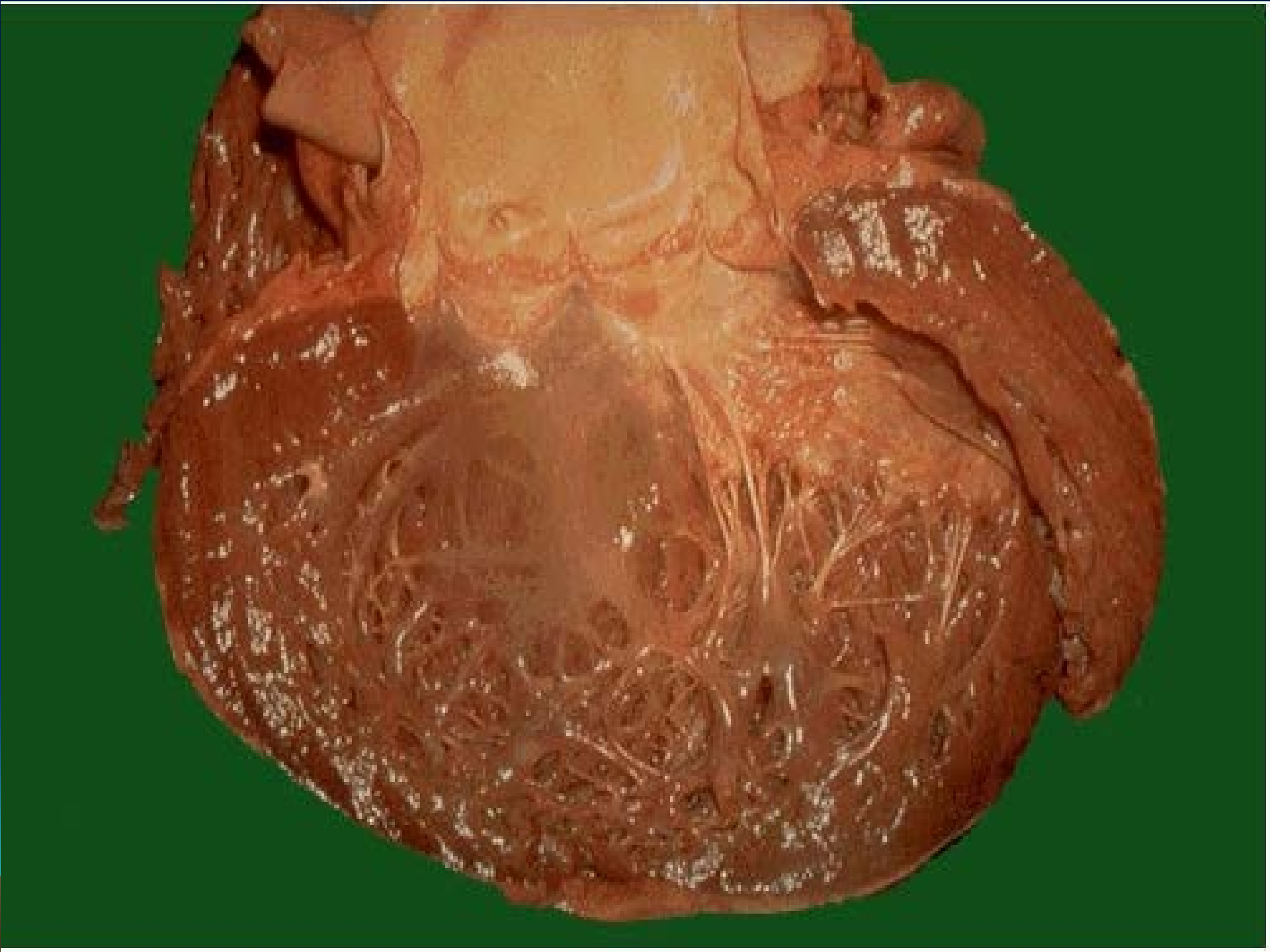

TRATAMIENTO CMD:

- REPOSO y DIETA HIPOSÓDICA
- DIURÉTICOS
- DIGITÁLICOS
- INHIBIDORES ECA y ARA
- ANTITROMBÓTICOS
- ANTIARRÍTMICOS
- TRANSPLANTE CARDIACO

CARDIOMIOPATIA HIPERTROFICA:

- SEPTAL
- APICAL (SINDROME YAMAGUCHI)
- BASAL
- POSTERIOR
- GLOBAL

CARDIOMIOPATIA HIPERTROFICA OBSTRUCTIVA (CMHO):

OTROS TERMINOS

- ESTENOSIS SUBAORTICA HIPERTROFICA FAMILIAR
- HIPERTROFIA SEPTAL ASIMETRICA

CARDIOMIOPATIA HIPERTRÓFICA:

HERENCIA:

- AUTOSOMICA DOMINANTE
- MUTACION EN LA CADENA PESADA DE LA BETA MIOSINA
- CROMOSOMA 14 (50%) 7, 11, 17, 21.

Normal heart

Hypertrophic cardiomyopathy

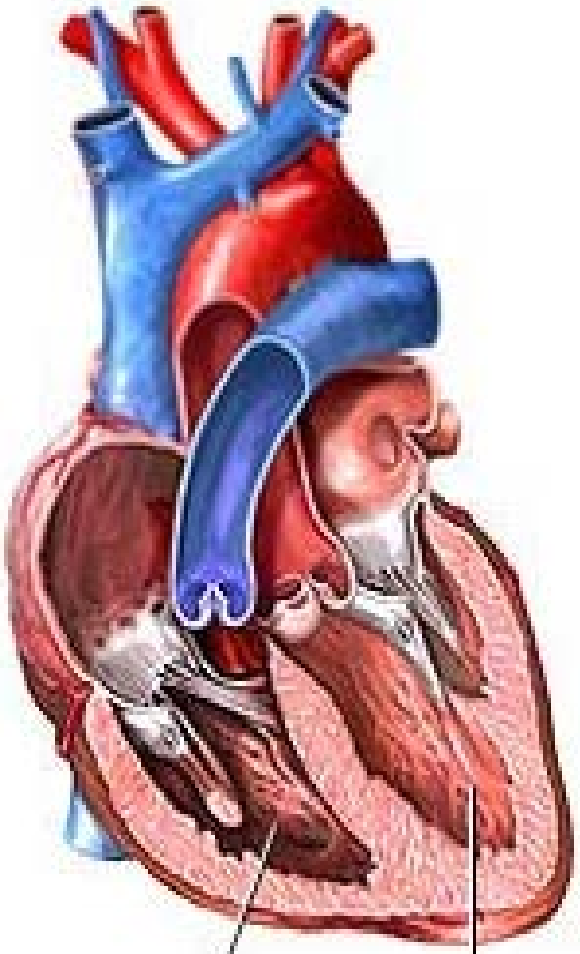

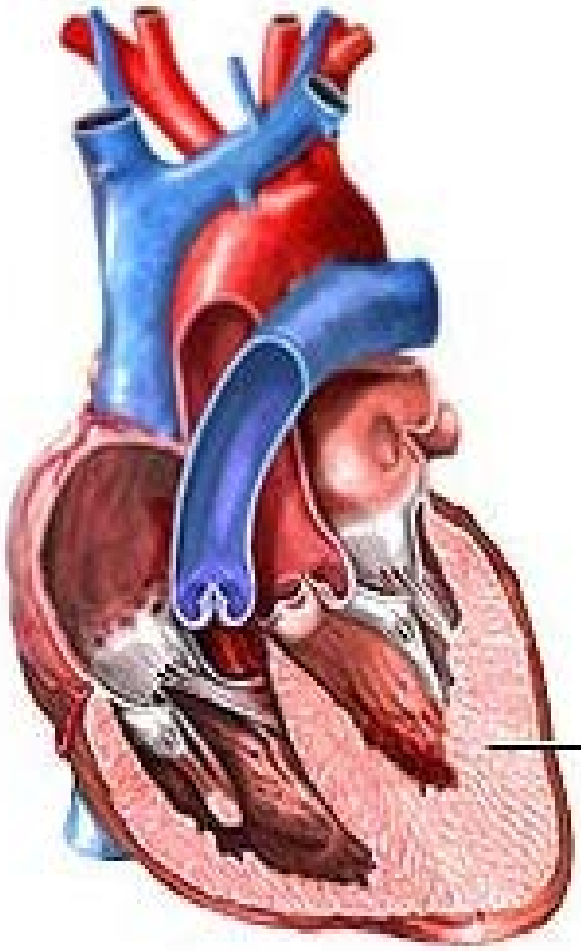

ADAM.

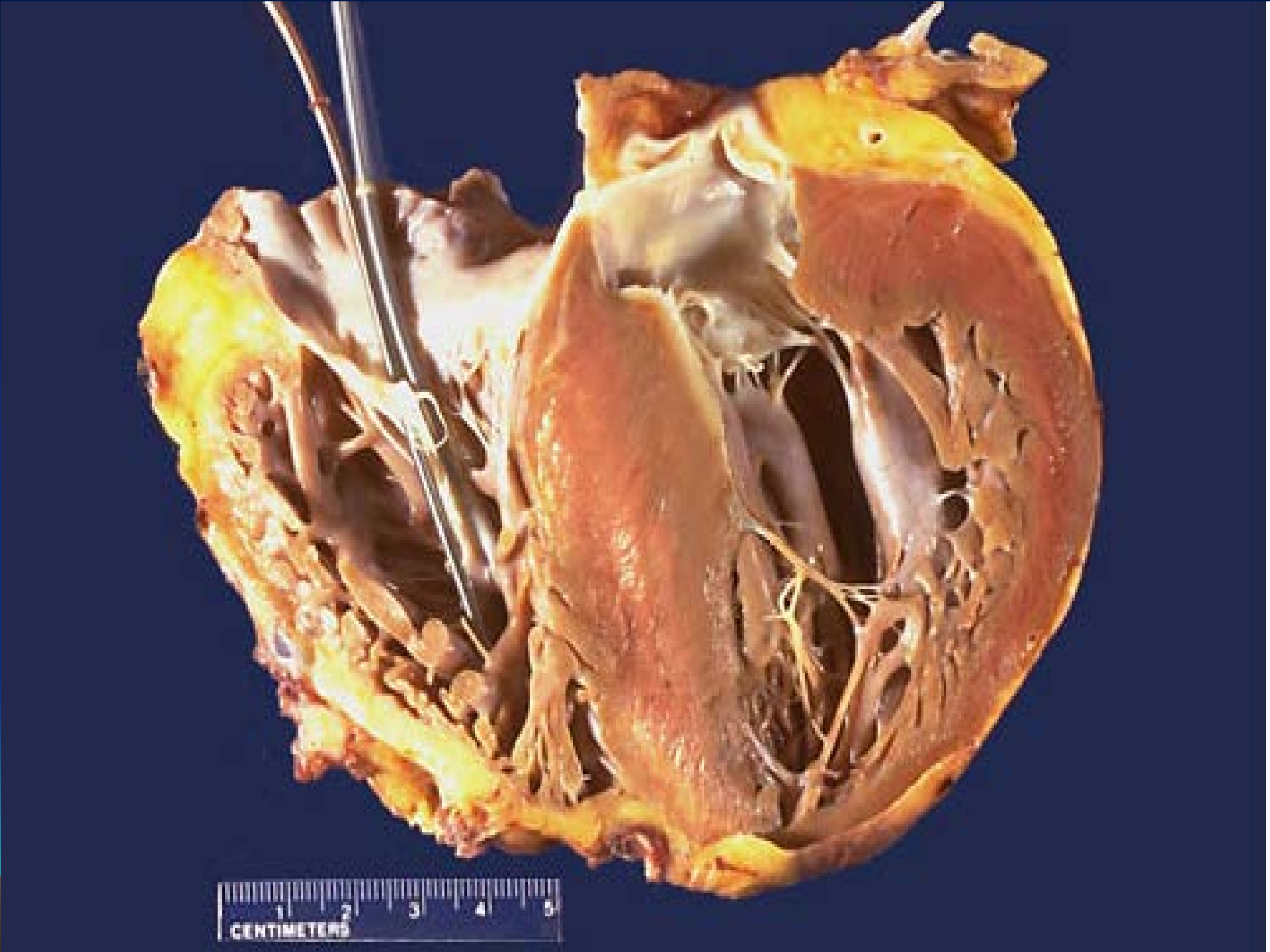
1
2
3
4
5
CENTIMETERS

METRIC 1
2

CARDIOMIOPATIA HIPERTROFICA:

- PATOGENESIS DESCONOCIDA
- ESTIMULACION EXCESIVA DE CATECOLAMINAS
- ANORMALIDADES GENETICAS DEL TEJIDO DE LA CRESTA NEURAL
- SE ASOCIA CON: *HIPERTENSION, LENTIGINOSIS, FEOCROMOCITOMA, ATAXIA DE FRIEDRICH.*

CARDIOMIOPATIA HIPERTROFICA:

FISIOPATOLOGIA:

- HIPERTROFIA SEPTAL
- FIBRAS MUSCULARES CORTAS-GRUESAS EN FORMA DE REMOLINOS
- FIBROSIS
- NUCLEOS GRANDES

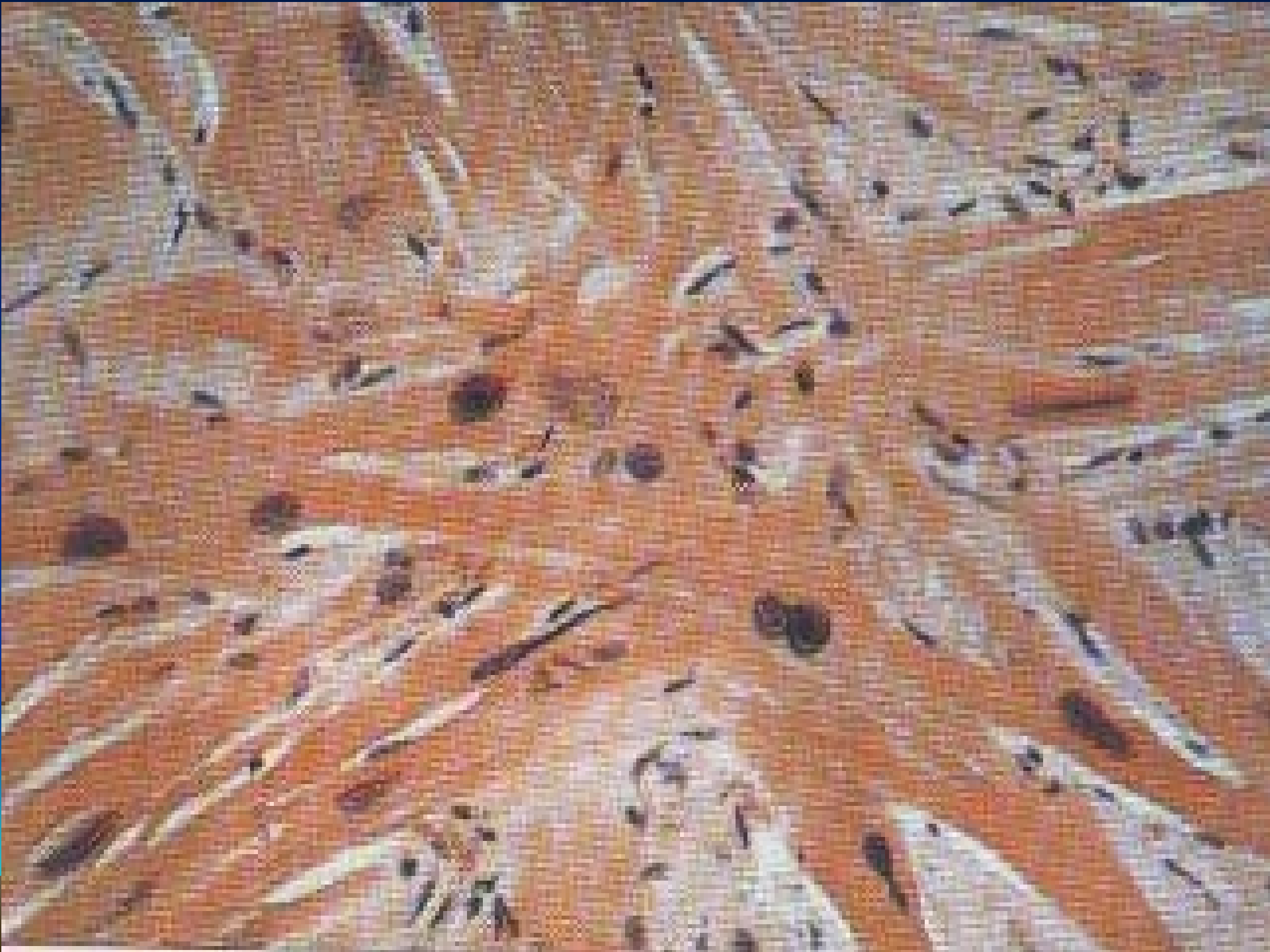

FISIOPATOLOGÍA:

- OBSTRUCCIÓN DEL TRACTO DE SALIDA DEL VENTRÍCULO IZQUIERDO.
- DISFUNCIÓN DIASTÓLICA (TRASTORNO EN LA RELAJACIÓN).

CUADRO CLÍNICO:

- ANGOR DE ESFUERZO
- DISNEA DE ESFUERZO
- SÍNCOPE DE ESFUERZO
- MUERTE SÚBITA (ARRITMIAS VENTRICULARES)

SINCOPE Y MUERTE SUBITA EN CMHO:

- OBSTRUCCION SEVERA
- ESTIMULACION CATECOLAMINAS
- SINDROME DE WOLF PARKINSON WHITE
- IAM MASIVO

EXAMEN FÍSICO EN CMHO:

- PULSOS BIESFERIENS
- APEX HIPERDINAMICO
- SOPLO SISTOLICO EYECTIVO APICAL Y EN MESOCARDIO
- INSUFICIENCIA MITRAL

DIAGNÓSTICO CMHO:

- ECG: HVI, Q PROFUNDAS EN V5-V6
- RX: ICT NORMAL Ó > 0.5
- ECO: HVI, SEPTUM 1.5>PARED POSTERIOR, GRADIENTE ENTRE TSVI Y AORTA, CIERRE MESOSISTÓLICO AÓRTICO, INSUFICIENCIA MITRAL, MOVIMIENTO SISTÓLICO ANTERIOR

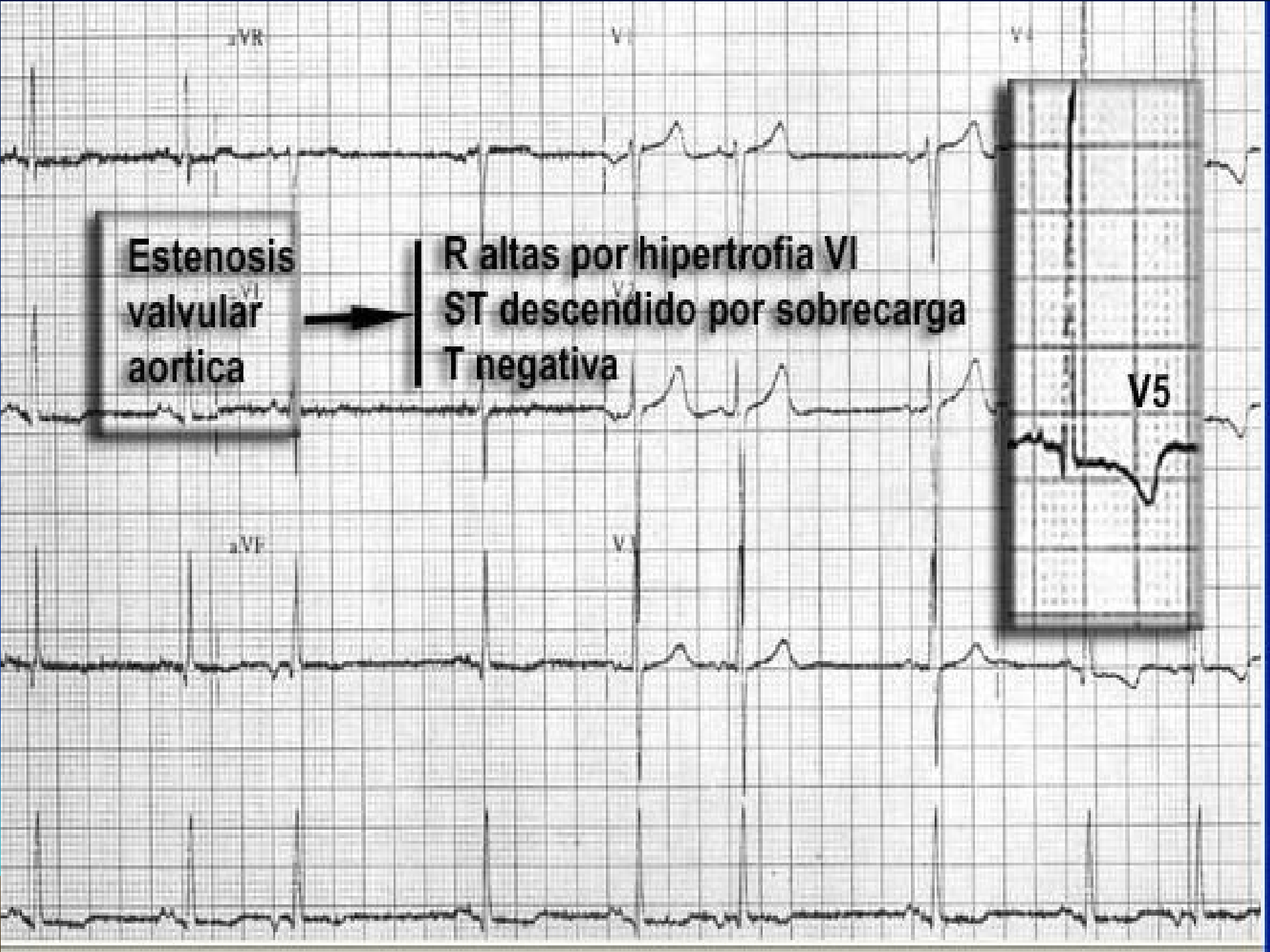
Estenosis valvular aortica
R altas por hipertrofia VI
ST descendido por sobrecarga
T negativa
V5

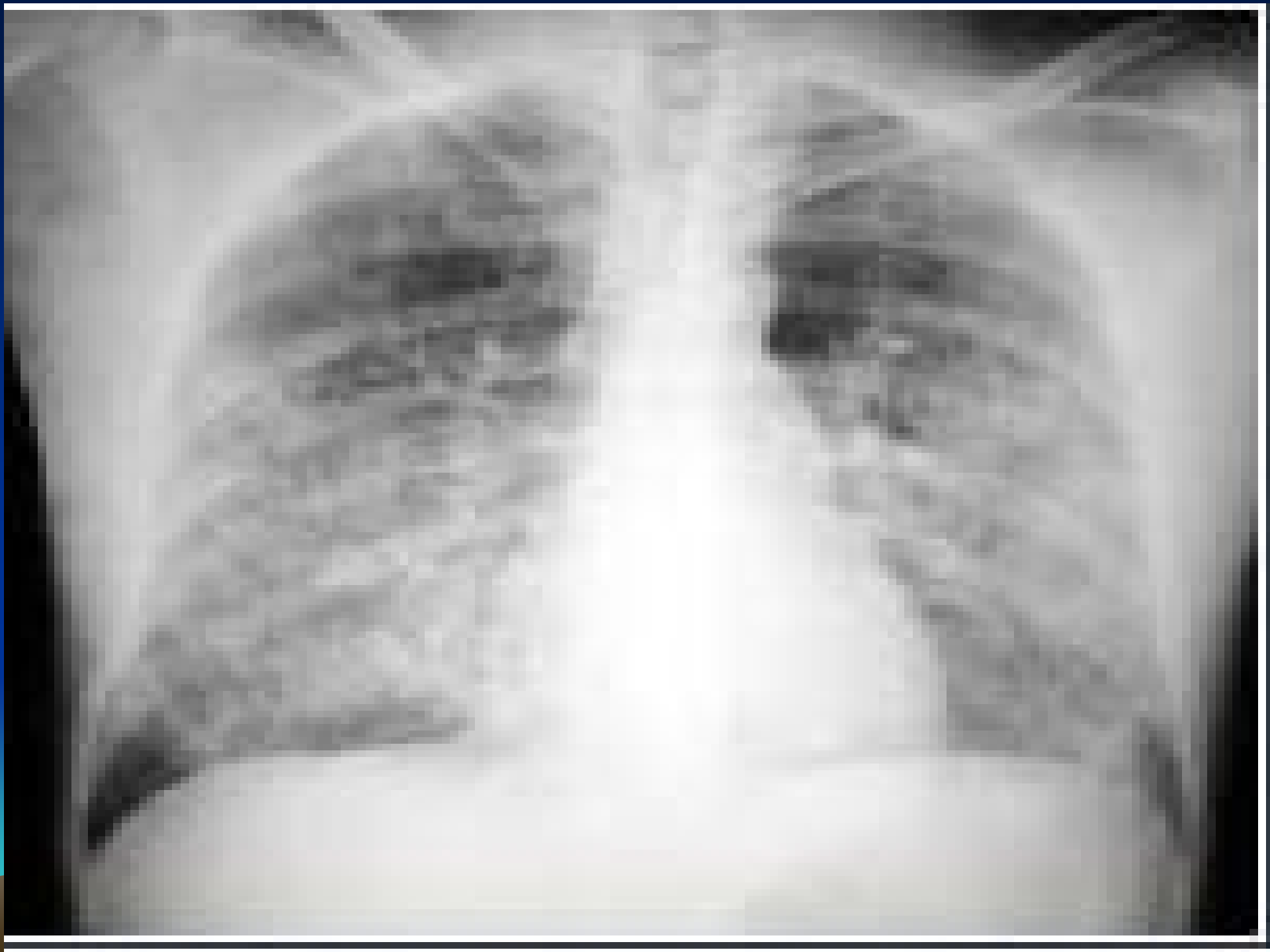

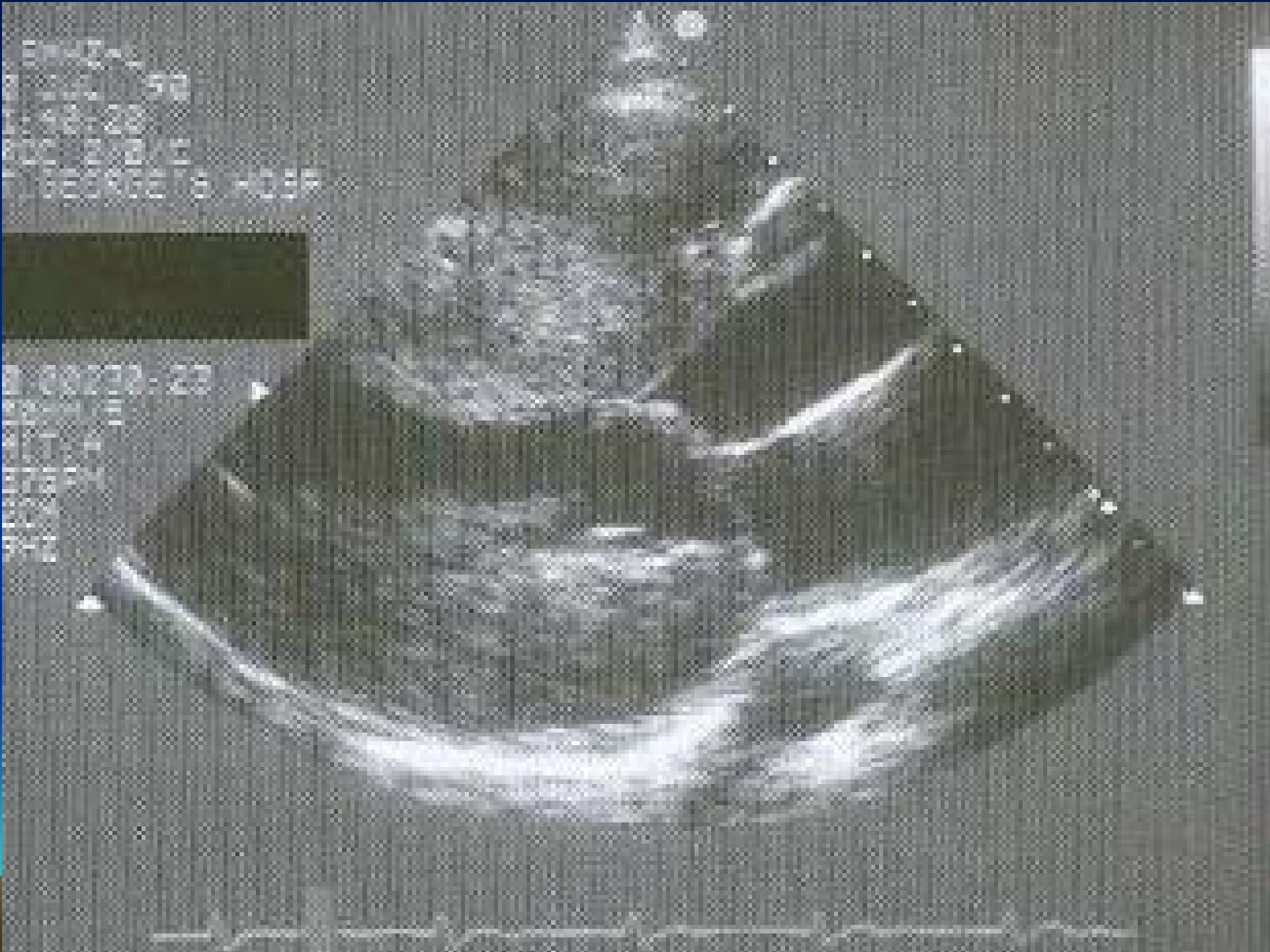

2 AUG 90
1:15:26
ST. GEORGE'S HOSP
LV
AO
LA
72.

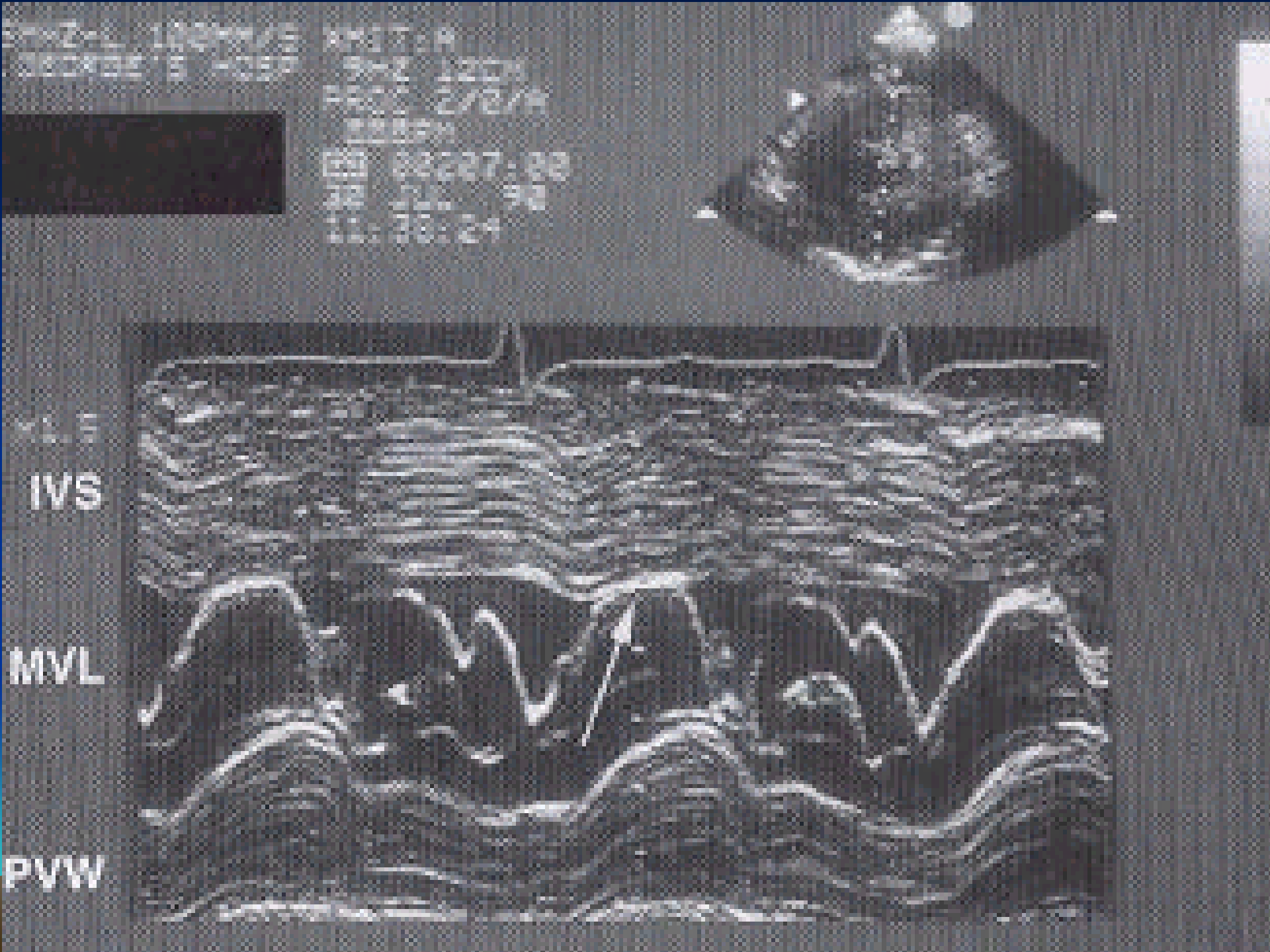
IVS
MVL
PVW

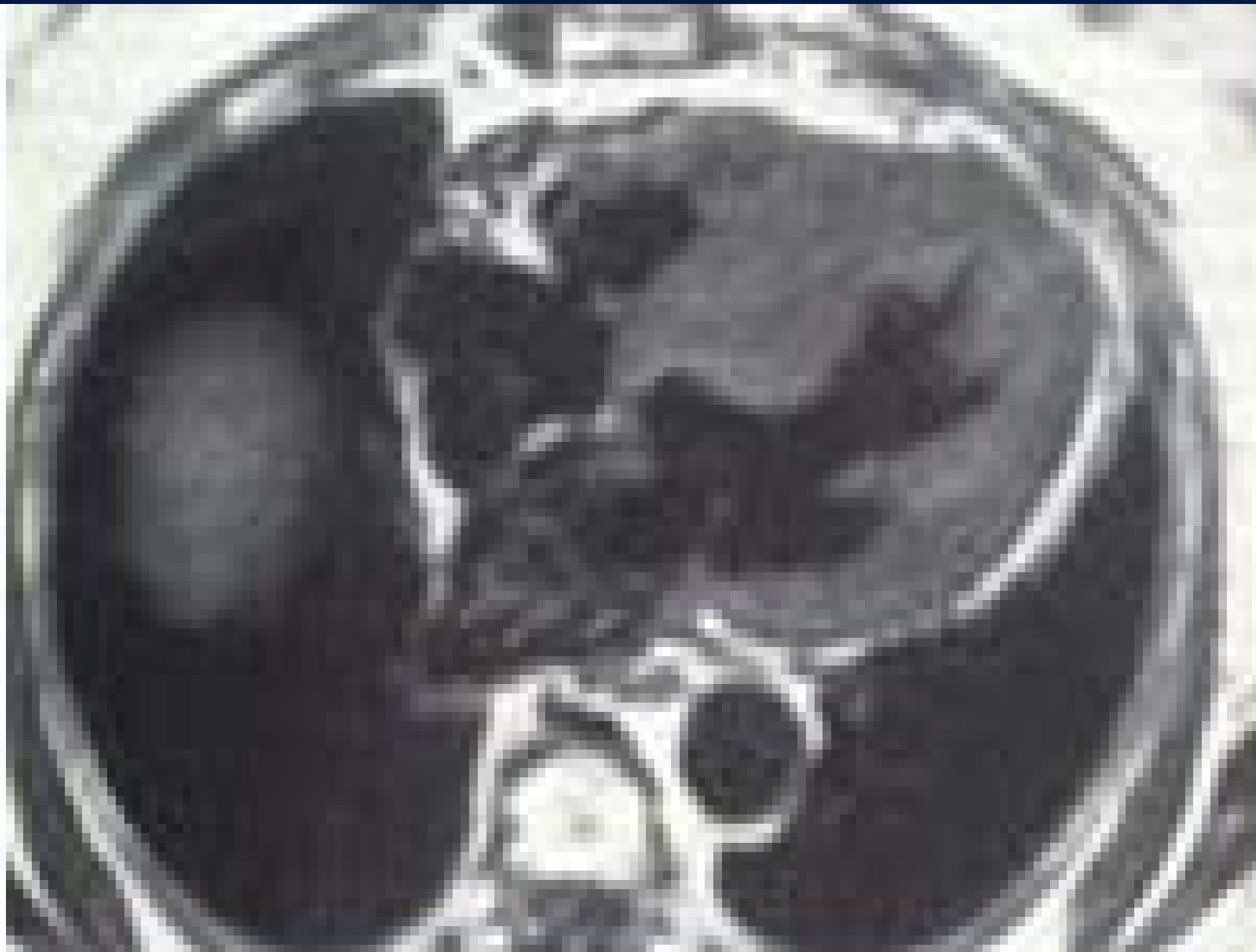

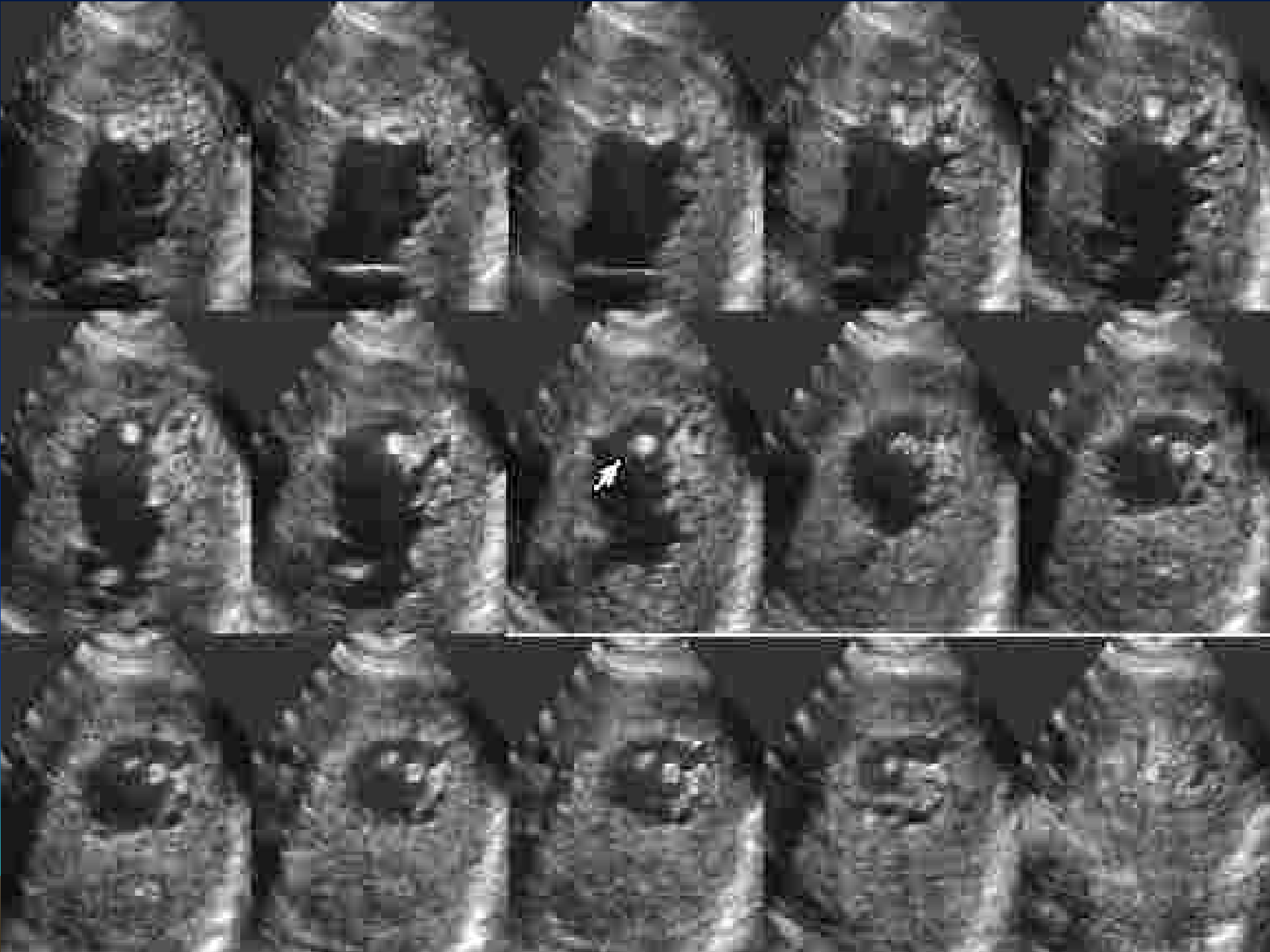

TRATAMIENTO CMHO:

- BETABLOQUEADORES
- ANTIARRÍTMICOS
- MIECTOMÍA
- NECROSIS QUÍMICA
- MARCAPASO DESFIBRILADOR

CARDIOMIOPATIA RESTRICTIVA:

- FORMA MENOS COMUN
- SEMEJA PERICARDITIS CONSTRICTIVA
- HEMOCROMATOSIS Y AMILOIDOSIS
- ESCLERODERMIA
- ENFERMEDAD DE LOEFFLER
- FIBROSIS ENDOMIOCARDICA
- SARCOIDOSIS

CARDIOMIOPATÍA RESTRICTIVA:

- MIOCARDIO INFILTRADO QUE IMPIDE LA RELAJACIÓN (DISFUNCIÓN DIASTÓLICA)
- INSUFICIENCIA CARDIACA
- INSUFICIENCIA DE VÁLVULAS AV
- DILATACIÓN AURICULAR

PM SJ164/79

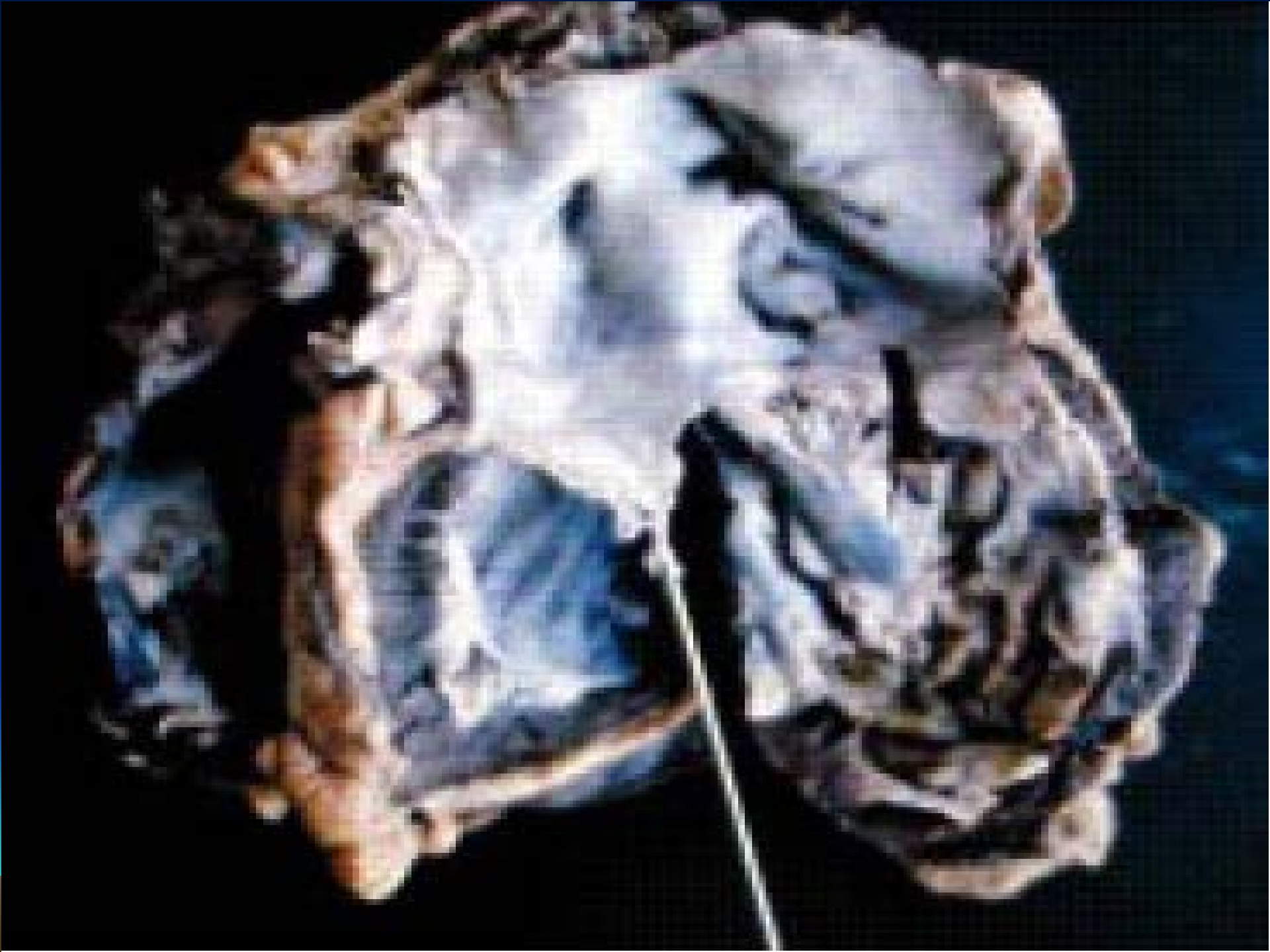

A.D.A.M.

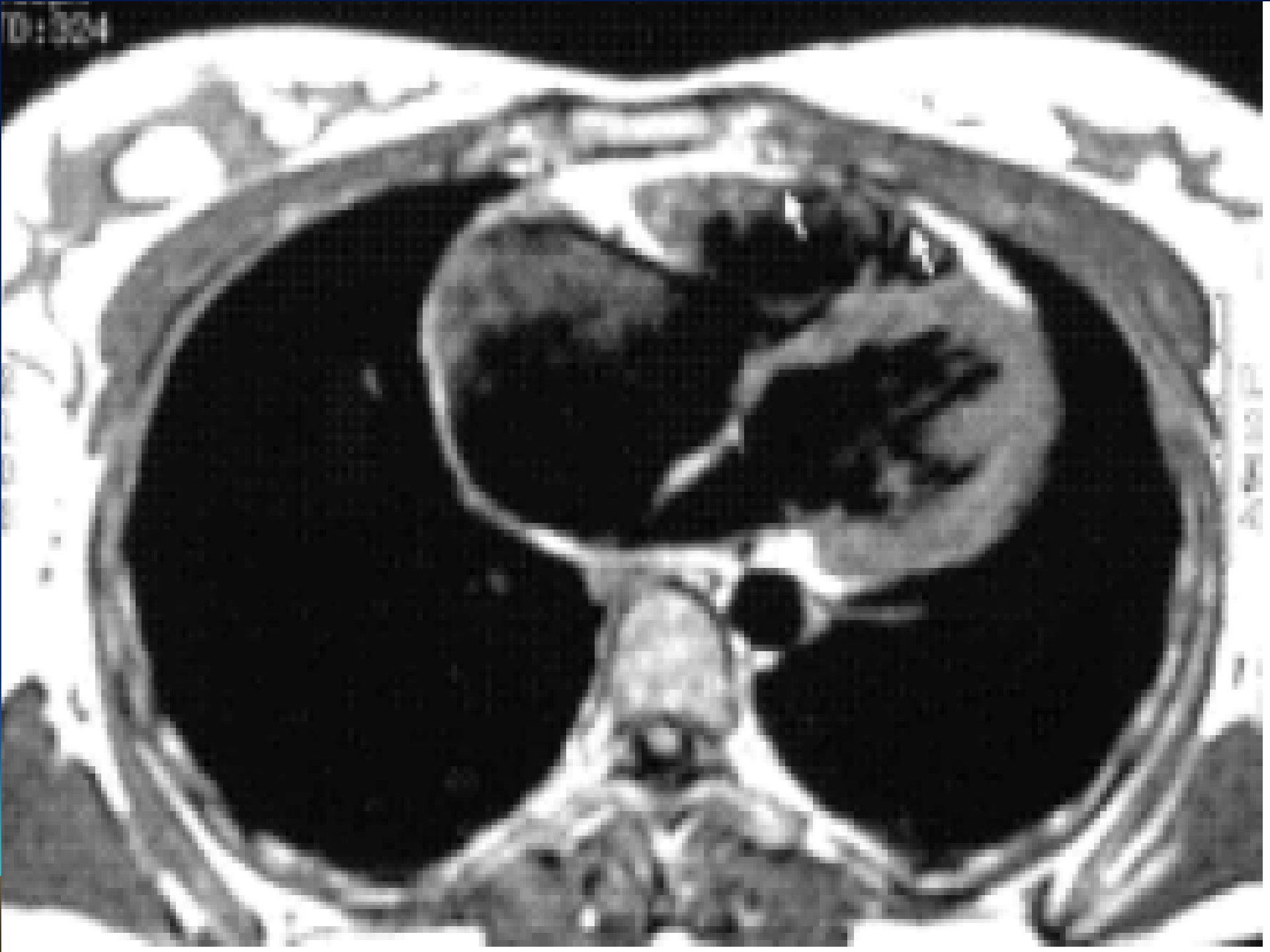
ID: 3024

CARDIOMIOPATIA RESTRICTIVA:

TRATAMIENTO:

- REPOSO
- DIGITALICOS
- DIURETICOS
- VASODILATADORES

CASO CLÍNICO:

- Masculino 39 años presenta síncope y angor de esfuerzo, historia familiar de muerte súbita. Soplo sistólico expulsivo en mesocardio y regurgitante apical.
- **ECG:** ondas Q profundas en derivaciones izquierdas, R altas en V1-V2.
- **DIAGNÓSTICO**_____

CONCLUSIONES:

- LAS CMs SON UN DIAGNÓSTICO DE EXCLUSIÓN EN CARDIOLOGÍA.
- CMD = INSUFICIENCIA CARDIACA, CARDIOMEGALIA, INSUFICIENCIA M/T
- CMH = ANGOR, SÍNCOPE Y DISNEA DE ESFUERZO, MUERTE SÚBITA
- PRONÓSTICO RESERVADO.

BIBLIOGRAFIA:

- SWANTON, Cardiology pocket book. Editorial Blackwell Scientific Publications
- FARRERAS-ROZMAN, Medicina Interna. Editorial Mosby-Doyma libros.

CARDIOPATIAS CONGENITAS ACIANOGENAS

DR. RAMIRO LARA R.

- COMUNICACION INTERAURICULAR
- COMUNICACION INTERVENTRICULAR
- PERSISTENCIA CONDUCTO ARTERIOSO

CLASIFICACION FISIOPATOLOGICA DE CARDIOPATIAS CONGENITAS

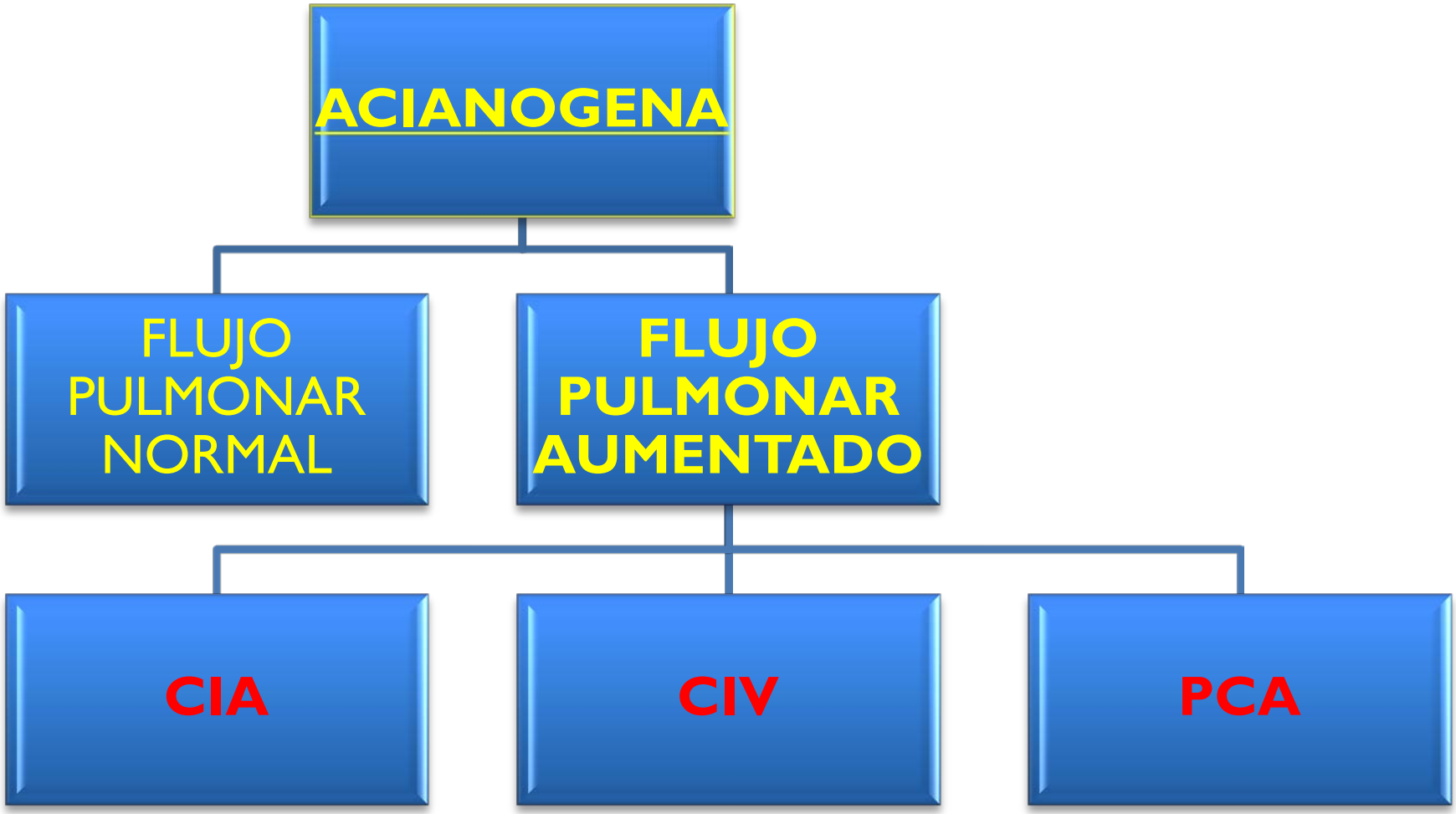

COMUNICACION INTERAURICULAR

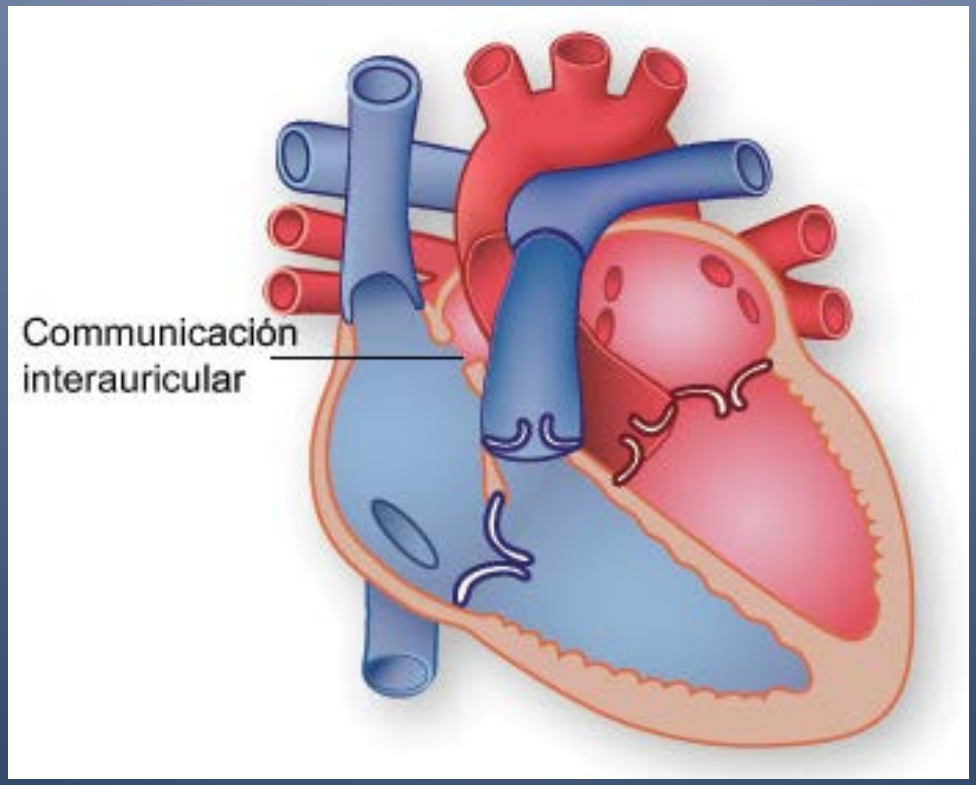

DEFINICION

- DEFECTO EN TABIQUE INTERAURICULAR

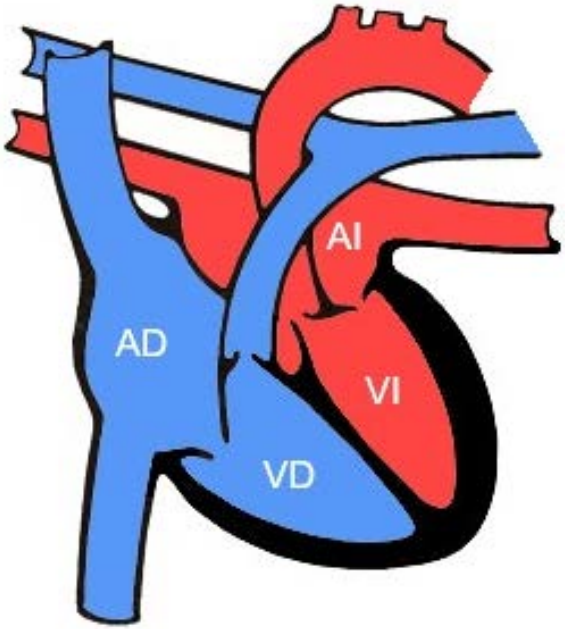

Corazón normal

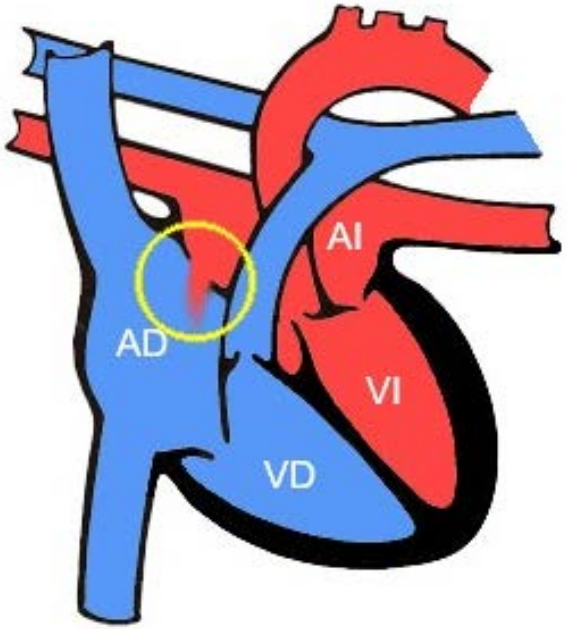

CIA

Defecto del tabique auricular

TIPOS (LOCALIZACION)

- OSTIUM PRIMUM
  - PORCION MAS BAJA
- OSTIUM SECUNDUM
  - MAS FRECUENTE
  - MEDIOSEPTAL
- SENO VENOSO
  - DESEMBOCADURA VCS-VCI

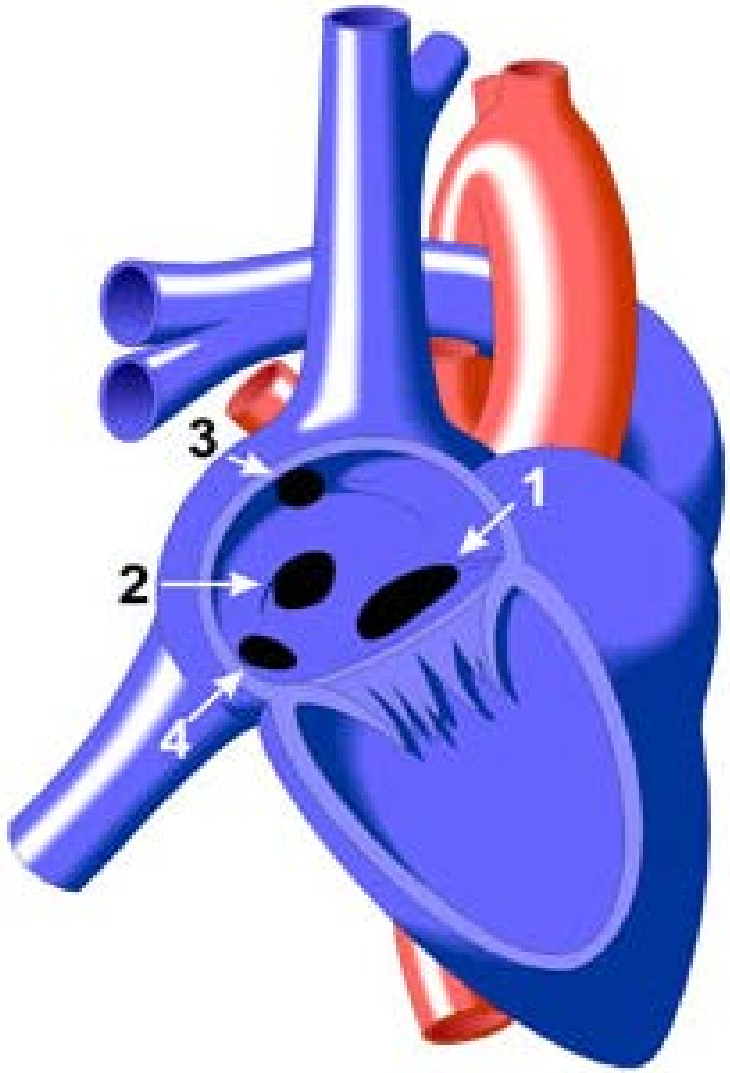

TIPOS (LOCALIZACION)

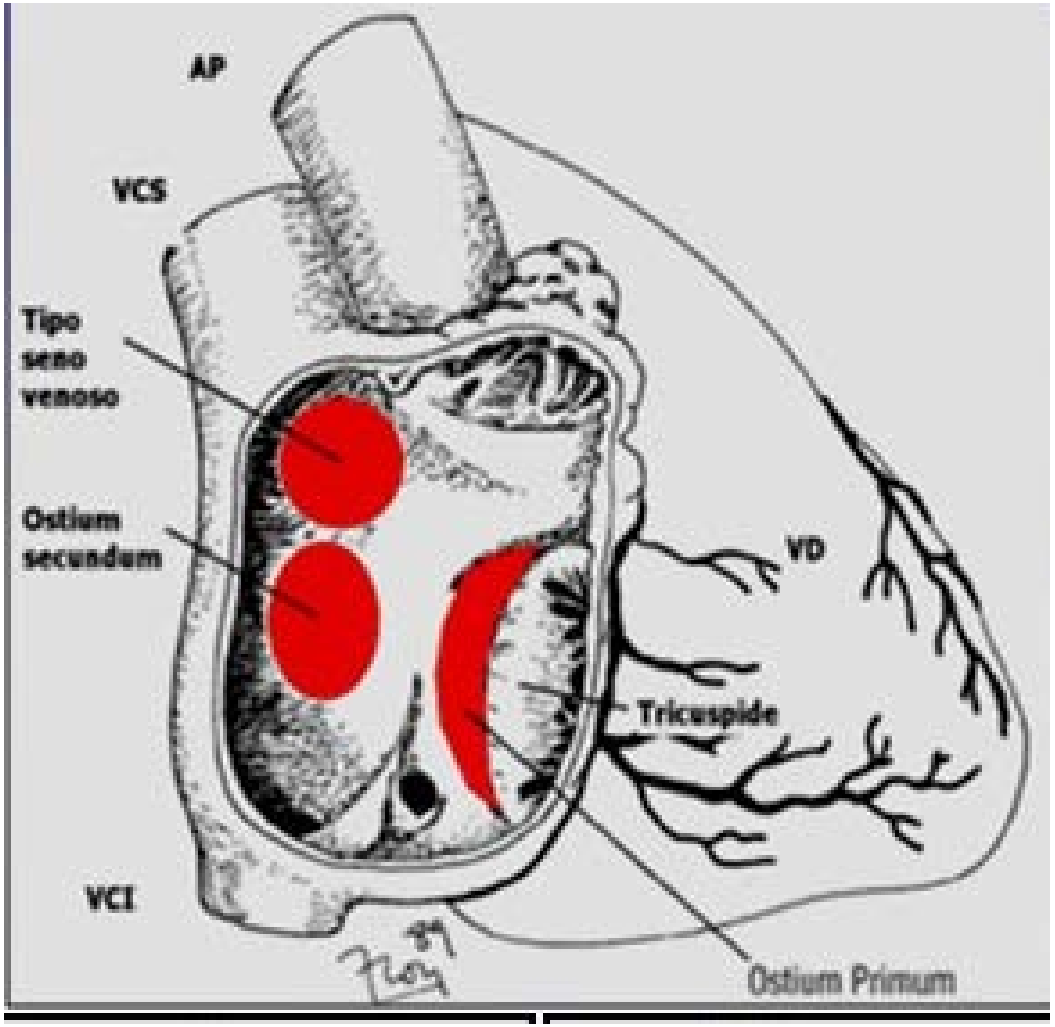

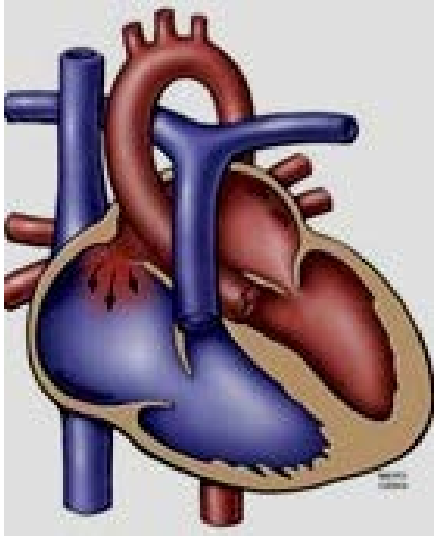

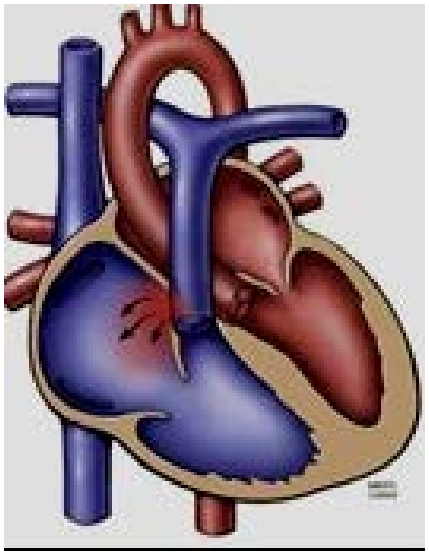

FISIOPATOLOGIA

- SHUNT IZQ→DER
- SOBRECARGA CAVIDADES DER
- SOBRECARGA CIRCUITO PULMONAR

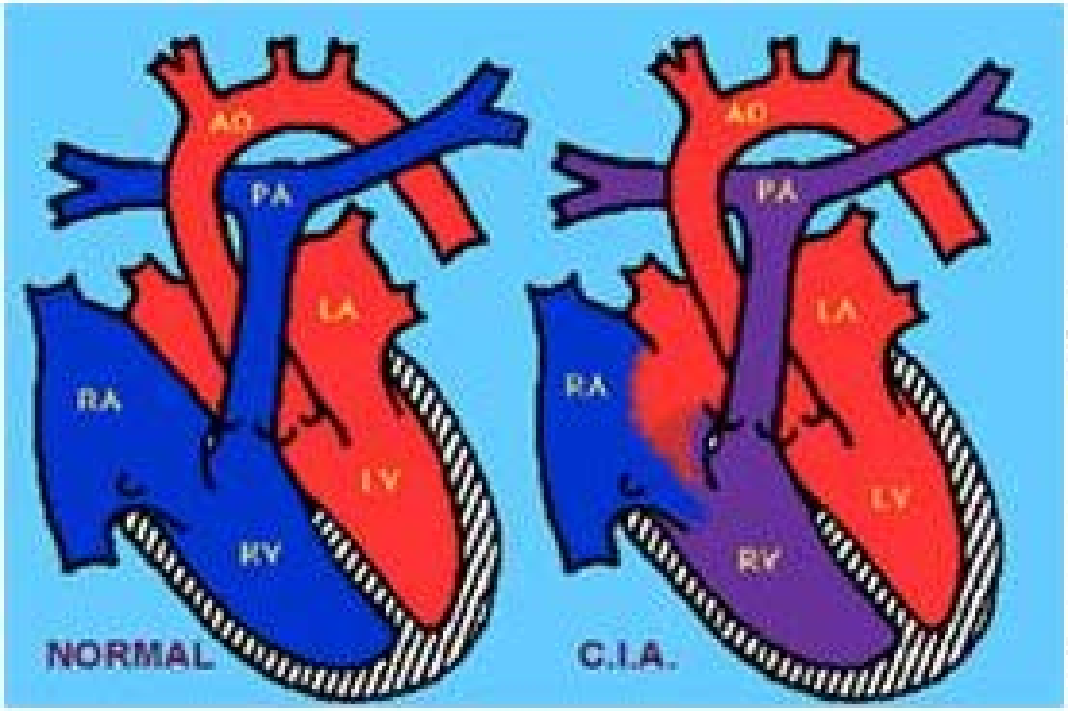

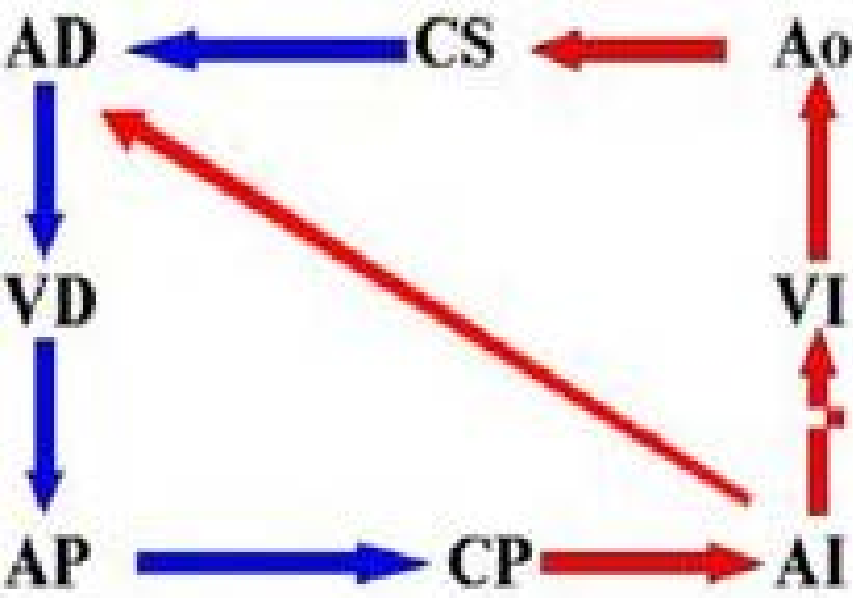

FISIOPATOLOGIA

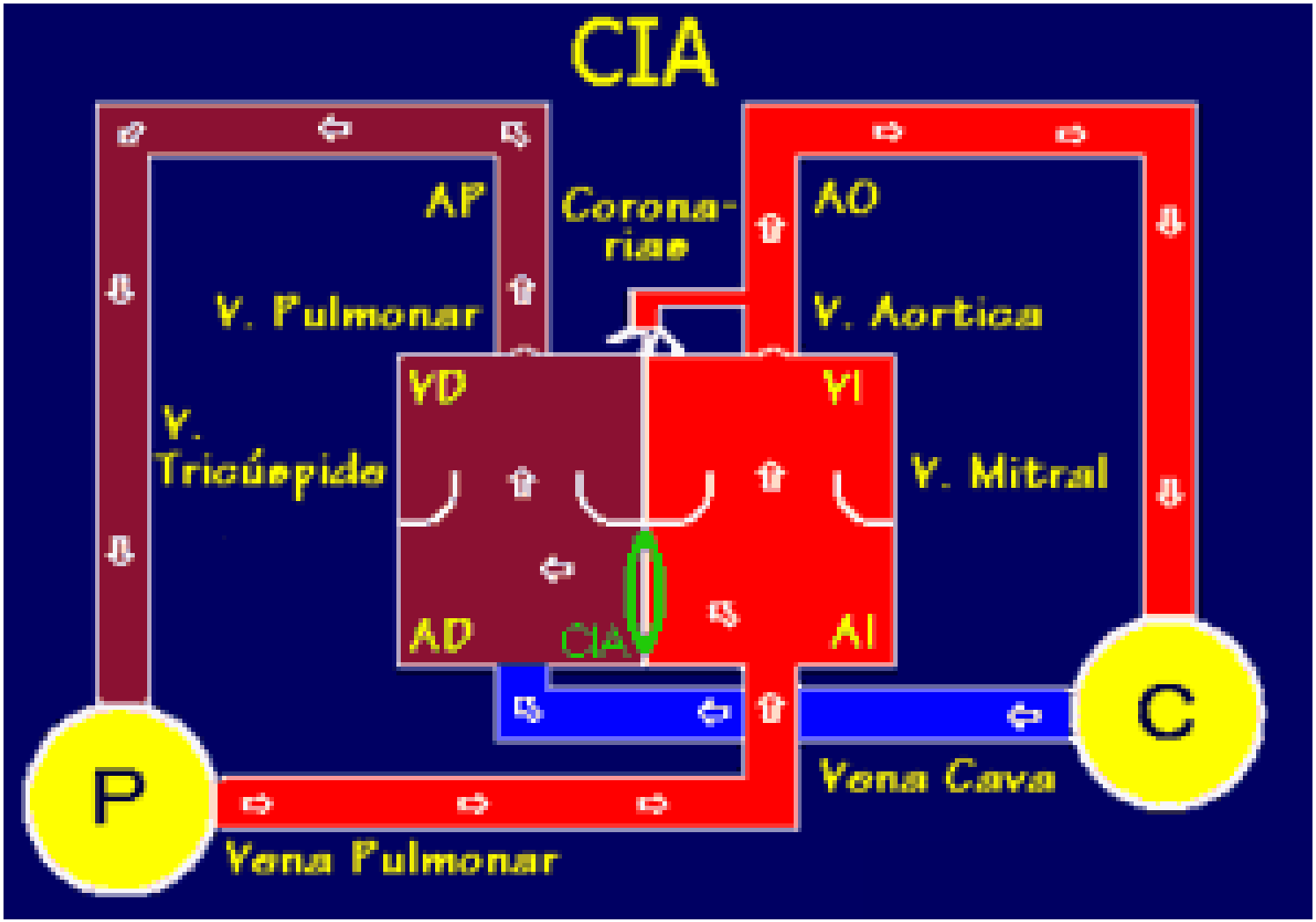

CLINICA

- ASINTOMATICO
- IC
- DISNEA
- ⇧INFECCIONES RESPIRATORIAS BAJAS
- 30-40 AñOS
  - HAP
  - IC
  - SIND EISENMENGER

Defecto del tabique auricular

CLINICA

- R1 FUERTE+SOPLO SISTOLICO
- R2 DESDOBLAMIENTO FIJO
- DESAPARECE DESDOBLAMIENTO R2 EN HTP

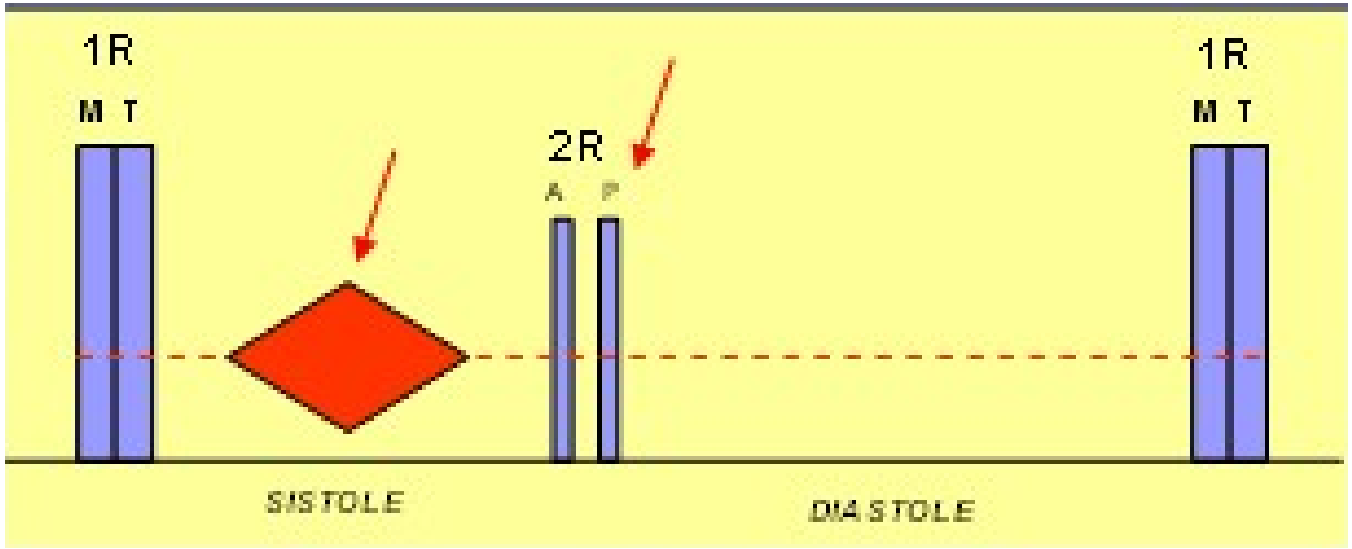

DIAGNOSTICO

- ECOCARDIOGRAMA
  - DE ELECCION PARA Dx

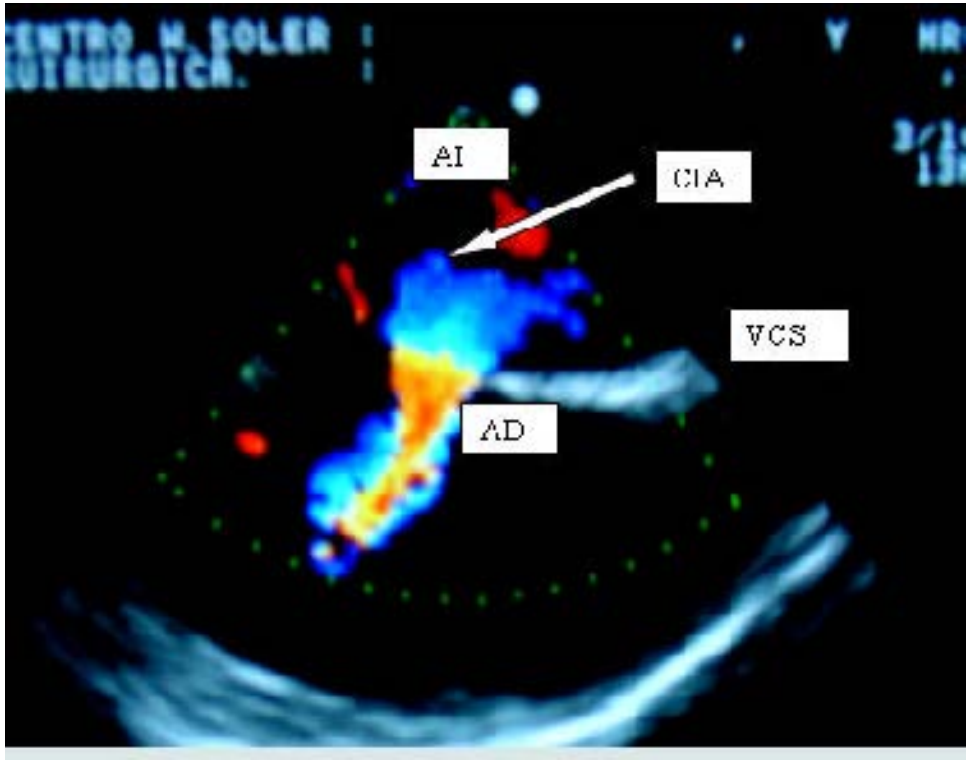

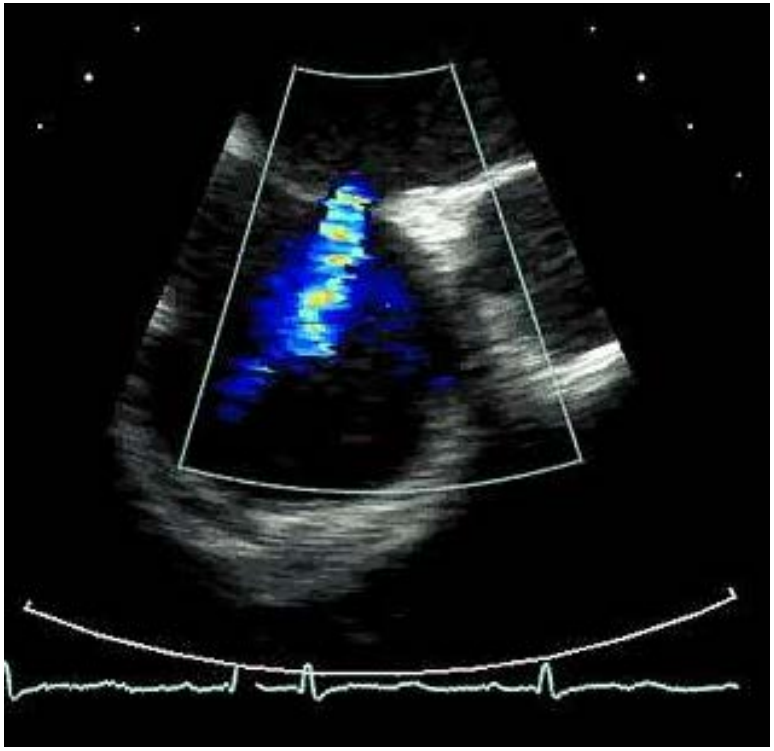

DIAGNOSTICO

- ECOCARDIOGRAMA

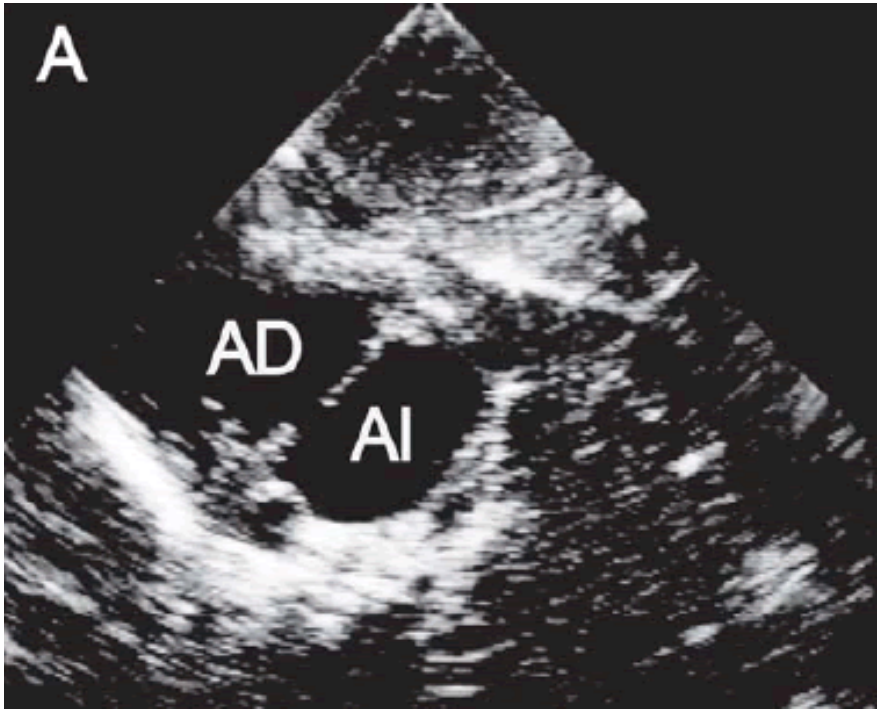

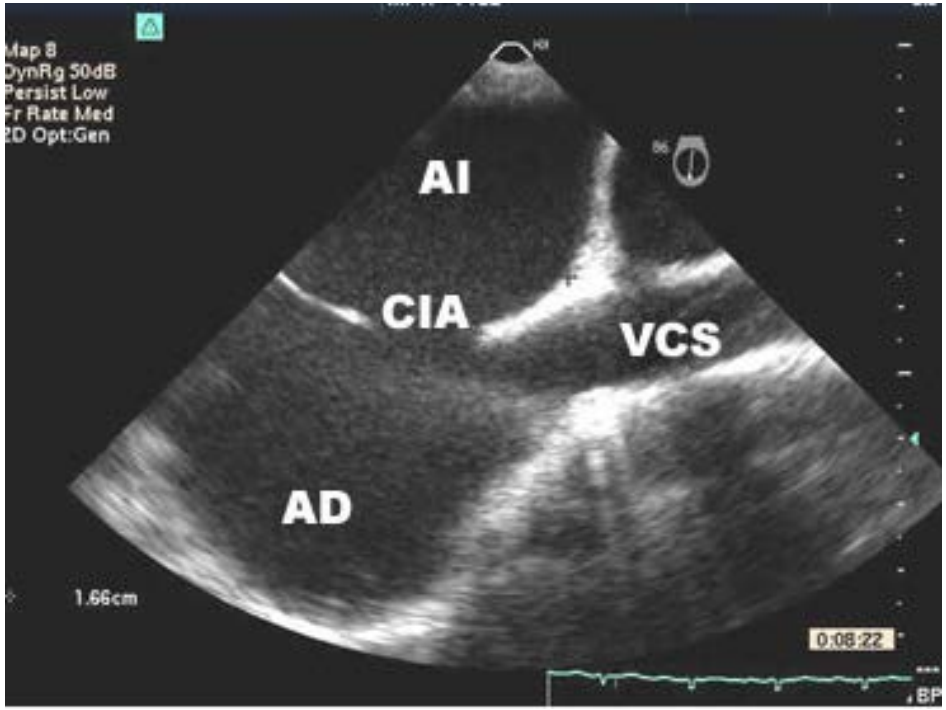

ECO TRIDIMENCIONAL CIA

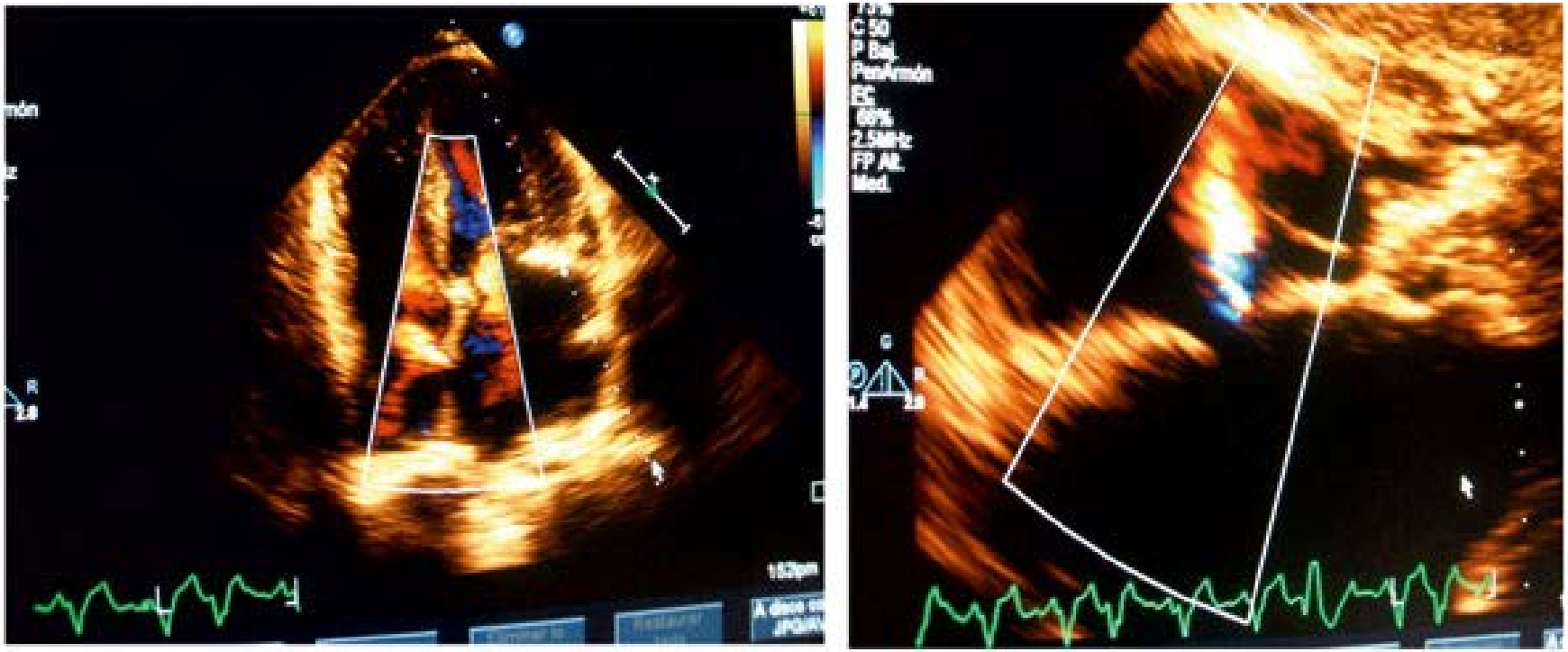

Fig. 4. Comunicación interauricular tipo foramen oval permeable desde vista de 4C apical y subcostal.

EXAMENES COMPLEMENTARIOS

- ECG
  - HIPERTROFIA VD
  - EJE DER
  - BRDHH
  - BAV

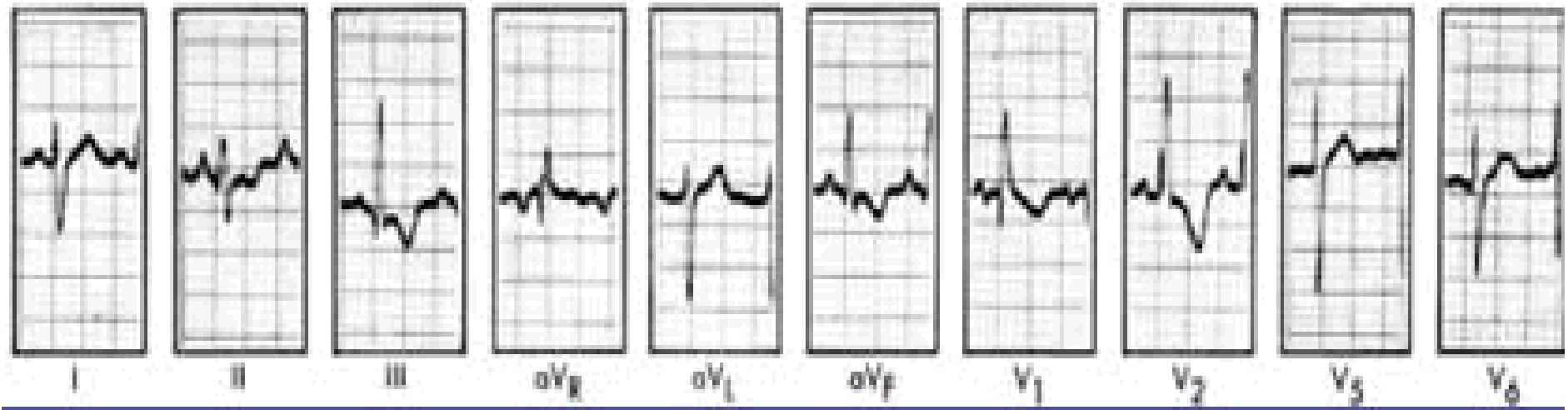

EXAMENES COMPLEMENTARIOS

- Rx TORAX
  - HIPERFLUJO PULMONAR
  - CARDIOMEGALIA CAV DER
  - PULMONAR ABOMBADA

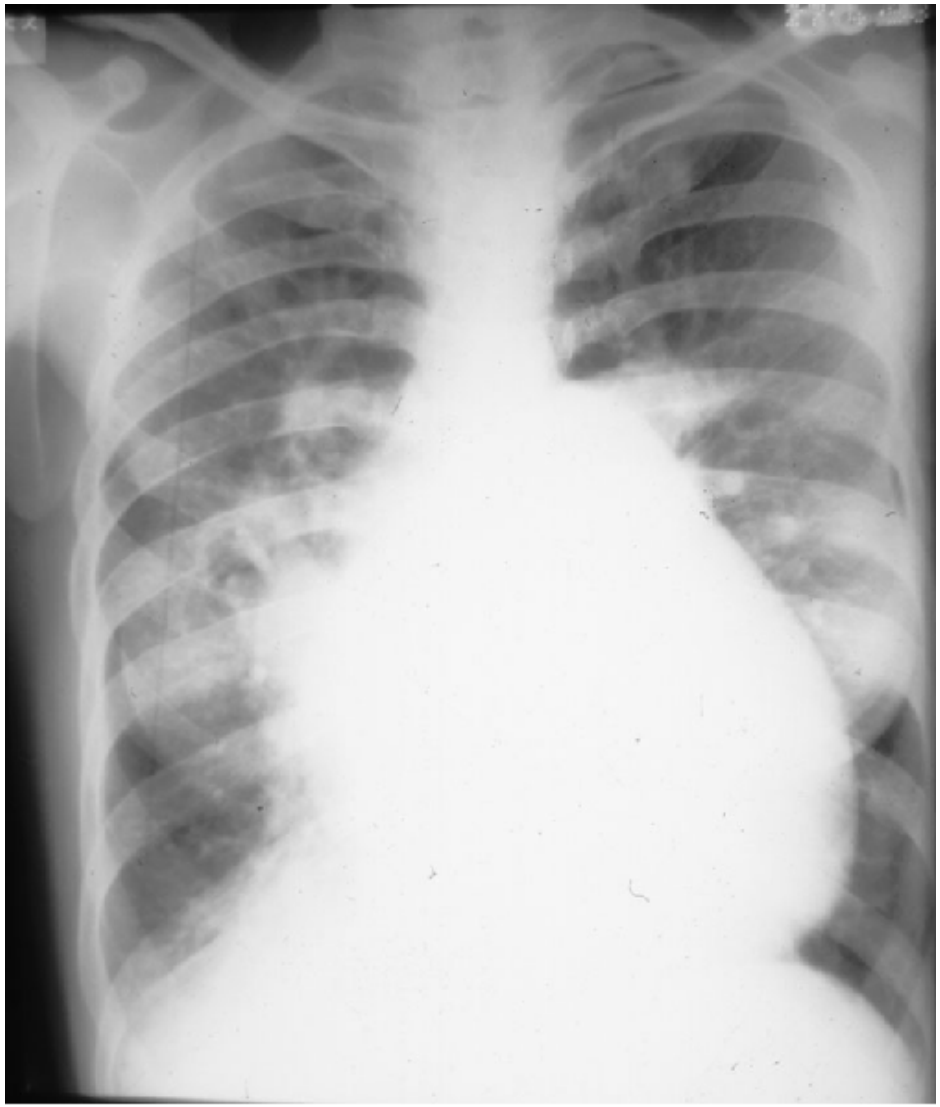

EXAMENES COMPLEMENTARIOS

- CATETERISMO
  - SALTO OXIMETRO EN AD

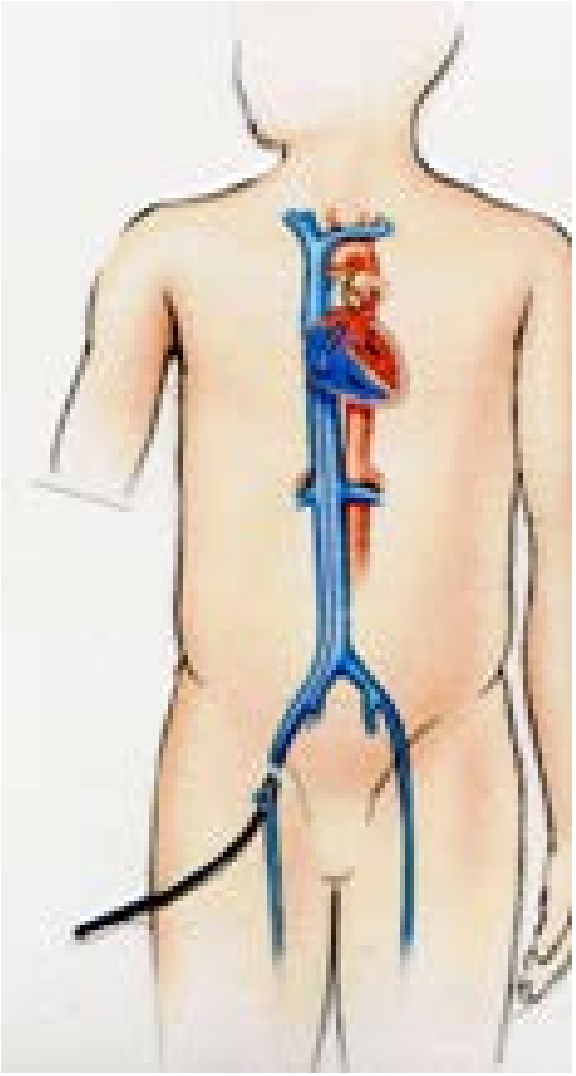

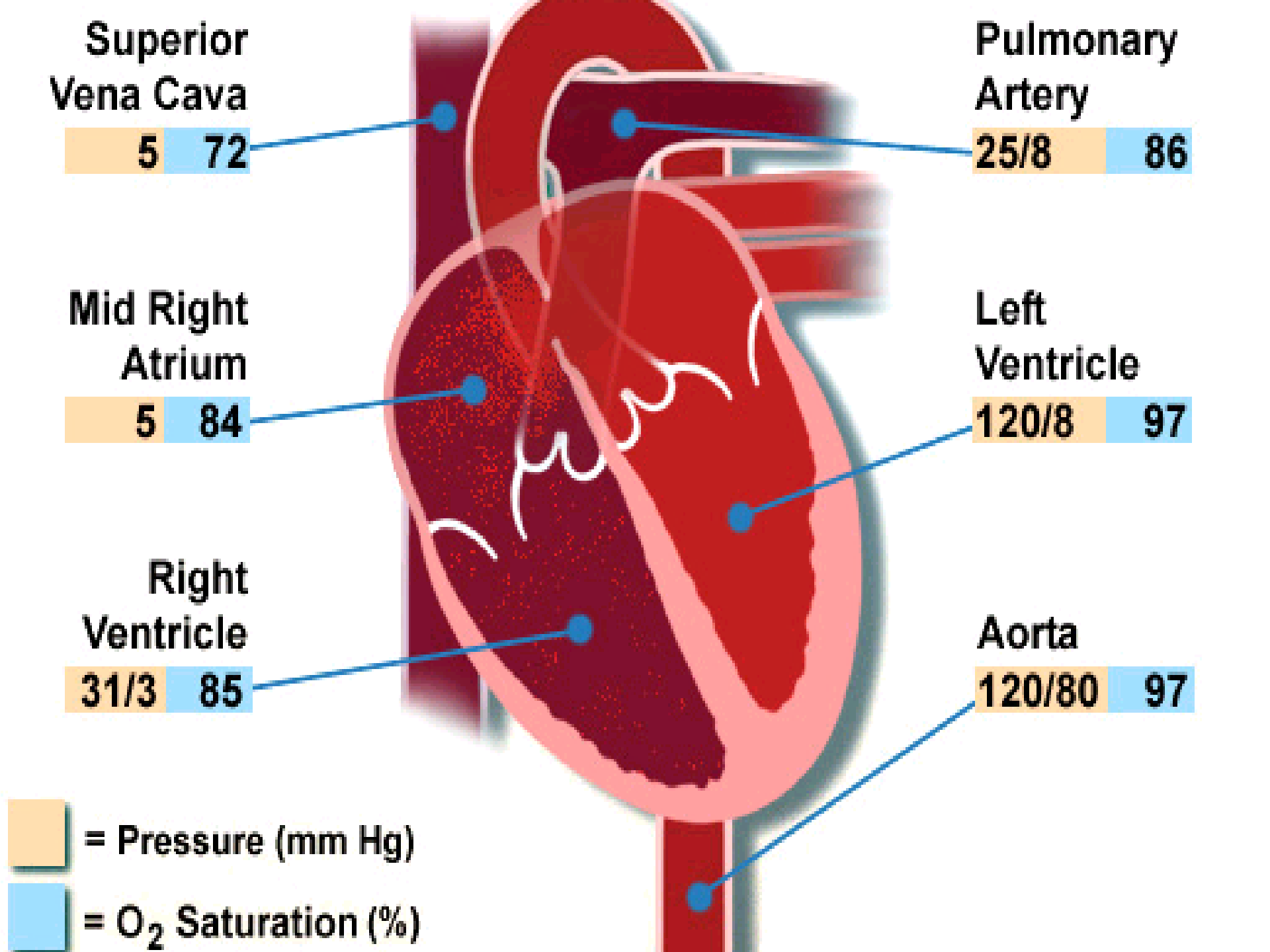
Superior Vena Cava
5 72
Pulmonary Artery
25/8 86
Mid Right Atrium
5 84
Left Ventricle
120/8 97
Right Ventricle
31/3 85
Aorta
120/80 97
= Pressure (mm Hg)
= O_2 Saturation (%)

PRONOSTICO Y TRATAMIENTO

- CIERRE ESPONTANEO HASTA LOS 2-5 ANOS
- CORRECCION QUIRURGICA RECOMENDADA A LOS 3-6 ANOS
  - QP:QS>1,5-2
  - MORTALIDAD <2%
- EN PACIENTES OPERADOS >40ANOS:
  - CONTROL PERIODICO ARRITMIAS AURICULARES
  - EMBOLIA CEREBRAL
  - IC
- -

PRONOSTICO Y TRATAMIENTO

- NO SE REALIZA CIRUGIA EN:
  - QP:QS<1-1,5
  - SIND EISENMENGER
- COMPLICACIONES:
  - PERSISTENCIA SHUNT
  - FORMACION TROMBOS
  - ROTURA DISPOSITIVO
  - ARRITMIAS
  - MUERTE SUBITA

TRATAMIENTO

- CIRUGIA
  - CIERRE DEL DEFECTO CON SUTURA DIRECTA

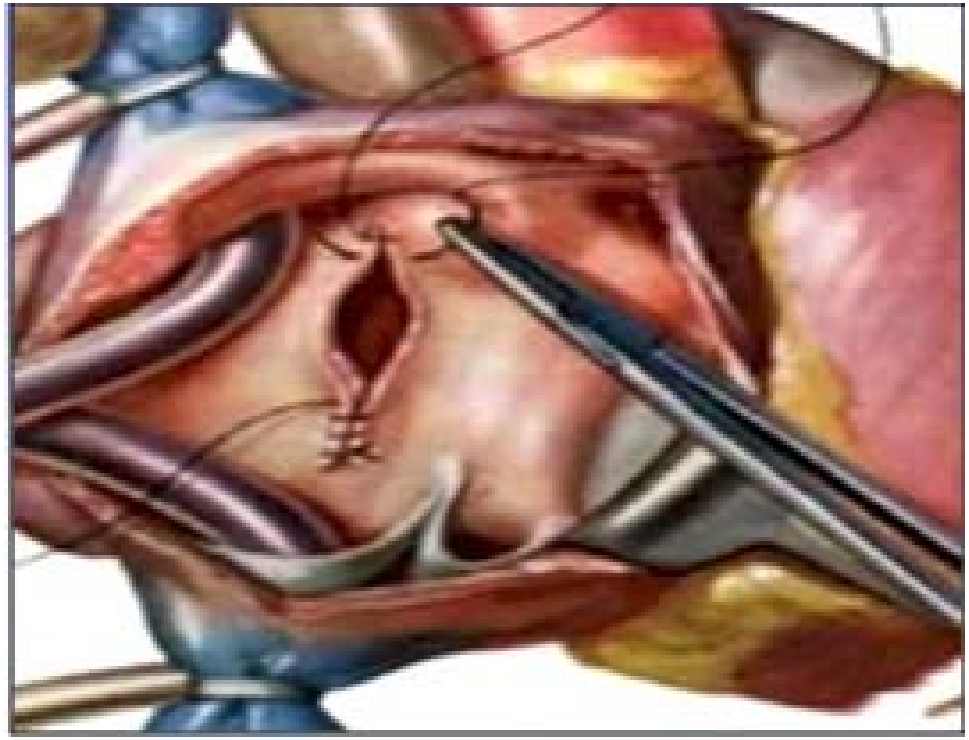

TRATAMIENTO

- CIRUGIA
  - CIERRE PERCUTANEO
    - DISPOSITIVO "AMPLATZER"

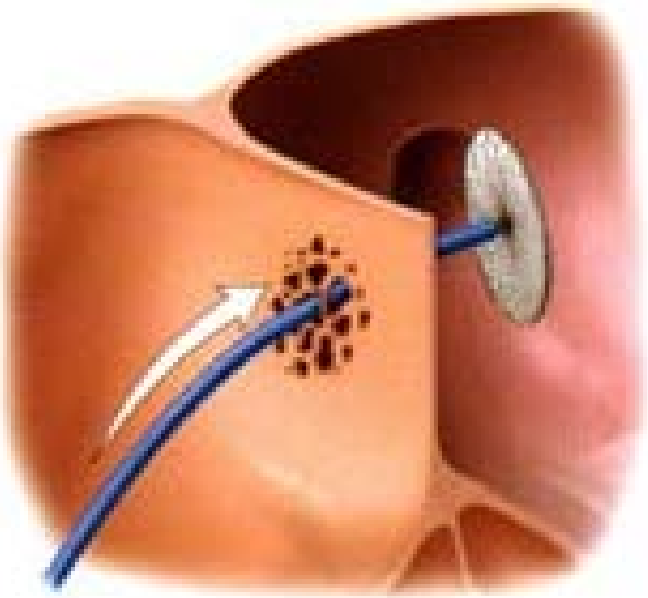

TRATAMIENTO

- CIERRE PERCUTANEO: AMPLATZER

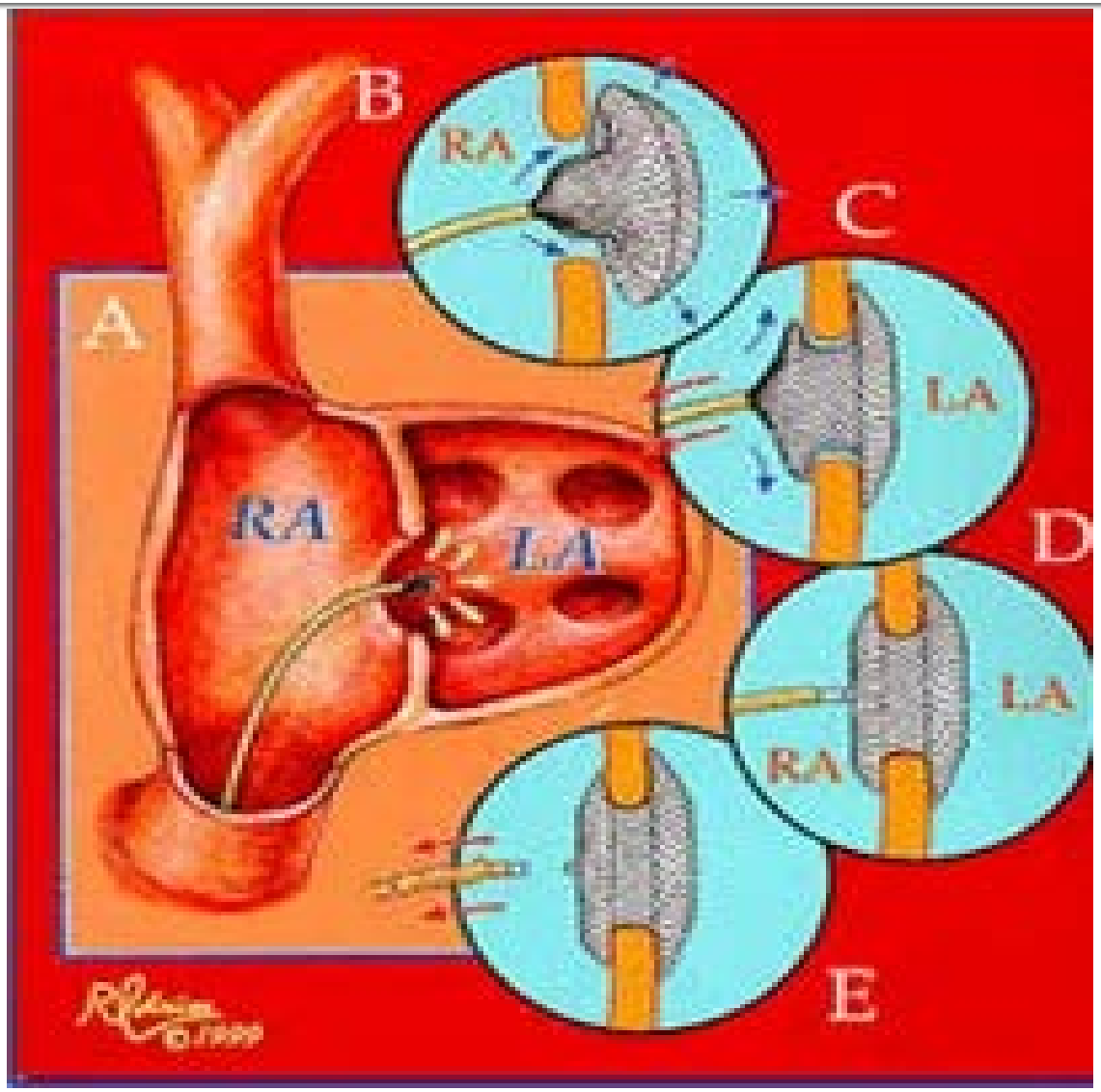

TRATAMIENTO

- COLOCACION AMPLATZER

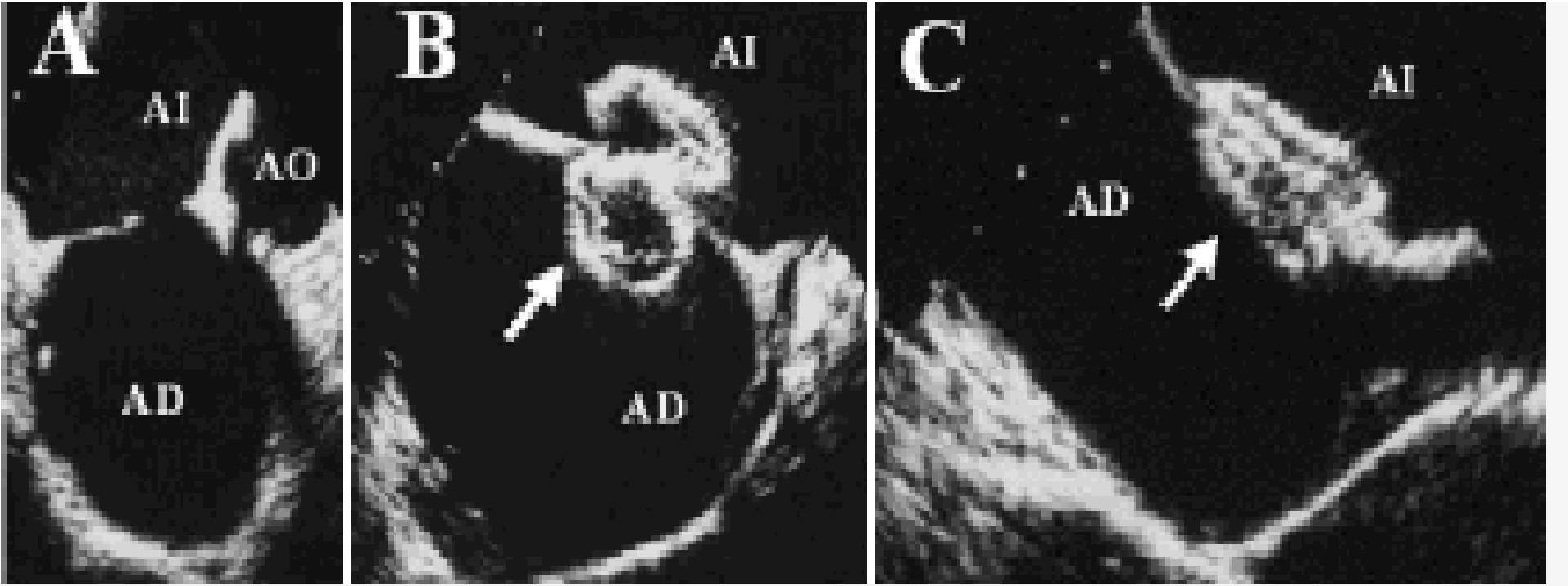

Fig. 6. A, B y C: ecocardiograma transesofágico durante la colocación de dispositivo Amplatzer (flecha) para cierre percutáneo de una CIA tipo ostium secundum. AD: aurícula derecha; AI: aurícula izquierda.

TRATAMIENTO

- AMPLATZER

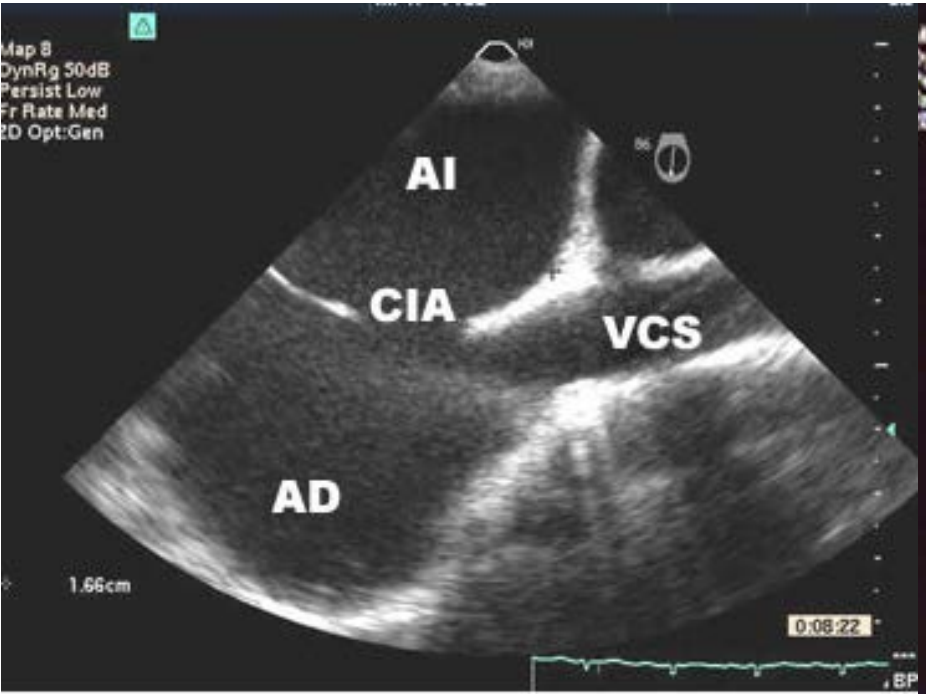

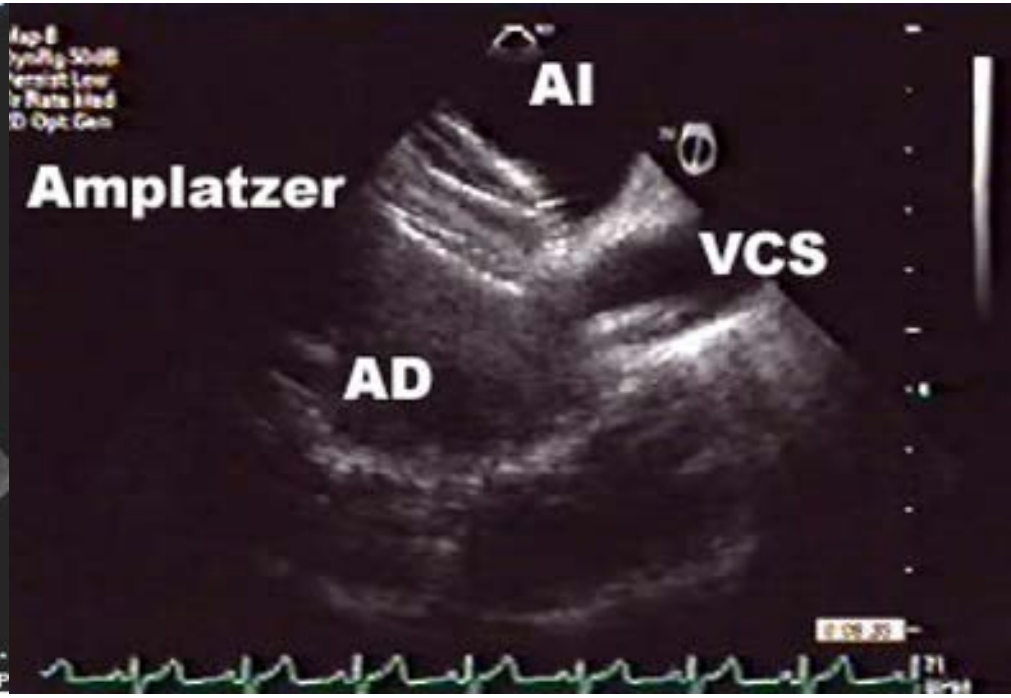

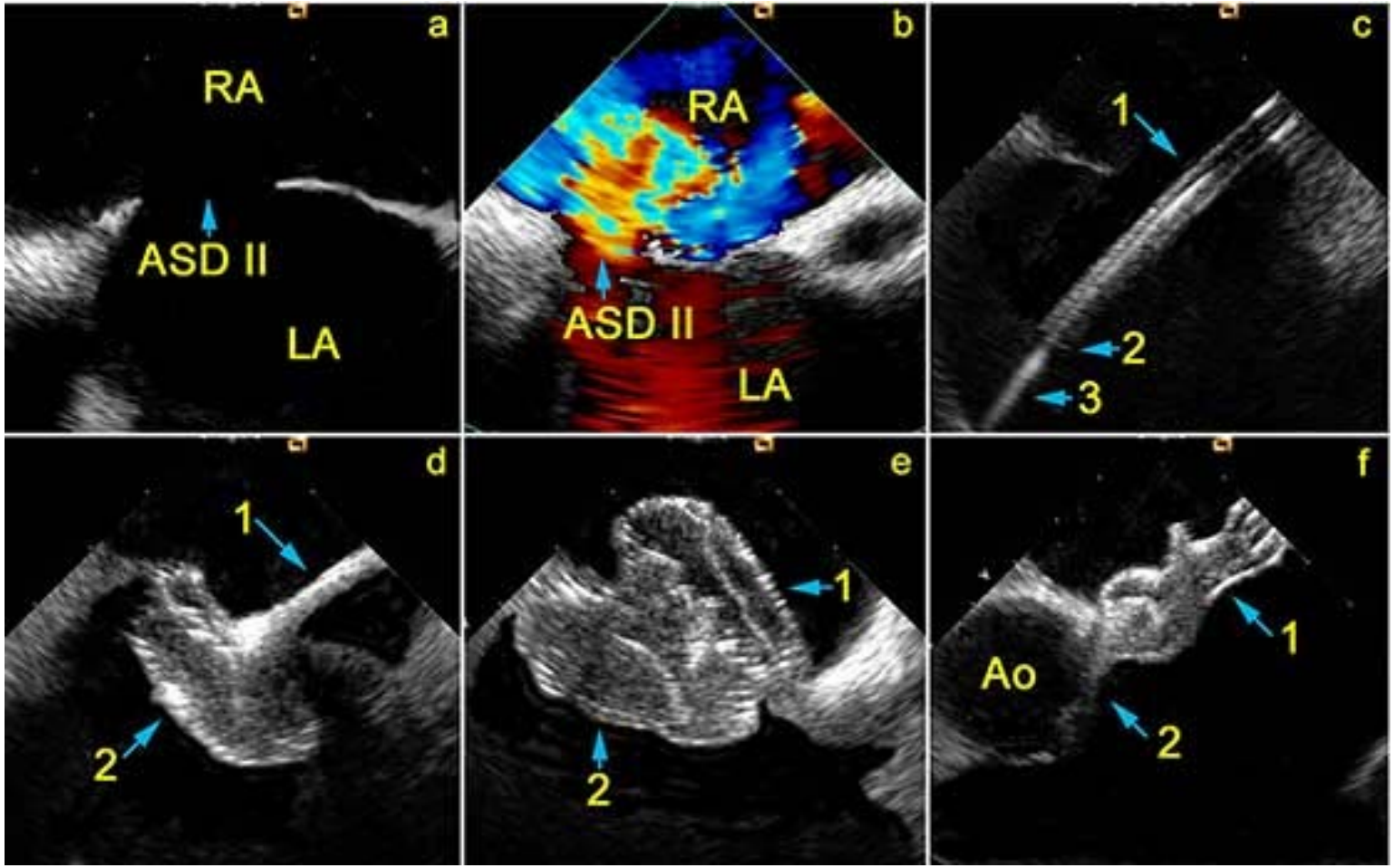

Guidance of ASD device closure by intracardiac echocardiography. Ao, aorta; ASD, atrial septal defect; LA, left atrium; RA, right atrium; 1c, long access sheath; 2c, end of access sheath in the left atrium; 3c, guidewire; 1d und 2d, delivery cable with the left-sided countercluder opened; 1e und 2e, implanted device still connected to the delivery cable; 1f und 2f, device in its final position.

COMUNICACION INTERVENTRICULAR

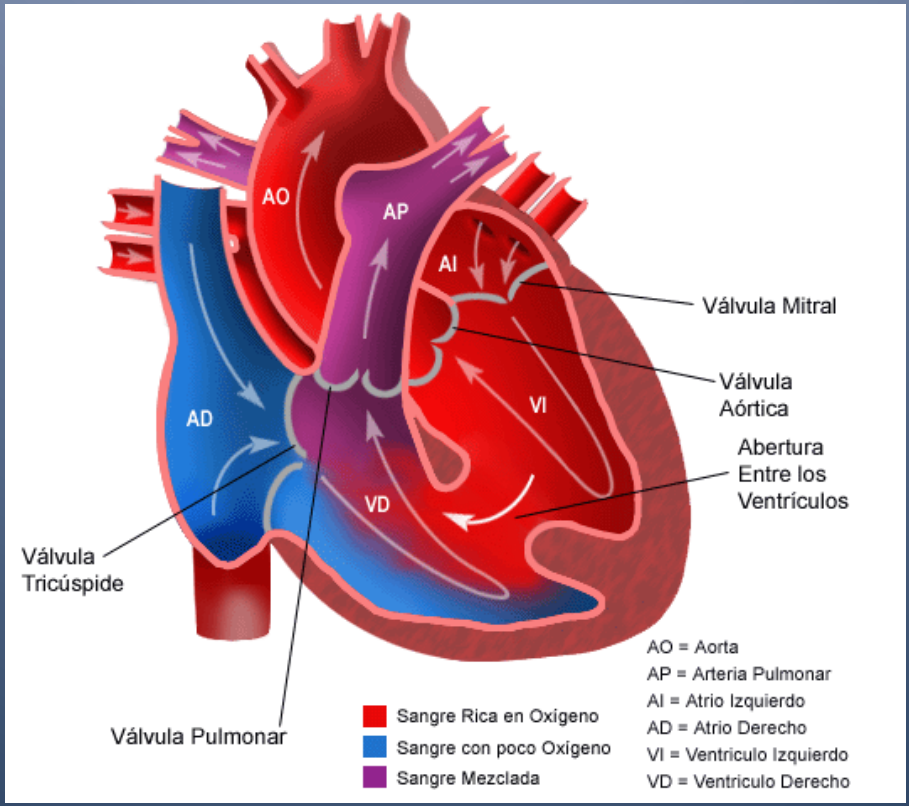

DEFINICION

- PRESENCIA DE DEFECTO EN TABIQUE INTERVERNTRICULAR

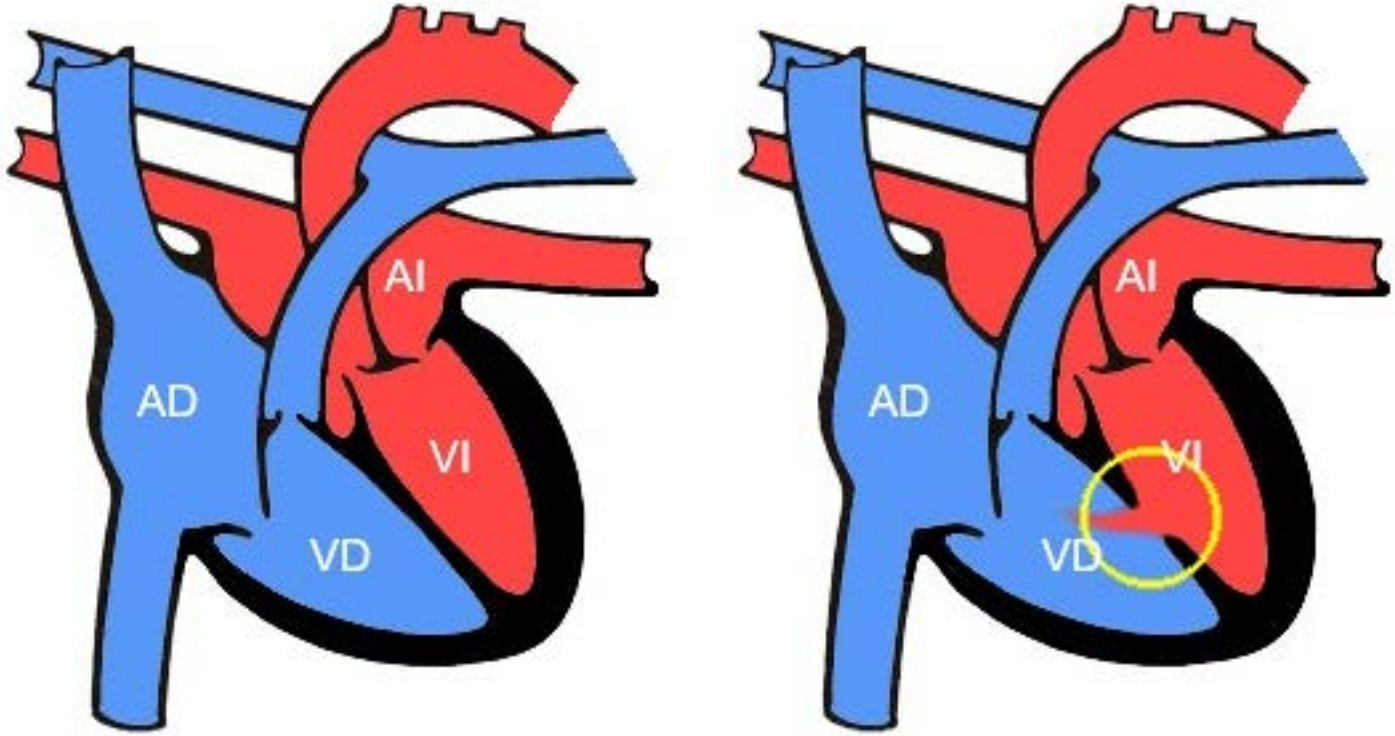

Corazón normal

CIV

COMUNICACION INTERVENTRICULAR

El defecto del tabique ventricular es una abertura anormal en la pared que separa los dos ventrículos

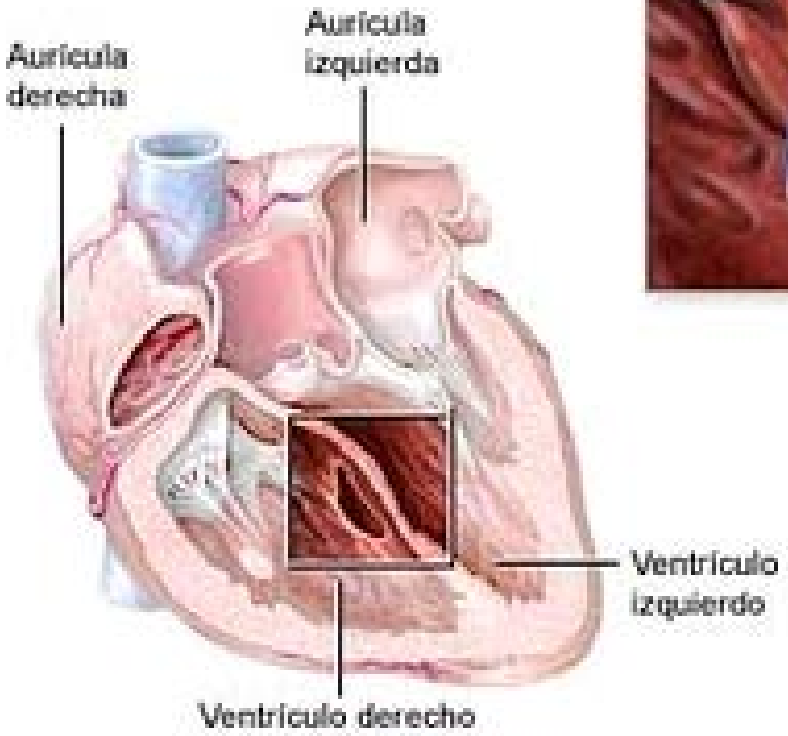

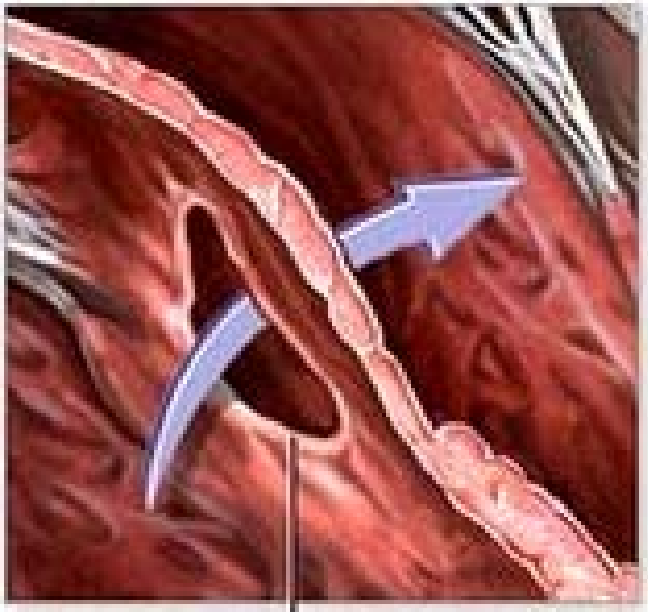

Defecto del tabique ventricular

TIPOS

- NUMERO:
  - UNICO
  - MULTIPLE
- LOCALIZACION
  - VIADE ENTRADA
  - PERIMEMBRANOSO 75%
    - PORCION SUPERIOR
  - MUSCULAR-ROGER 20%
    - SEPTO MUSCULAR
  - INFUNDIBULAR
    - INFUNDIBUO PULMONAR

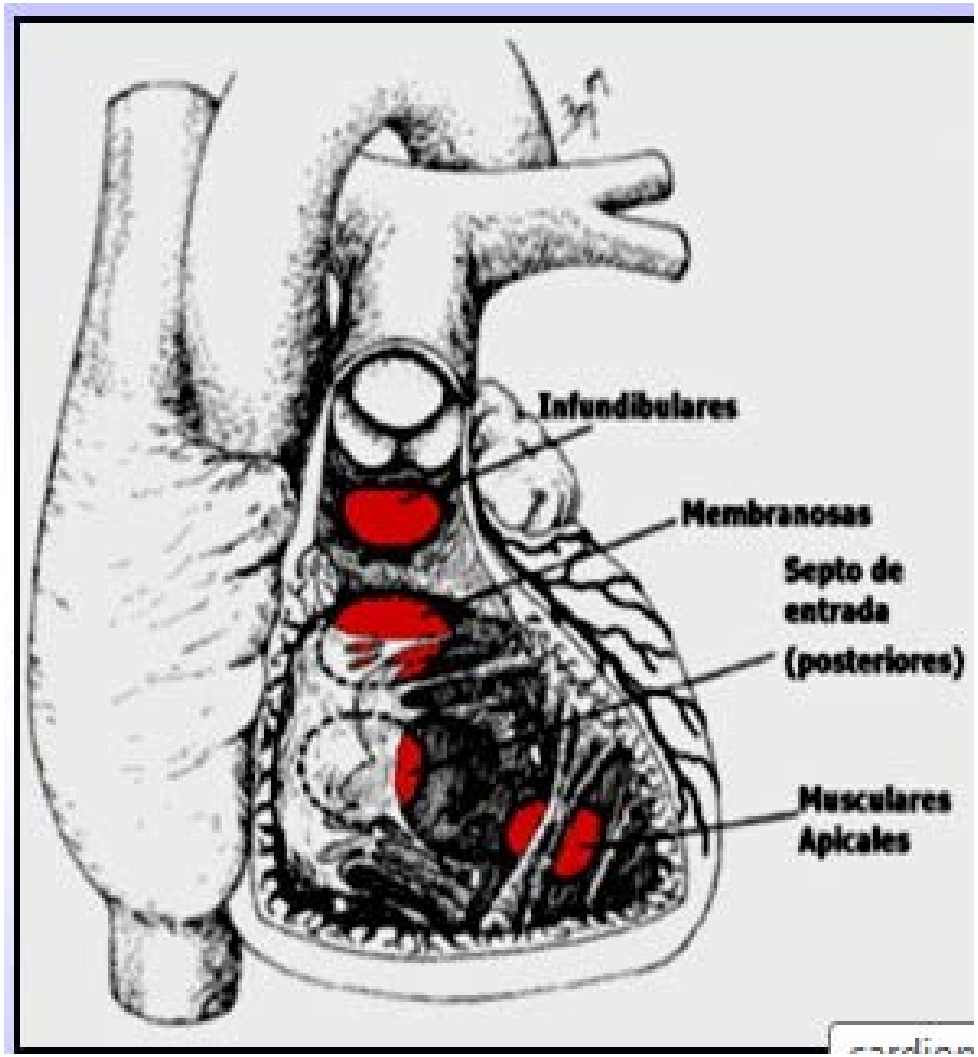

CLASIFICACION

- SEGUN TAMAñO DE LESION:

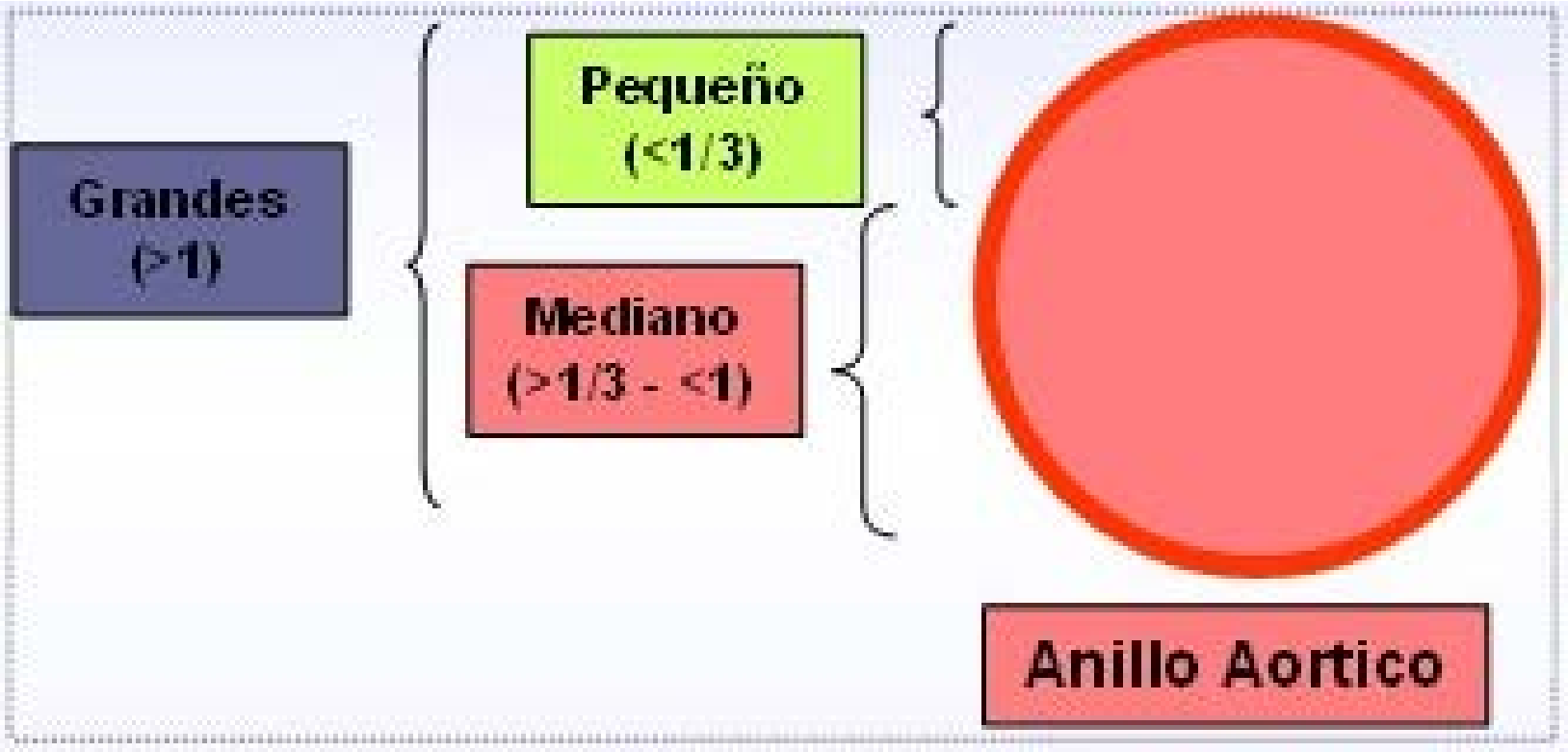

FISIOPATOLOGIA

- SHUNT IZQ→ DER
- HIPERFLUJOPUL MONAR→ HAP
- SOBRECARGA VENTRICULAR DERECHA

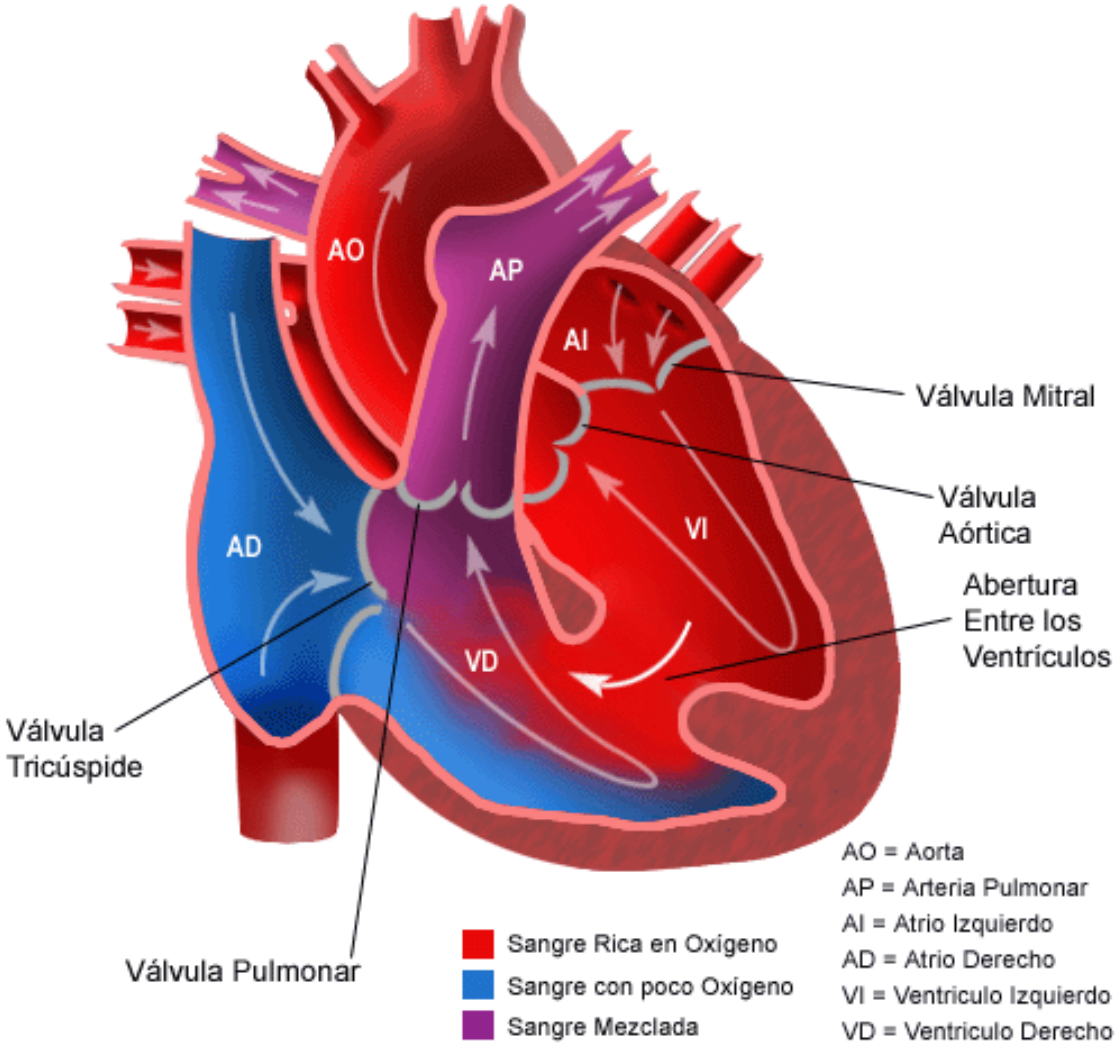

FISIOPATOLOGIA

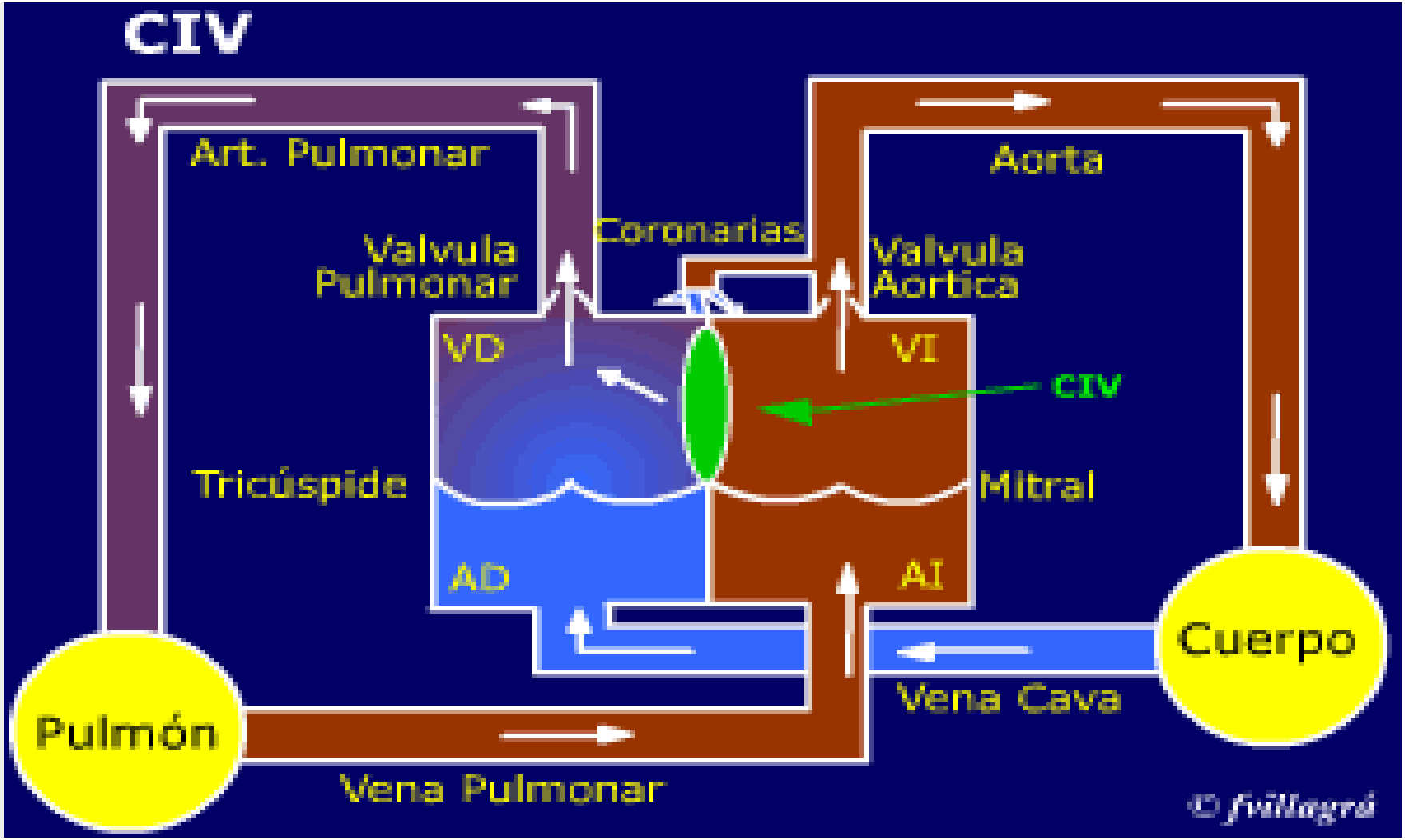

FISIOPATOLOGIA

- **CIV <1cm ⇨ ROGER**
  - CORTOCIRCUITO IZQ→DER
  - QP/QS<1,5:1,1
- **CIV 1-1,5cm**
  - CORTOCICUITO PUEDE SER IMPORTANTE
- **CIV 1,5-3cm ⇨ CIV HIPERTENSA**
  - SE IGUALAN LAS PRESIONES
  - CIV EISENMENGER
  - CIERRE QUIRURGICO CONTRAINDICADO

CLINICA

- CIV PEQUEñA
  - ASINTOMATICO
  - SOPLO HOLOSISTOLICO, FUERTE, ASPERO
- CIV DE GRAN TAMAñO
  - SOPLO HOLOSISTOLICO-EN BARRA -MESOCARDIO
  - DISNEA
  - CRECIMIENTO NORMAL
  - SUDORACION PROFUSA
  - ⇧INFECCIONES PULMONARES
  - IC

CLINICA

- CIV PEQUEñA:
  - SOPLO PANSISTOLICO
- CIV MEDIANA:
  - SOPLO SISTOLICO
  - SOPLO MESODIASTOLICO
  - R3 GALOPE
  - DESDOBLAMIENTO R2
- CIV GRANDE
  - ⇩INTENSIDAD SOPLO

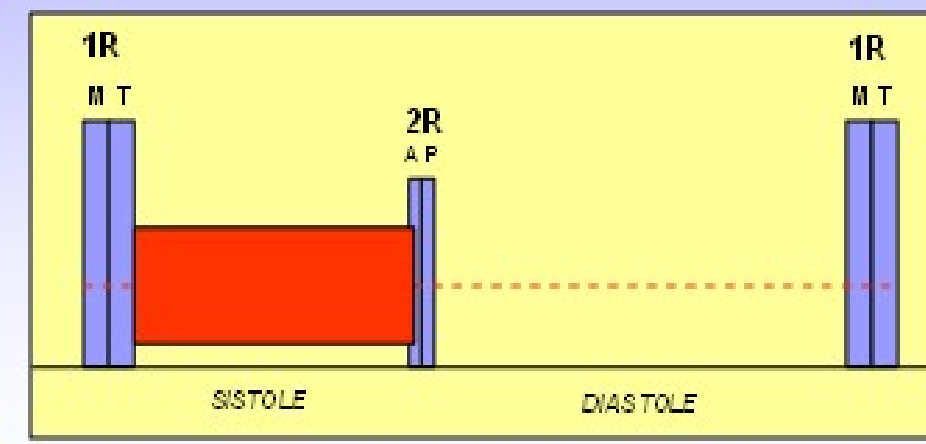

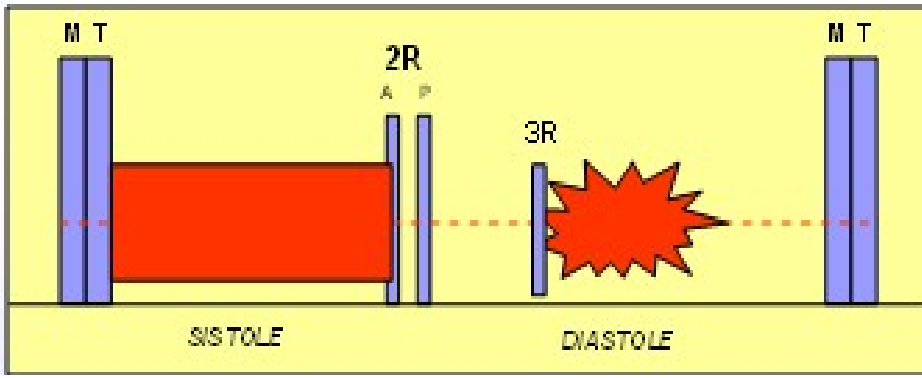

DIAGNOSTICO

- ECOCARDIOGRAFIA

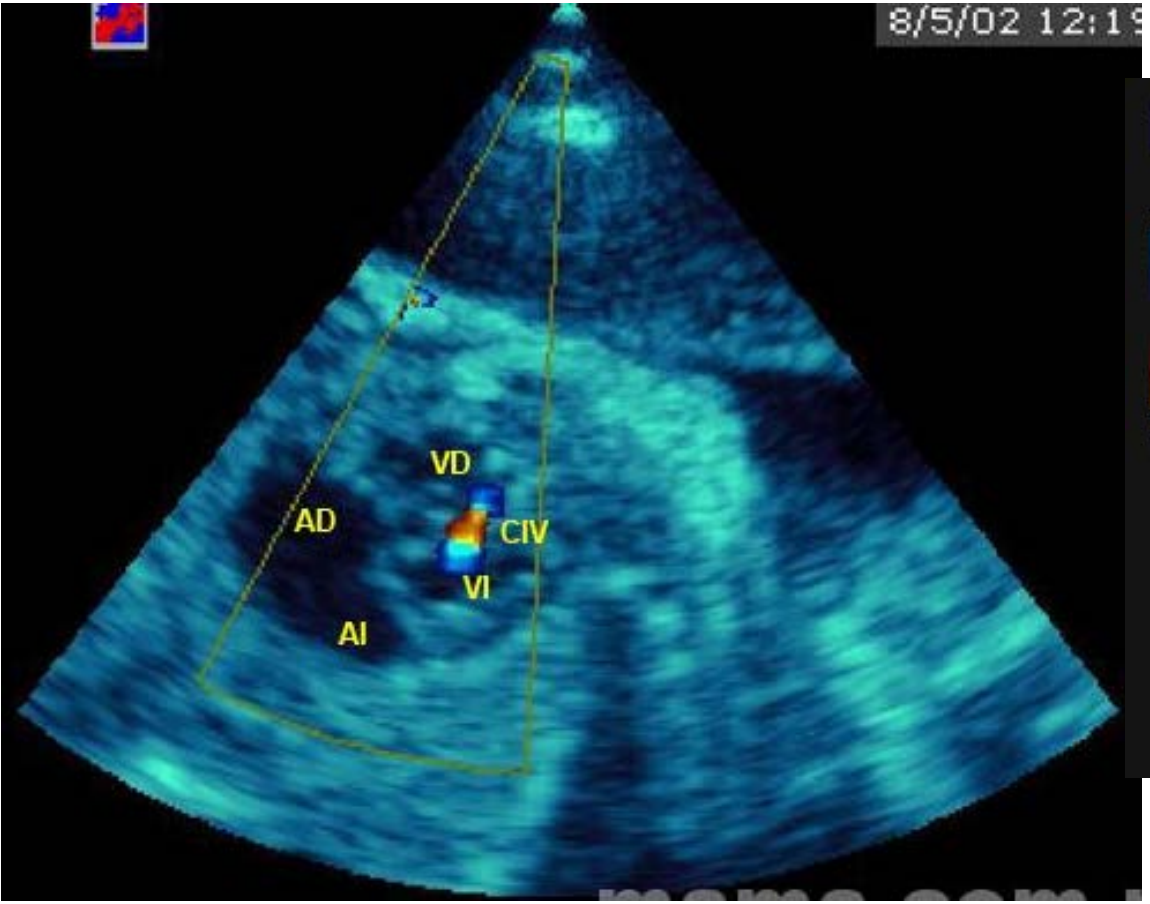

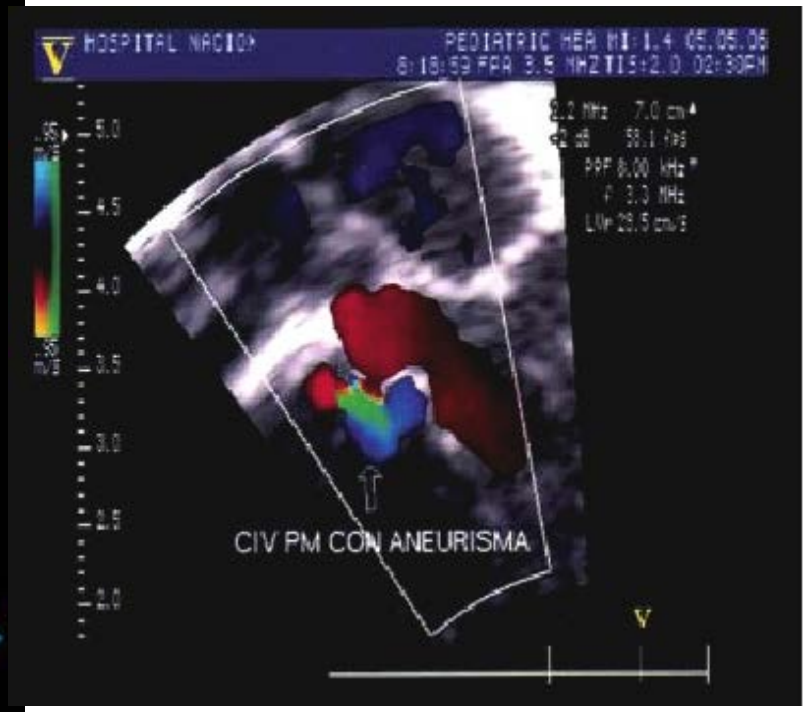

CIV ECOTRIDIMENCIONAL

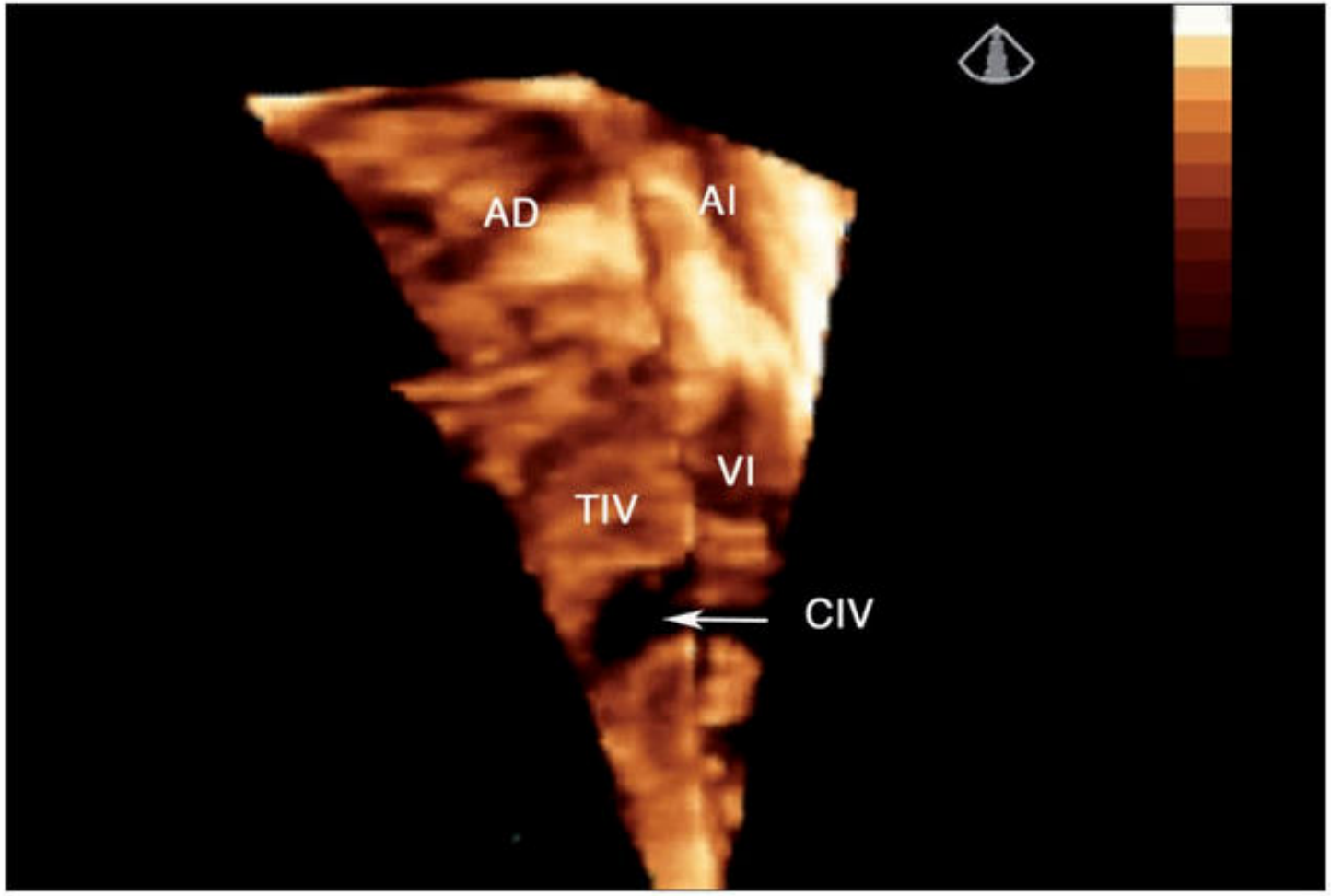

EXAMENES COMPLEMENTARIOS

- RADIOGRAFIA TORAX
  - CARDIOMEGALIA
  - HIPERAFLUJO PULMONAR
  - PULMONAR ABOMBADA

EXAMENES COMPLEMENTARIOS

- ECG
  - HIPERTROFIA BIVENTRICULAR
  - HAI

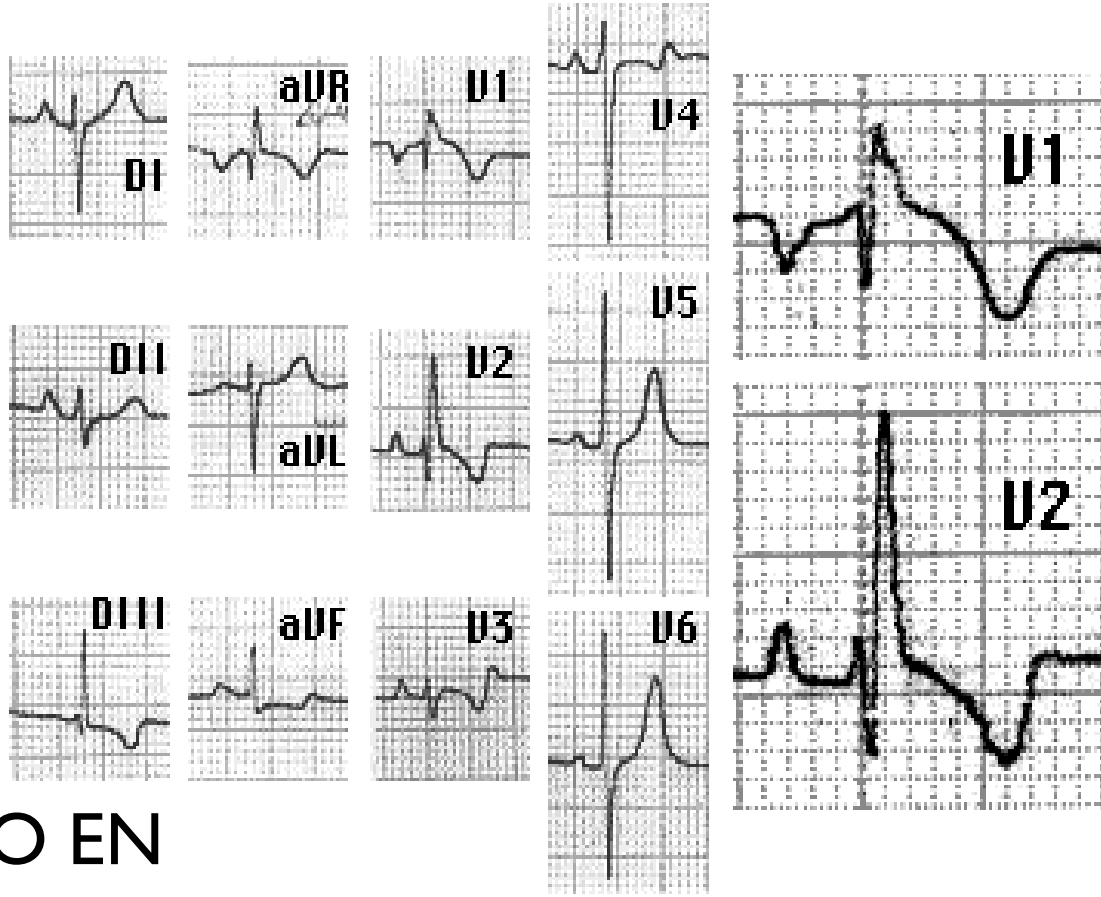

- CATETERISMO
  - SALTO OXIMETRO EN VD

PRONOSTICO Y TRATAMIENTO

- 30-50% CIV MUSCULARES PEQ CIERRAN EL PRIMER AñO DE VIDA
- INCACION DE CIRUGIA:
  - SHUNT IZQ-DER SIGIFICATIVO
    - QP:QS=>1,5-2
    - AUSENCIA RESISTENCIA PULMONARES ELEVADAS
  - SINTOMATOLOGIA IC, RETRASO EN CRECIMIENTO
- CONTRAINDICACION CIRUGIA:
  - ⇧RVP - SIND EISENMENGER

TRATAMIENTO

- CIERRE QUIRURGICO: PARCHE

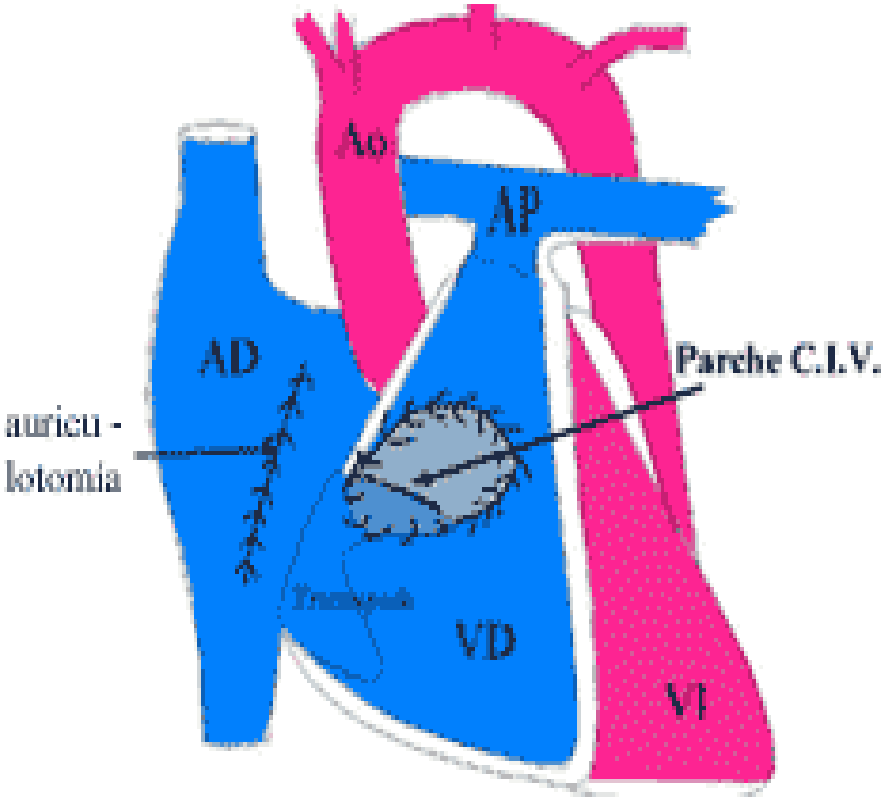

TRATAMIENTO

- CIERRE PERCUTANEO

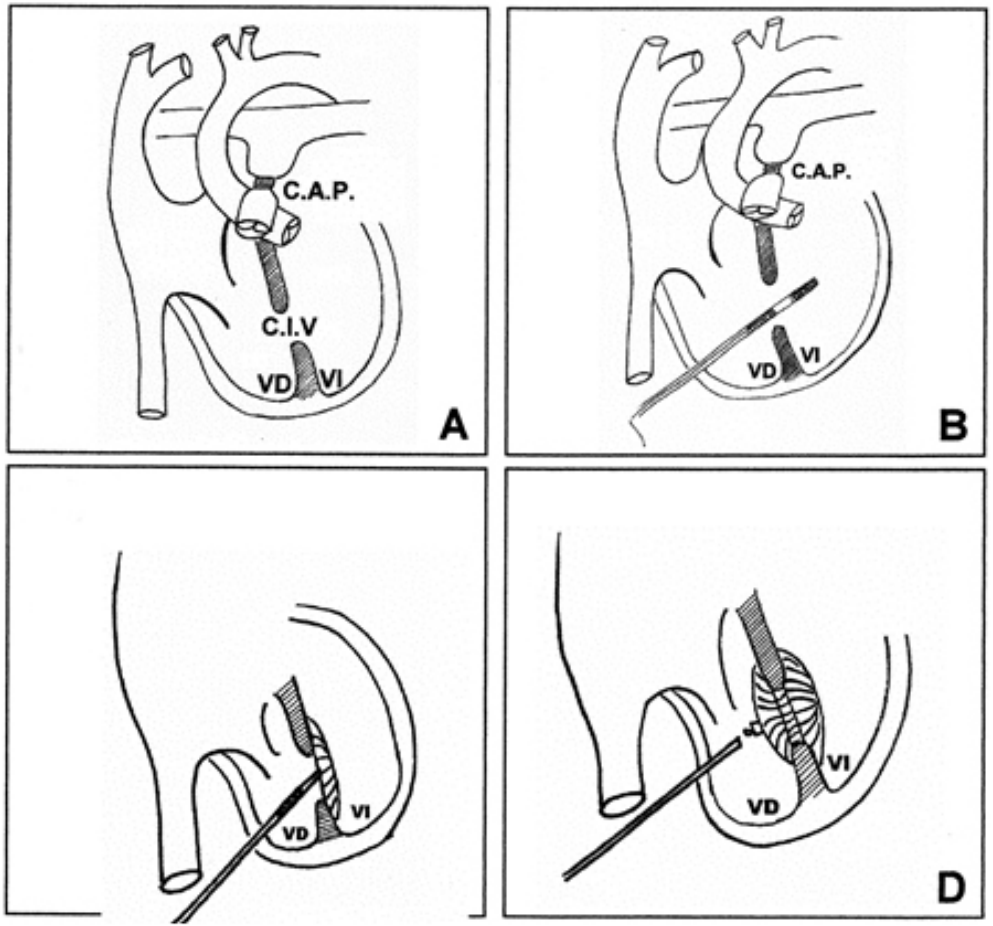

CIERRE PERCUTANEO: Ventriculografia posterior a colocacion Amplatzer

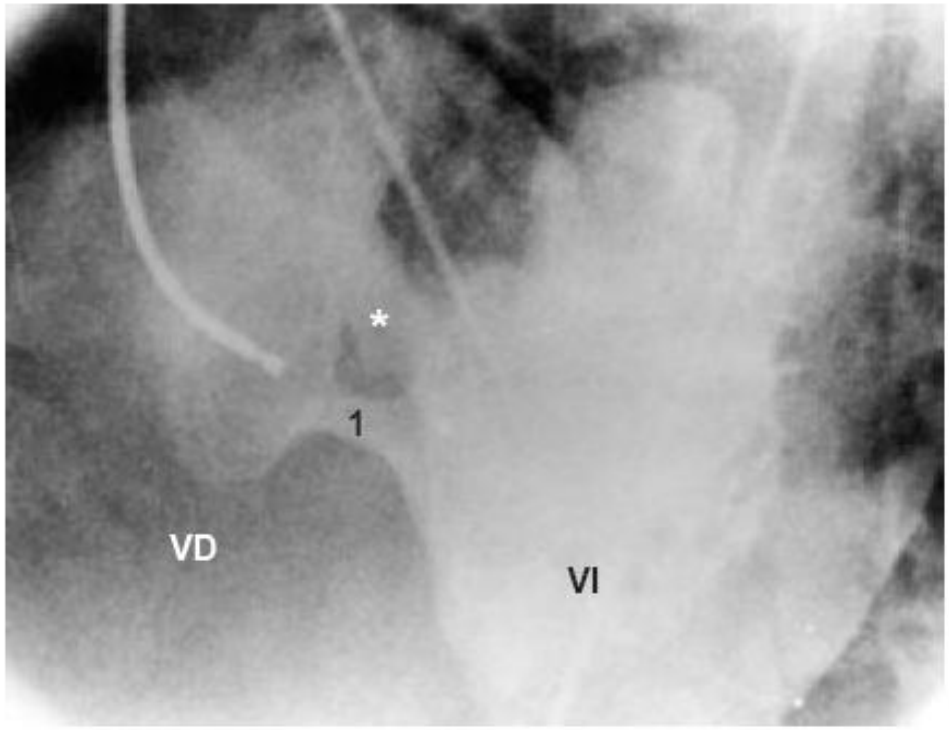

Fig. 3. Ventriculografía izquierda en posición cuatro cámaras posterior a colocación de dispositivo Amplatzer (1) en la comunicación interventricular, se observa otro defecto superior del septum (*). Ventrículo izquierdo (VI). Ventrículo derecho (VD).

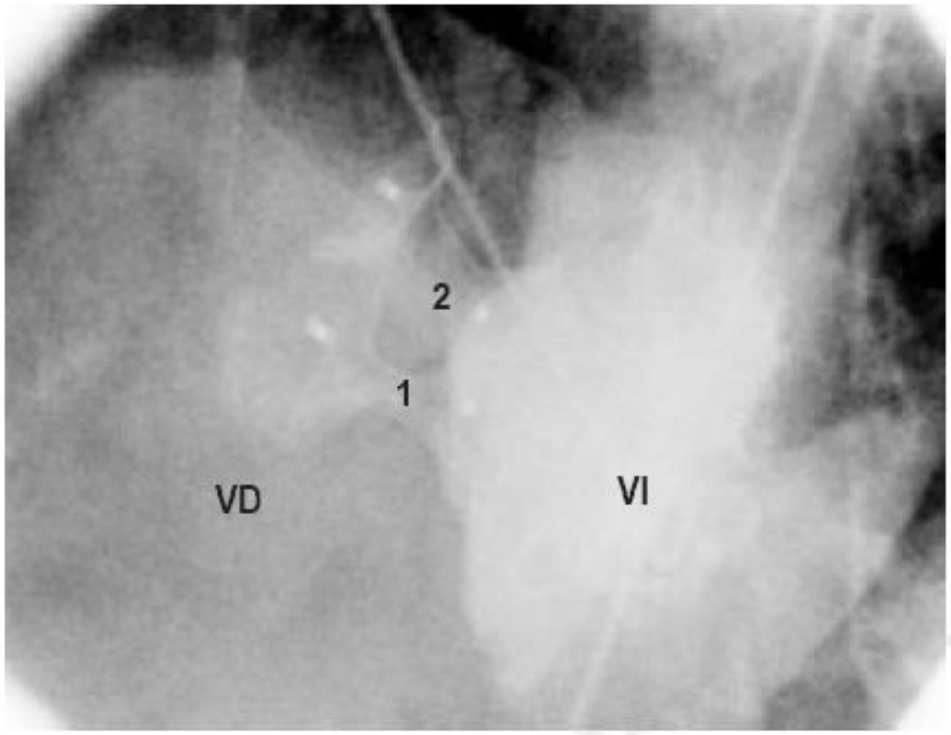

Fig. 4. Ventriculografía izquierda en posición cuatro cámaras, posterior a colocación de segundo dispositivo Amplatzer para ocluir ambos defectos (1,2) con escaso paso de contraste a través de los dispositivos. Ventrículo

CONDUCTO ARTERIOSO PERSISTENTE

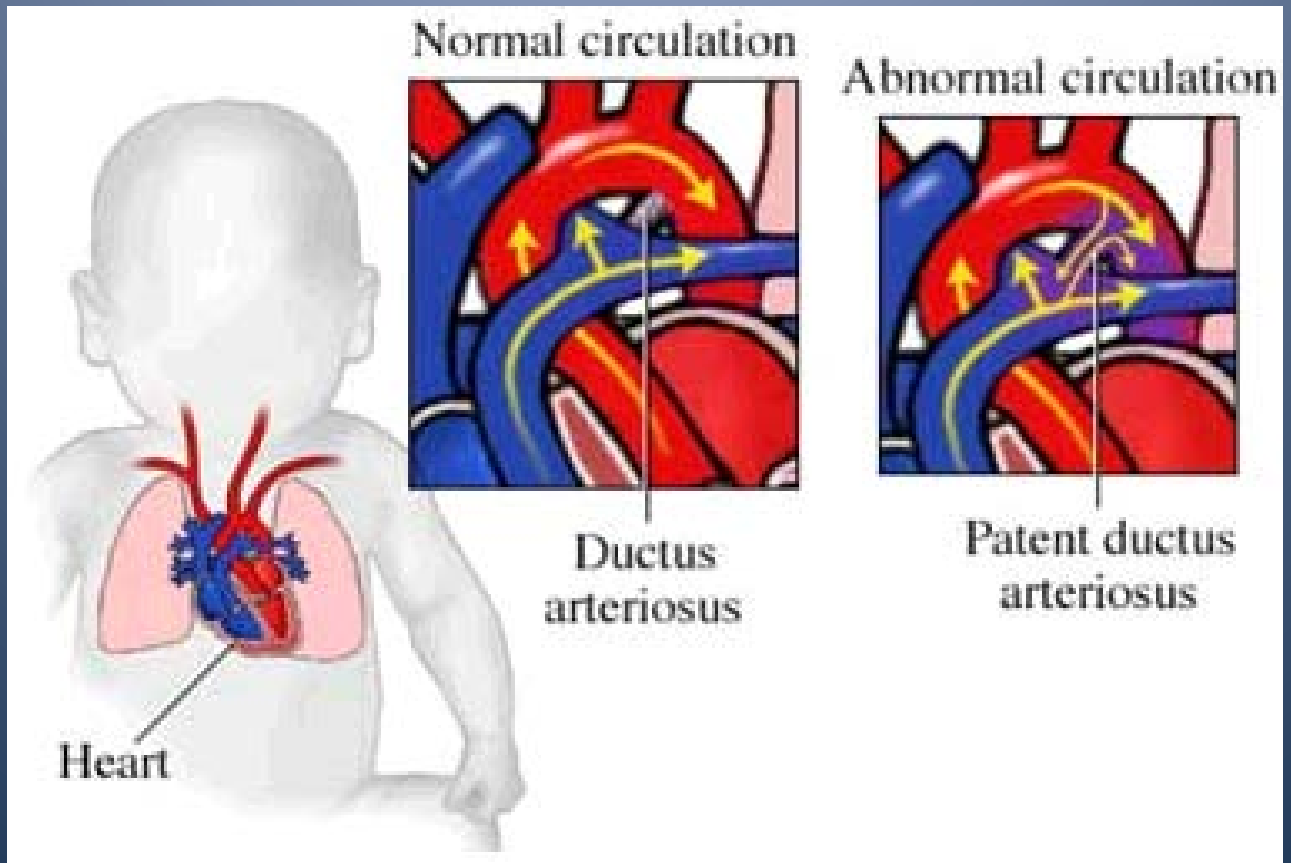

DEFINICION

- PERSISTENCIA DE UNA COMUNICACION ENTRE AORTA Y ARTERIA PULMONAR

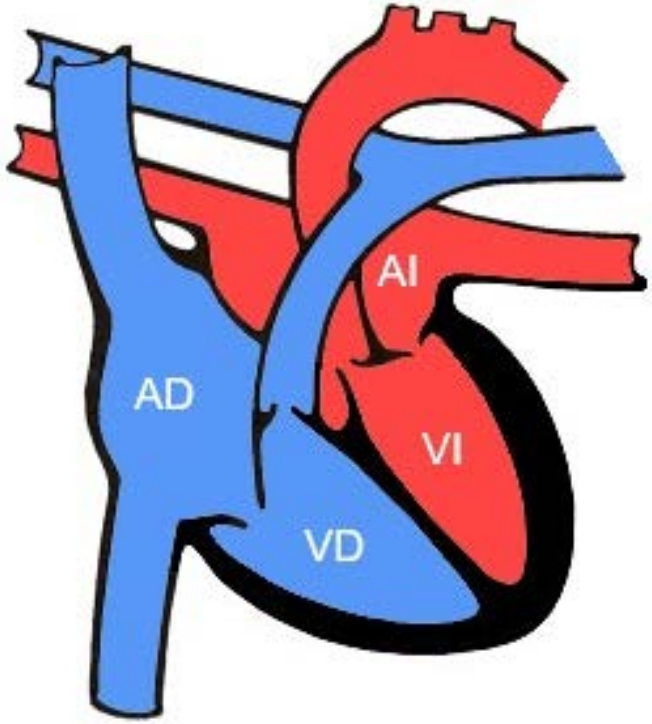

Corazón normal

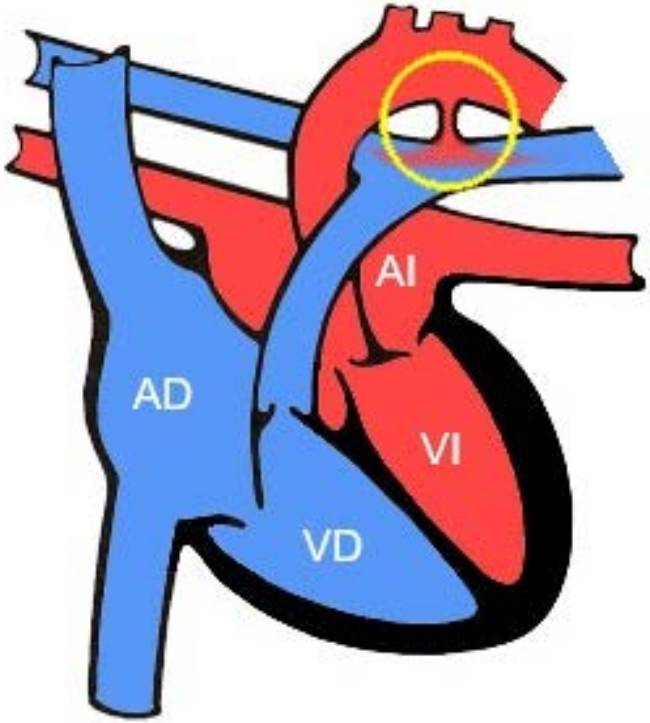

Ductus persistente

FISIOPATOLOGIA

- SHUNT AORTA→ A PULMONAR
- HIPERFLUJO PULMONAR Y SOBRECARGA CAVIDADES IZQUIERDAS

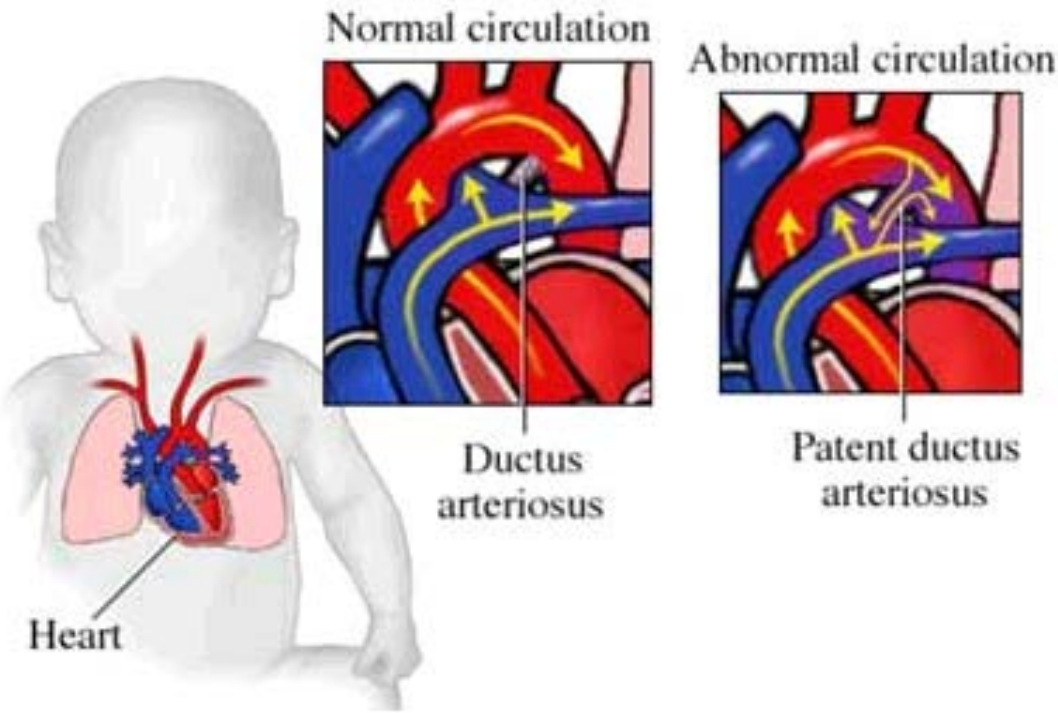

FISIOPATOLOGIA

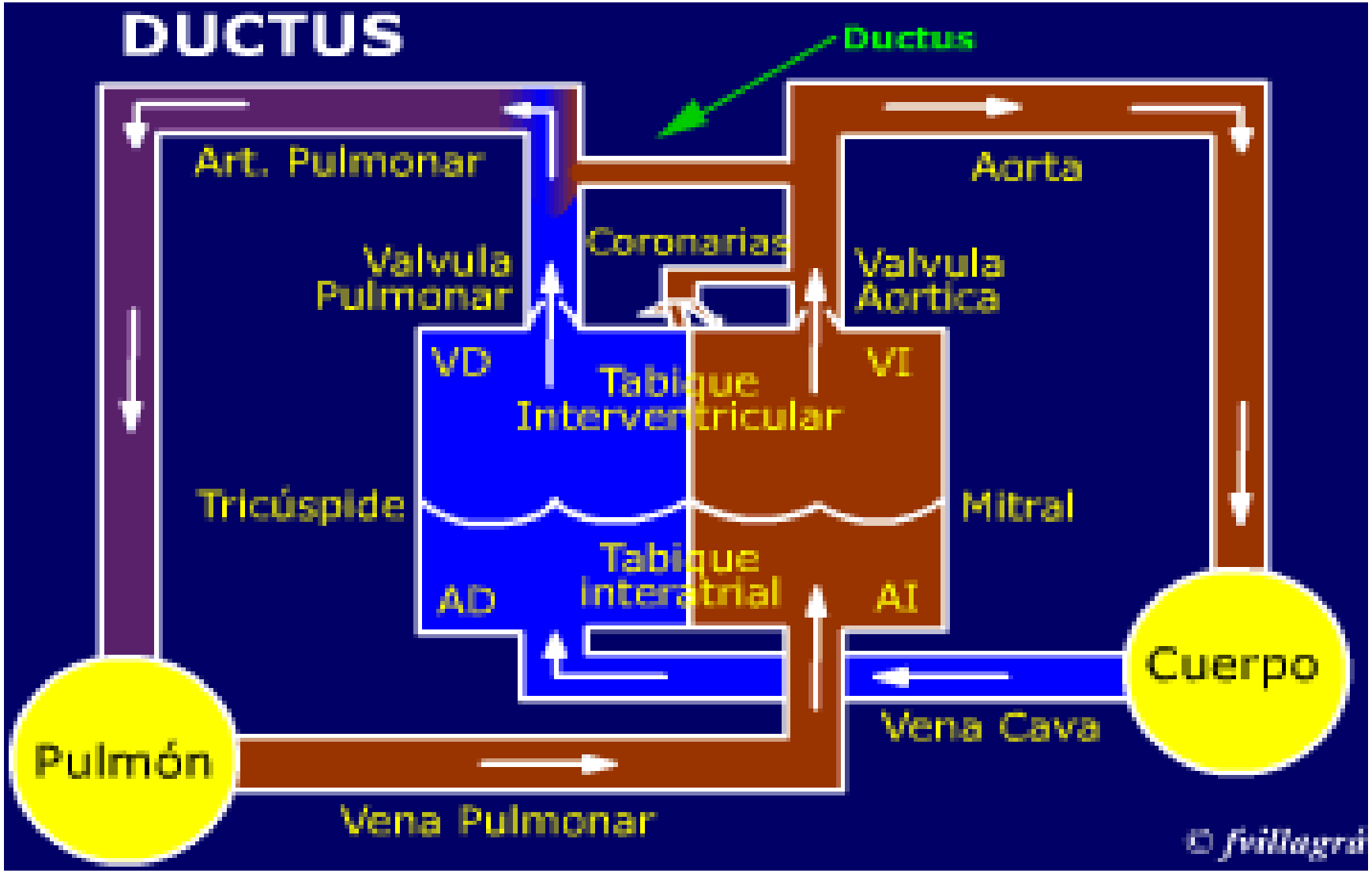

CLINICA

- **CAP < 4mm**
  - ASINTOMATICO
- **CAP 5-8mm**→ ASINTOMATICA HASTA TERCERA DECADA VIDA
  - PULSO ARTERIA CELER Y SALTON
  - SOPLO EN MAQUINARIA, EN FOCO PULMONAR IRRADIADO A REGION INFRACLAVICULAR IZQ
  - DISNEA
  - PALPITACIONES
  - ARRITMIAS AURICULARES
- **CAP GRAN TAMAñO**
  - IC
  - INVERSION DEL SHUNT / CIANOSIS / HAP

EXAMENES COMPLEMENTARIOS

- ECG
  - SOBRECARGA CAVIDADES IZQUIERDAS

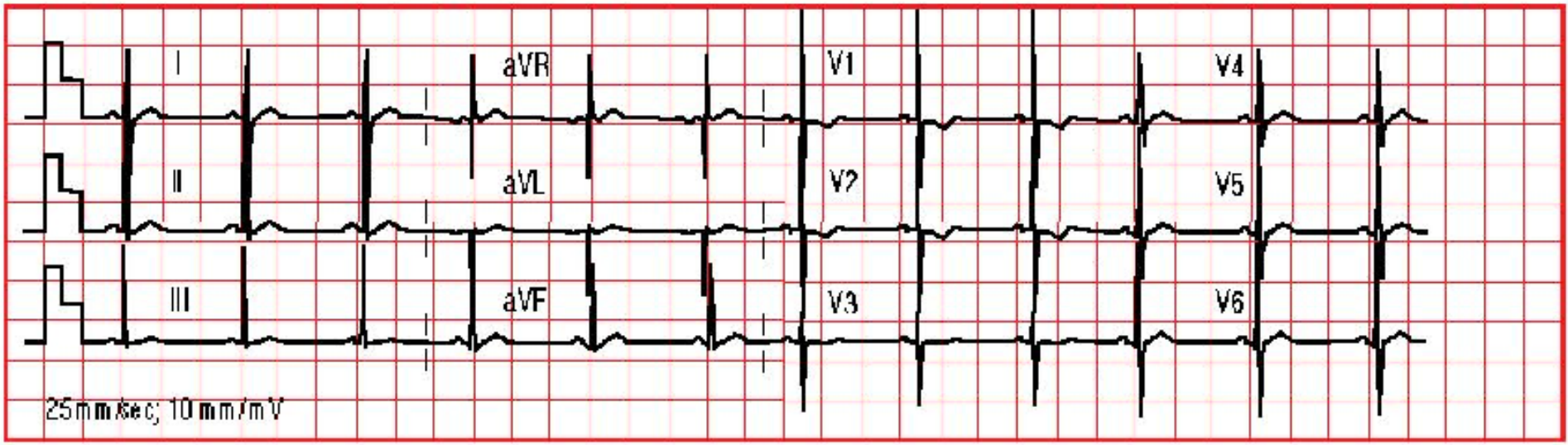

EXAMENES COMPLEMENTARIOS

- RX TORAX:
  - HIPERAFLUJO PULMONAR
  - CARDIOMEGALIA VI
  - PULMONAR ABOMBADA

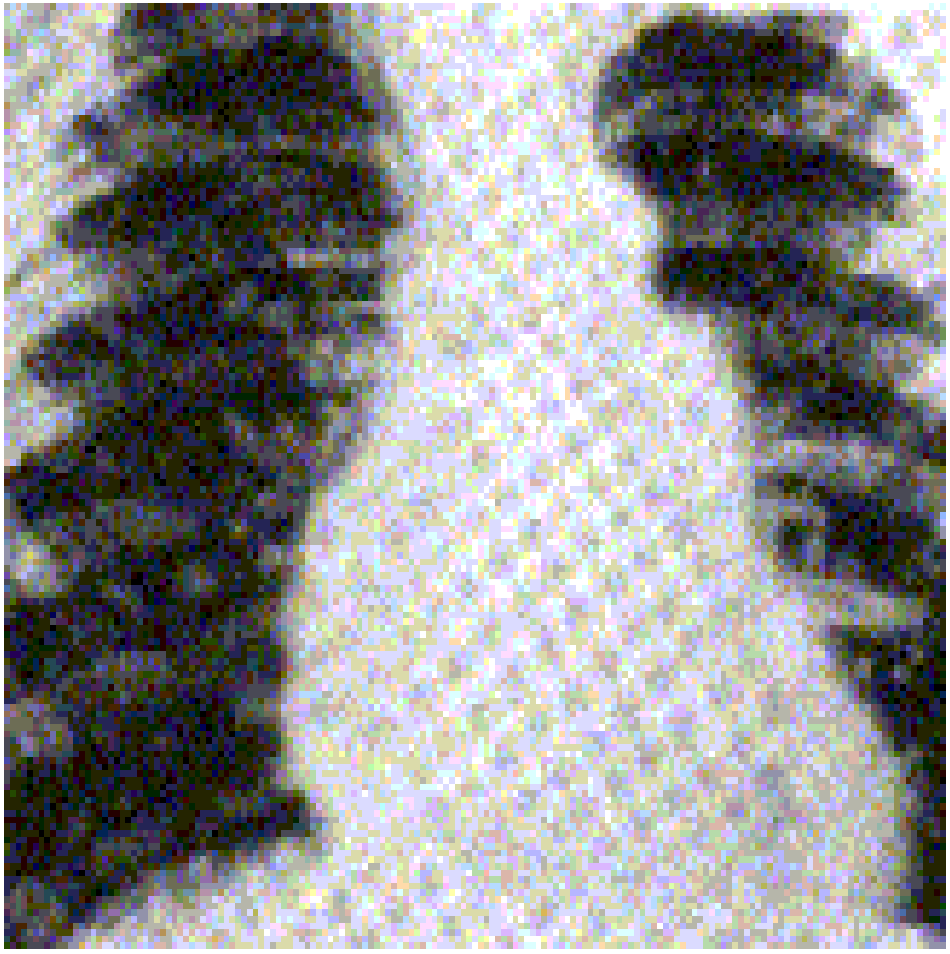

EXAMENES COMPLEMENTARIOS

- ECOCARDIOGRAMA

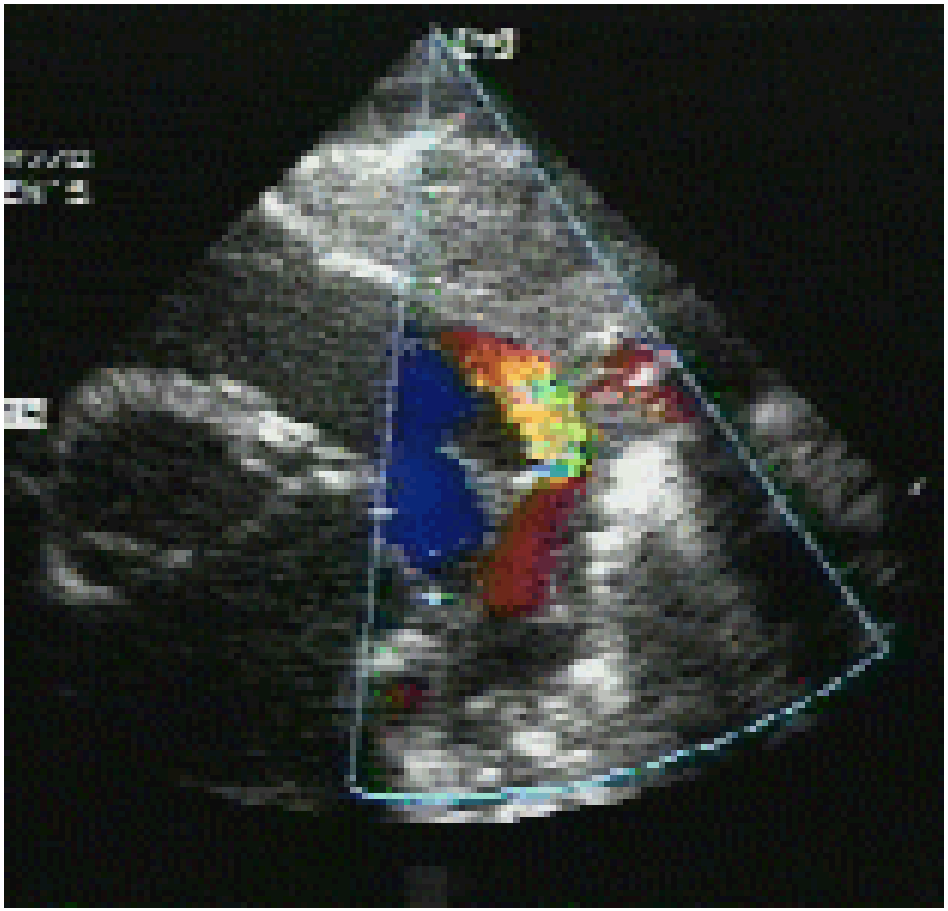

EXAMENES COMPLEMENTARIOS

- CATETERISMO

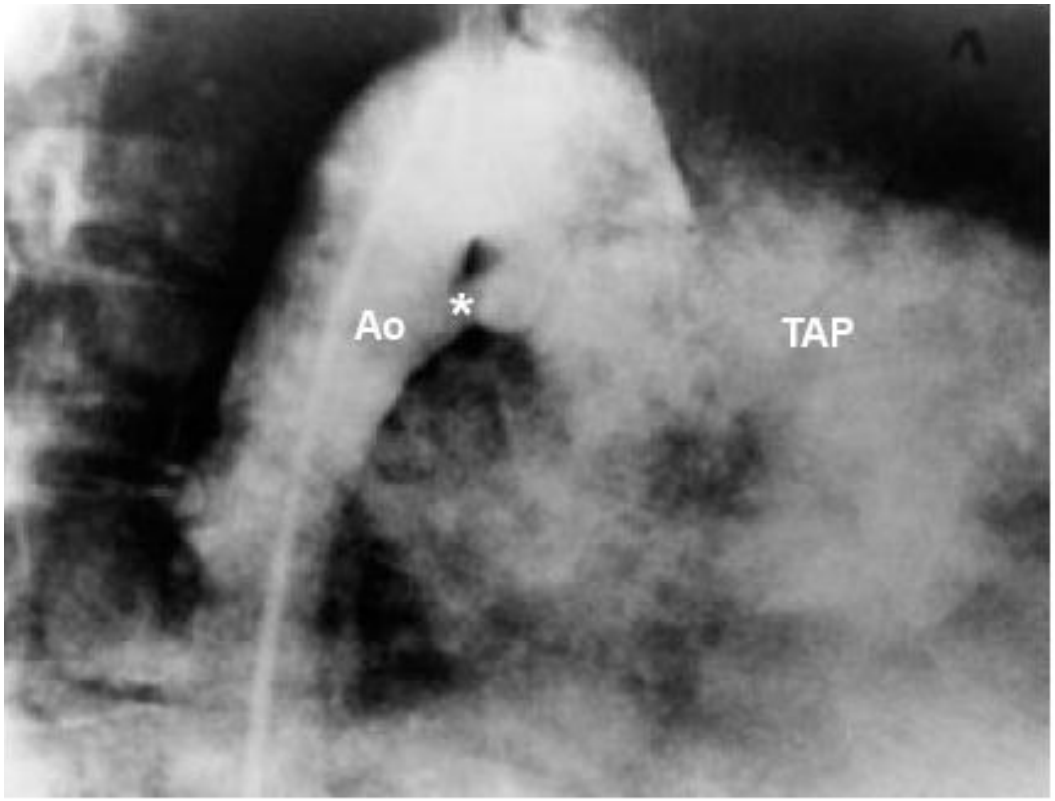

Fig. 1. Aortografía en oblicua anterior derecha donde se observa paso de contraste de la aorta (Ao) a tronco de arteria pulmonar (TAP) a través de un conducto (*).

TRATAMIENTO

- CIERRE QUIRURGICO

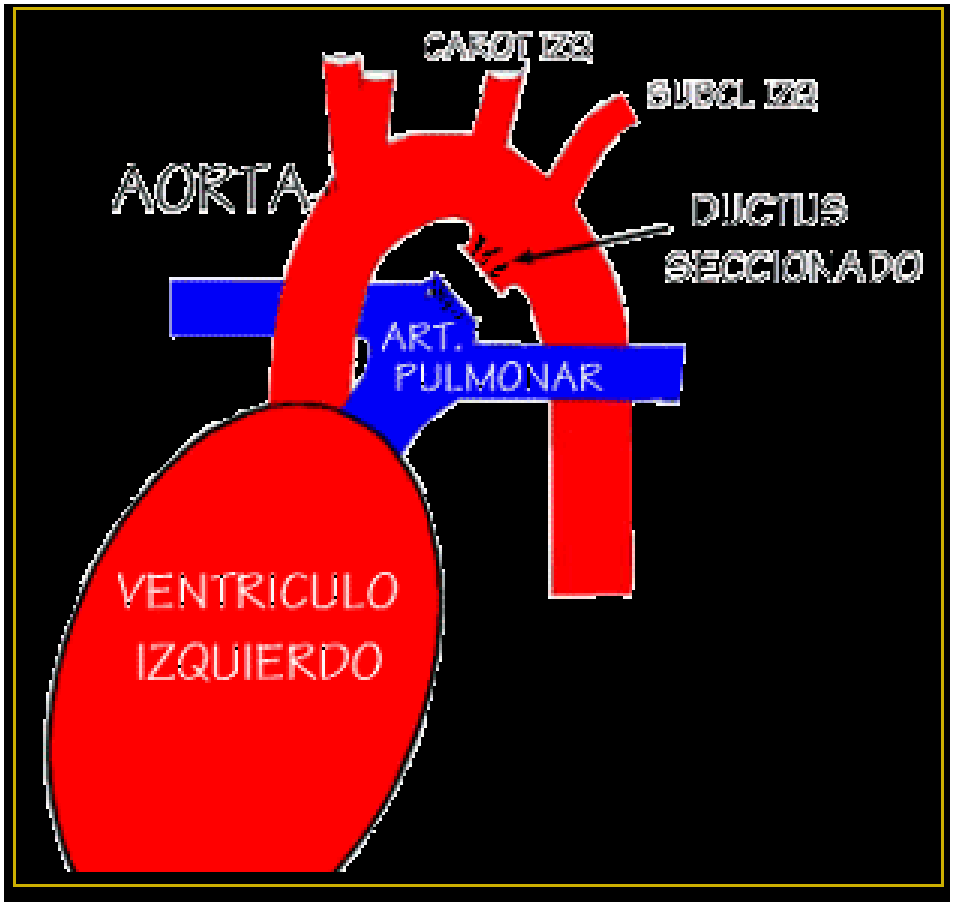

TRATAMIENTO

- CIERRE MEDIANTE DISPOSITIVO PERCUTANEO = AMPLATZER



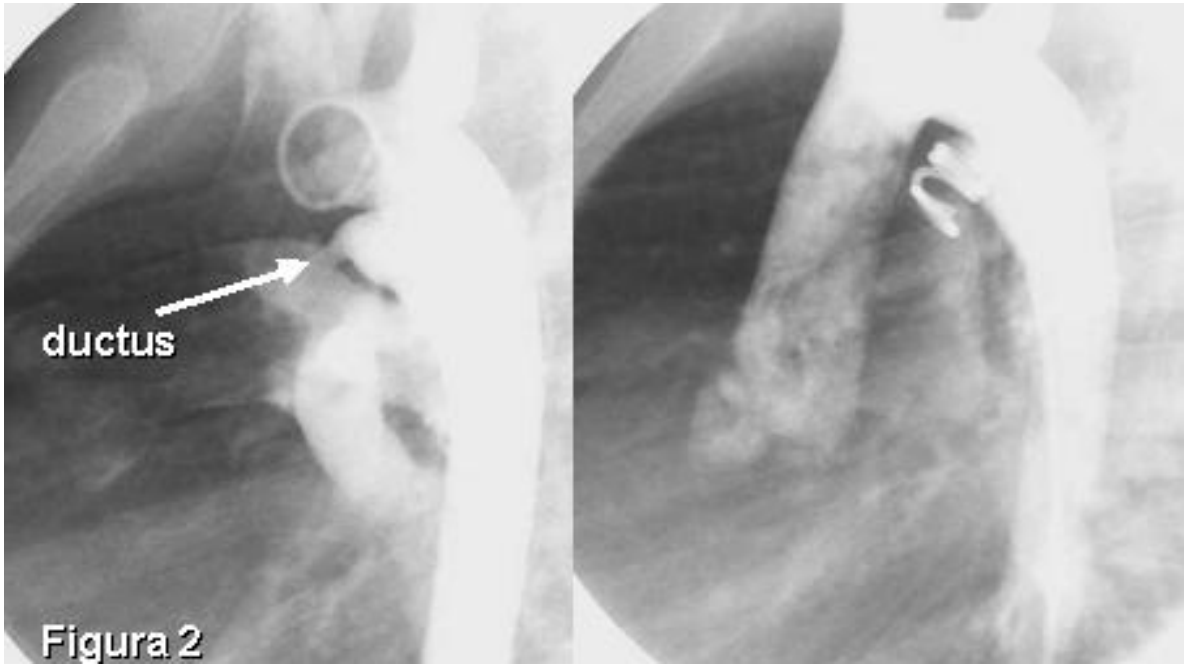

TRATAMIENTO

- CERRARSE MEDIANTE DISPOSITICO PERCUTANEO



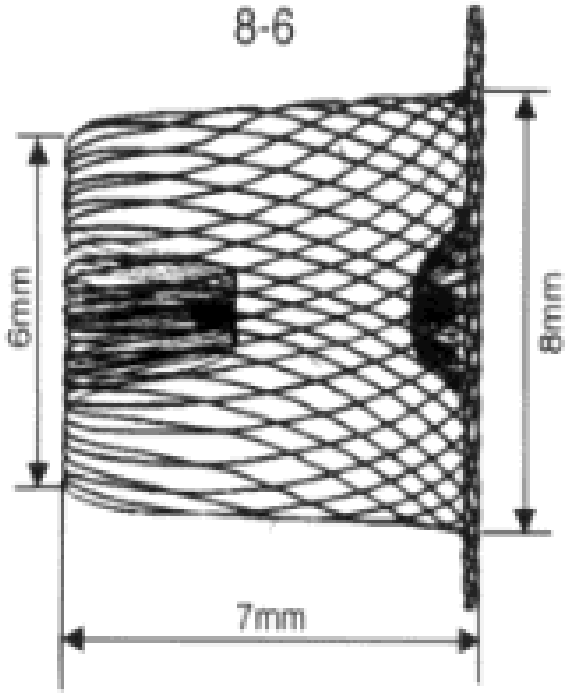

TRATAMIENTO

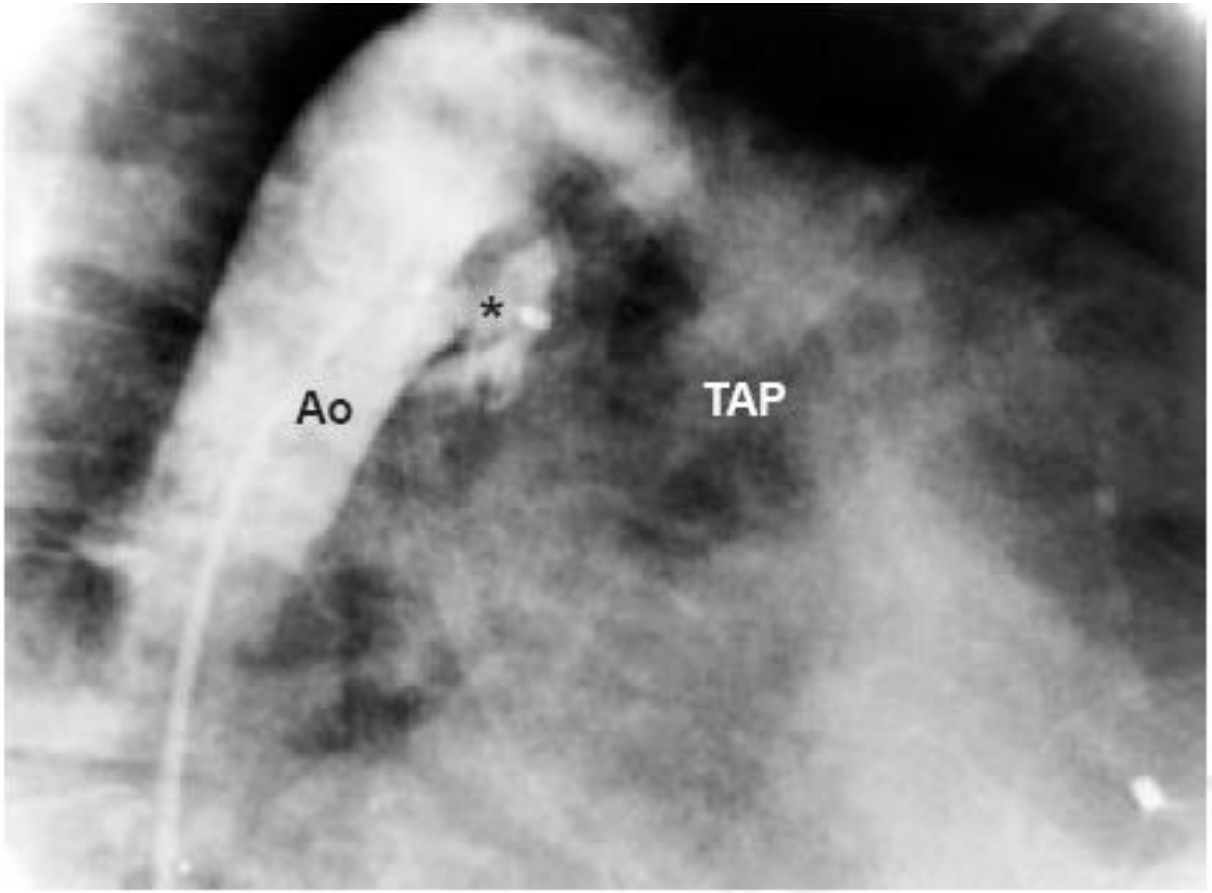

Fig. 2. Aortografía en oblicua anterior derecha con el dispositivo Amplatzer de comunicación interventricular en conducto arterioso (*). Nótese cómo el dispositivo tiene 2 discos de retención. Hay ligero paso de contraste a través del dispositivo. Aorta (Ao). Tronco arteria pulmonar (TAP).

GRACIAS

ECOCARDIOGRAFIA

DR. RAMIRO LARA R.

Ecocardiografía

Técnica que utiliza haces de ultrasonido reflejados por las estructuras cardiovasculares para producir líneas y formas características originadas por la anatomía cardiaca.

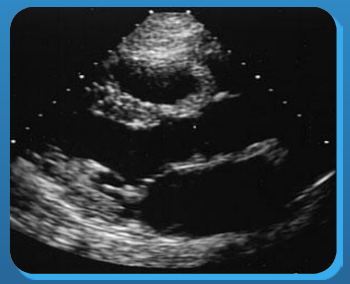



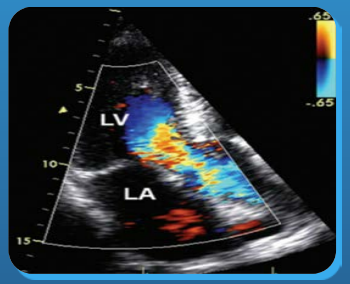

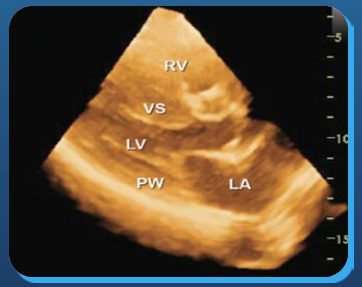

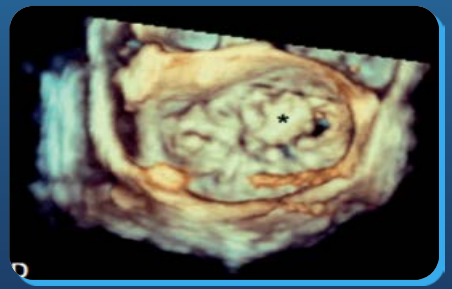

Ecocardiografía

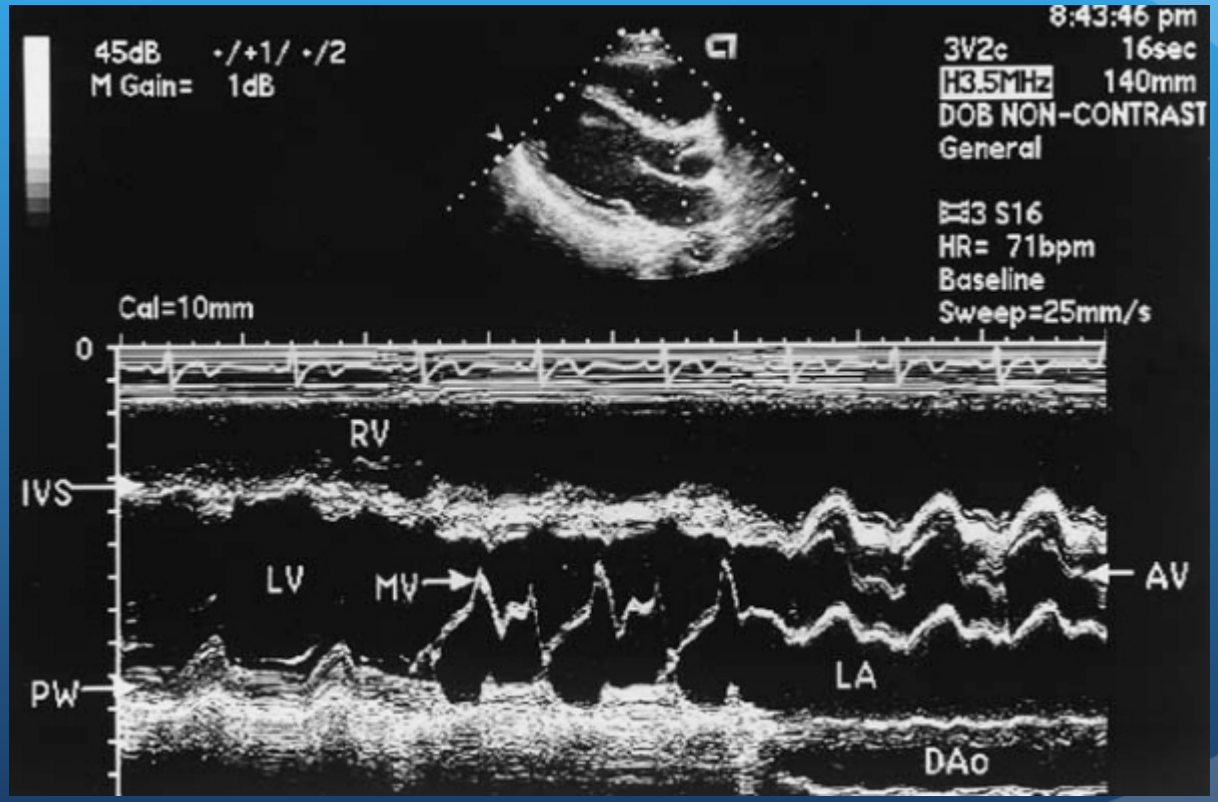

Ecocardiografía

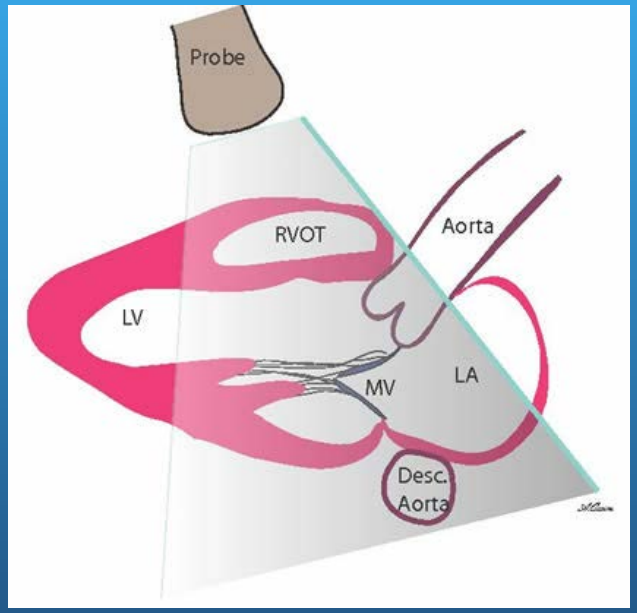

Ecocardiografía Transtorácica

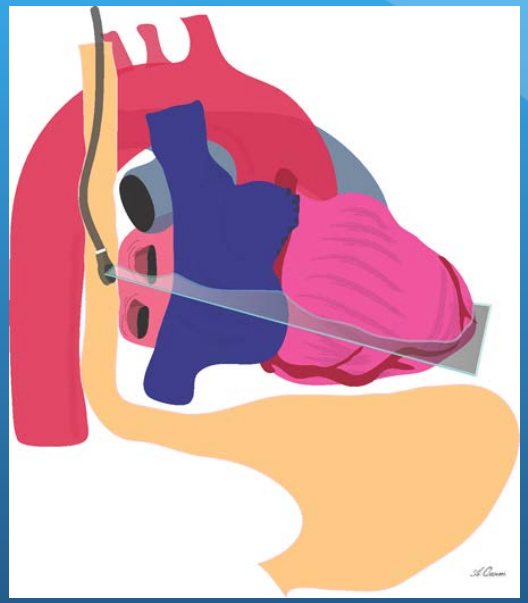

Ecocardiografía Transesofágica

Ecocardiografía Transtorácica

Modo M 2D

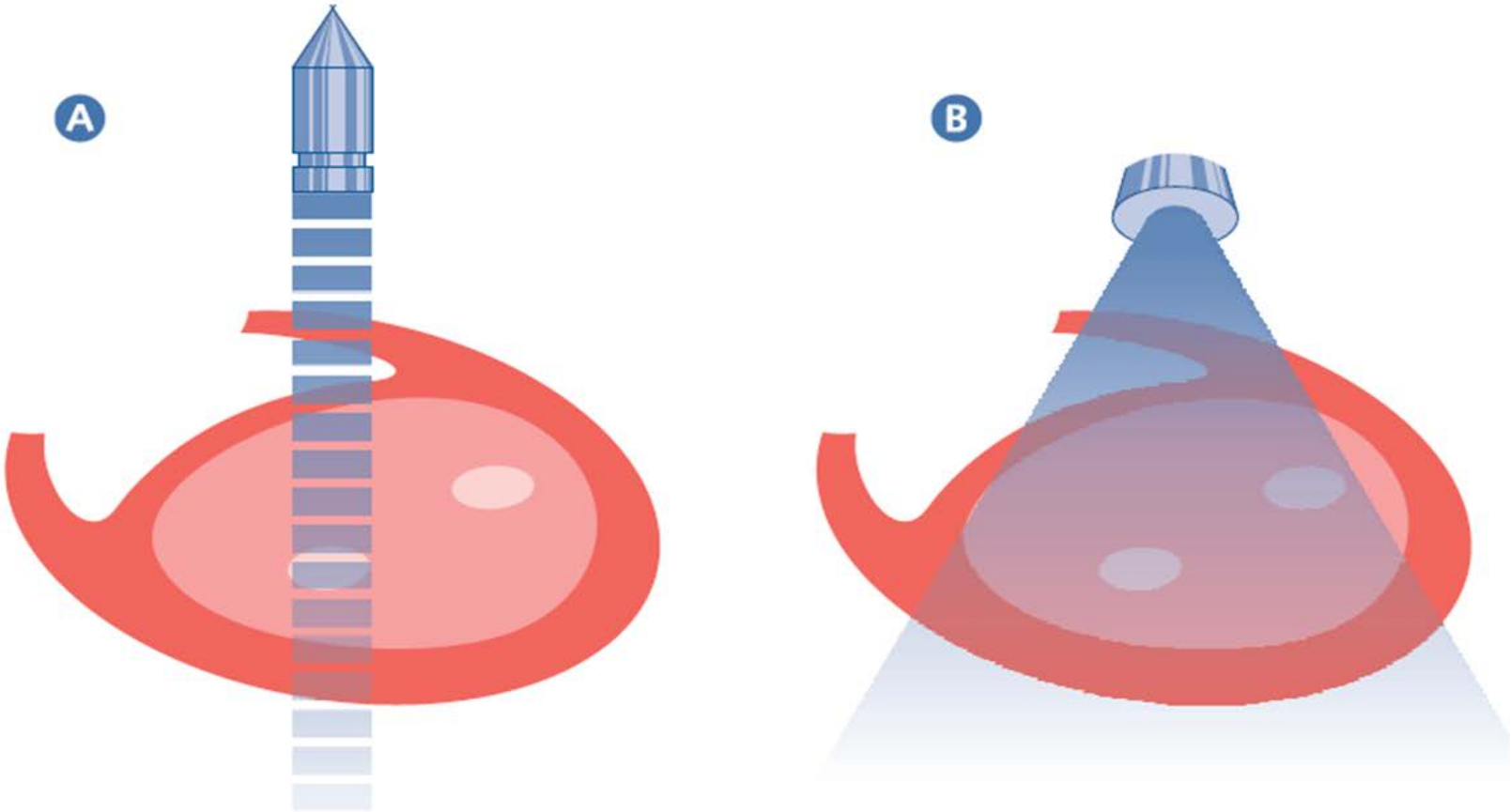

Modo M

Representa el movimiento de las estructuras cardiacas.Se usa principalmente para medir el diametro de las cavidades cardiacas y grosor de sus paredes . Así como para demostrar anomalías en el movimiento.

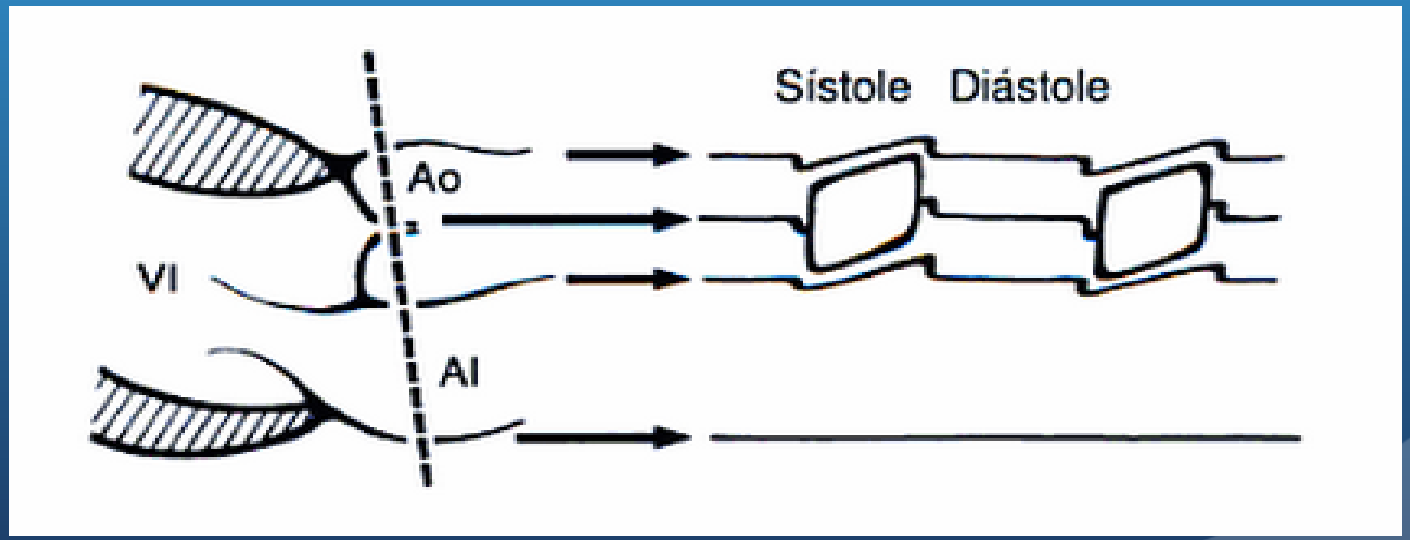

Modo M

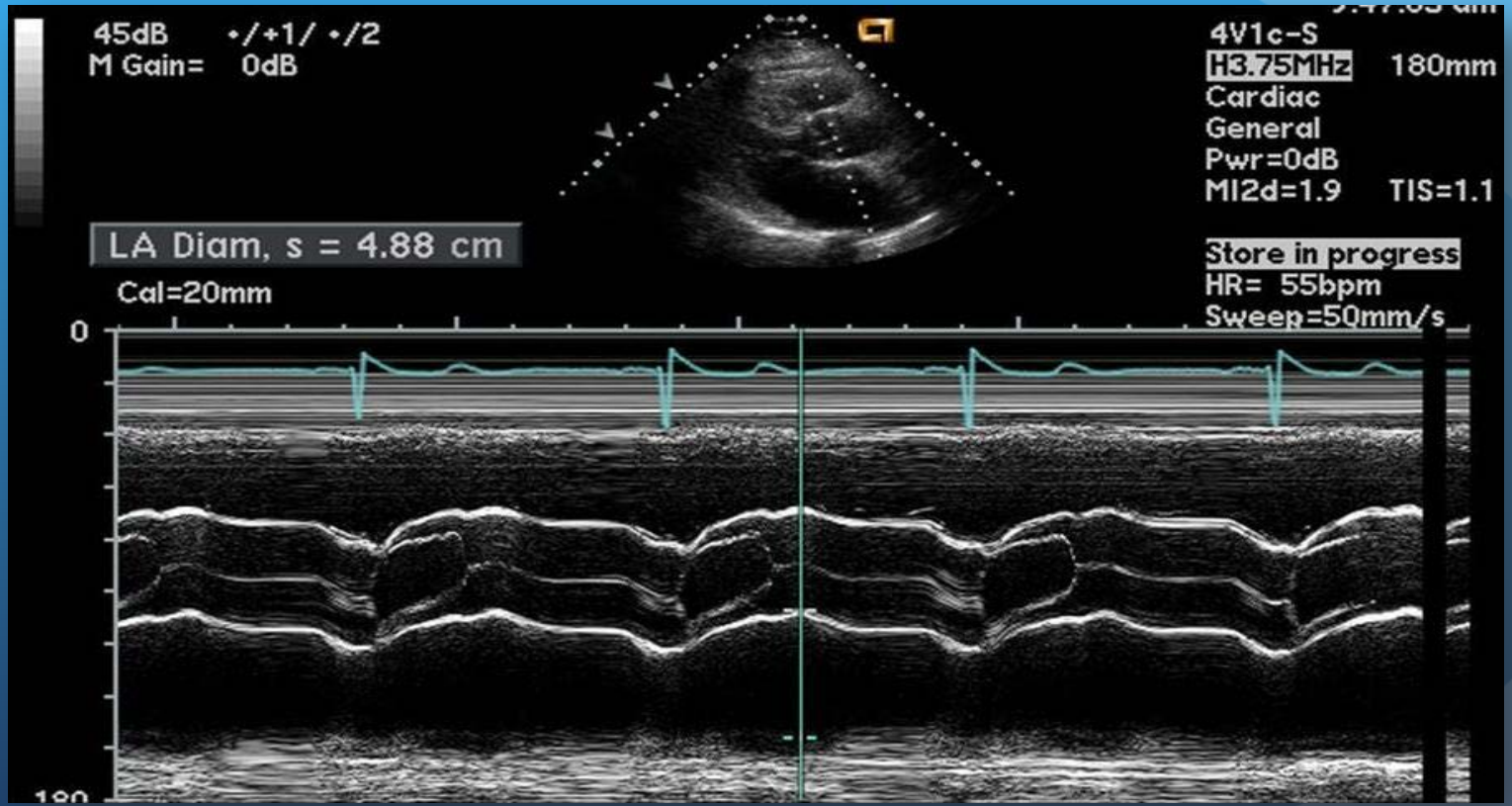
45dB
M Gain= 0dB
4V1c-S
H3.75MHz
180mm
Cardiac
General
Pwr=0dB
MI2d=1.9
TIS=1.1
LA Diam, s = 4.88 cm
Cal=20mm
Store in progress
HR= 55bpm
Sweep=50mm/s
0

Modo M

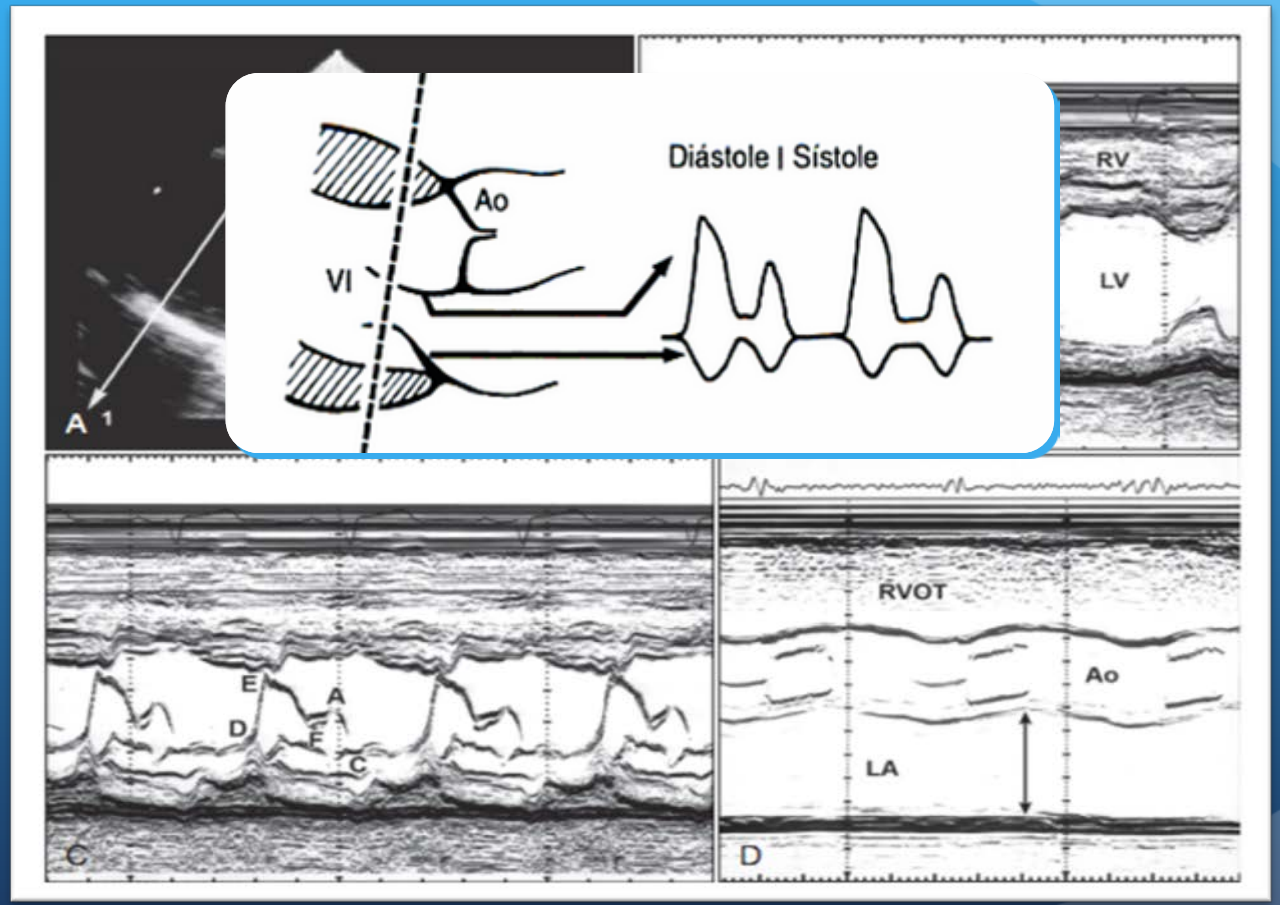

Modo M

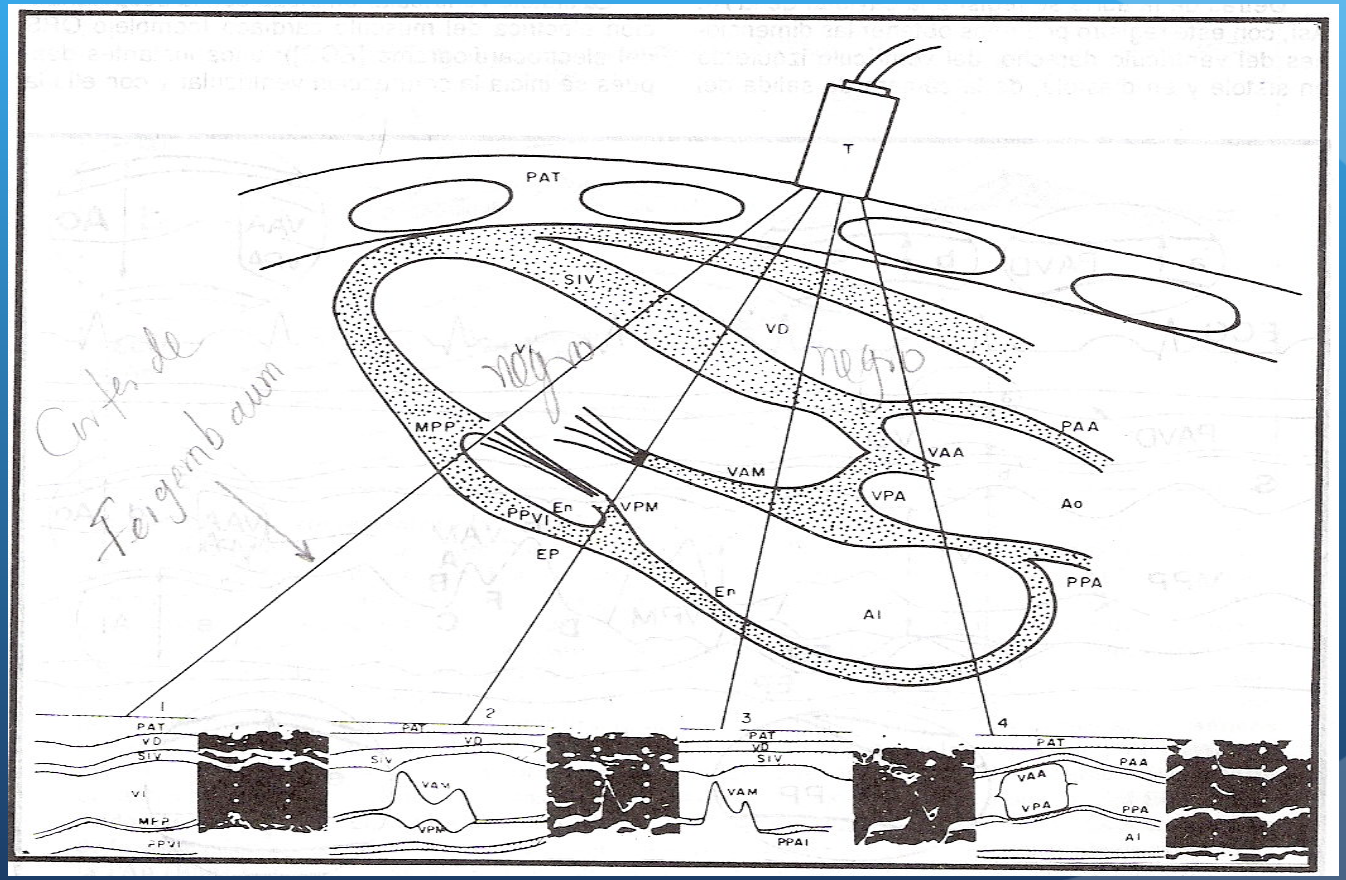
T
PAT
SIV
VD
VI
MPP
PPVI
En
VPM
EP
VAM
VAA
VPA
PAA
Ao
PPA
AI
1
2
3
4
PAT
VD
SIV
VI
MPP
PPVI
VAM
VPM
PPAI
VAA
VPA
PAA
PPA
AI

Ecocardiograma 2D

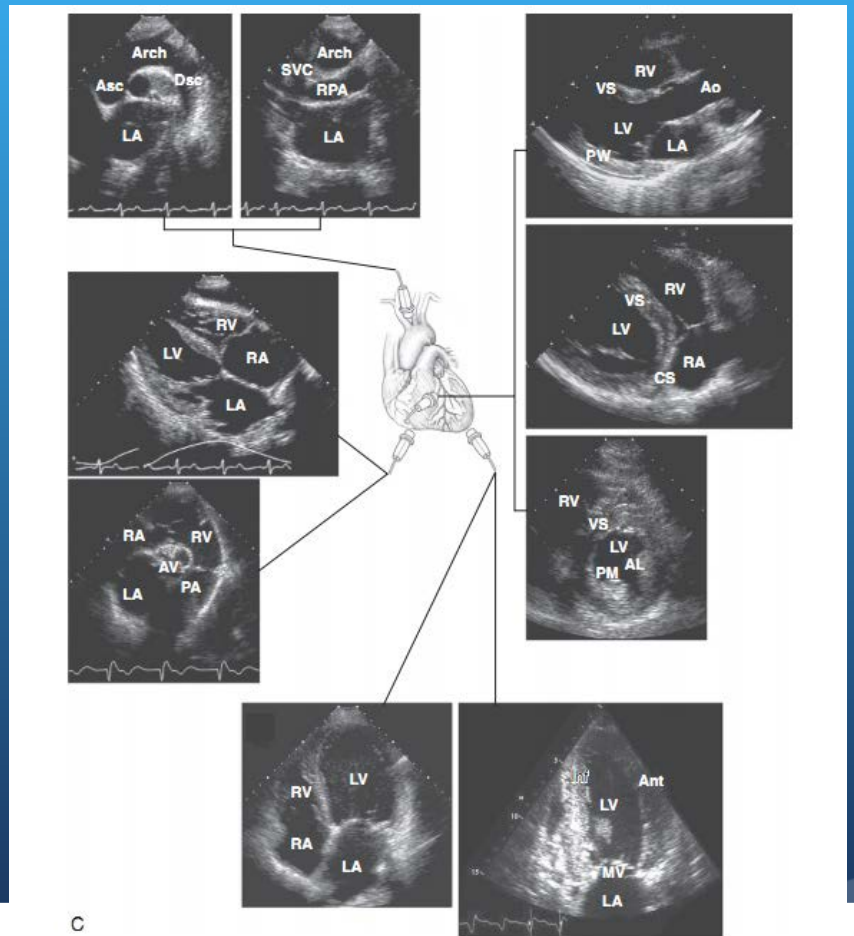

Ecocardiograma 2D

Posiciones del transductor.

- Paraesternal
- Apical
- Subcostal
- Supraesternal

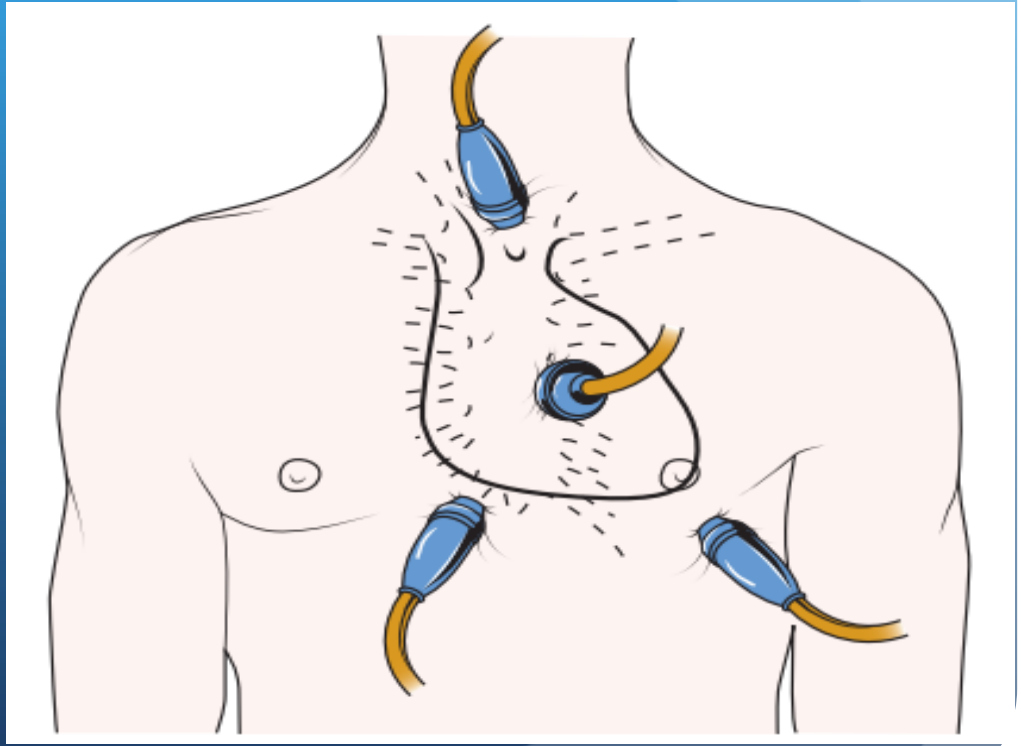

Ecocardiograma 2D

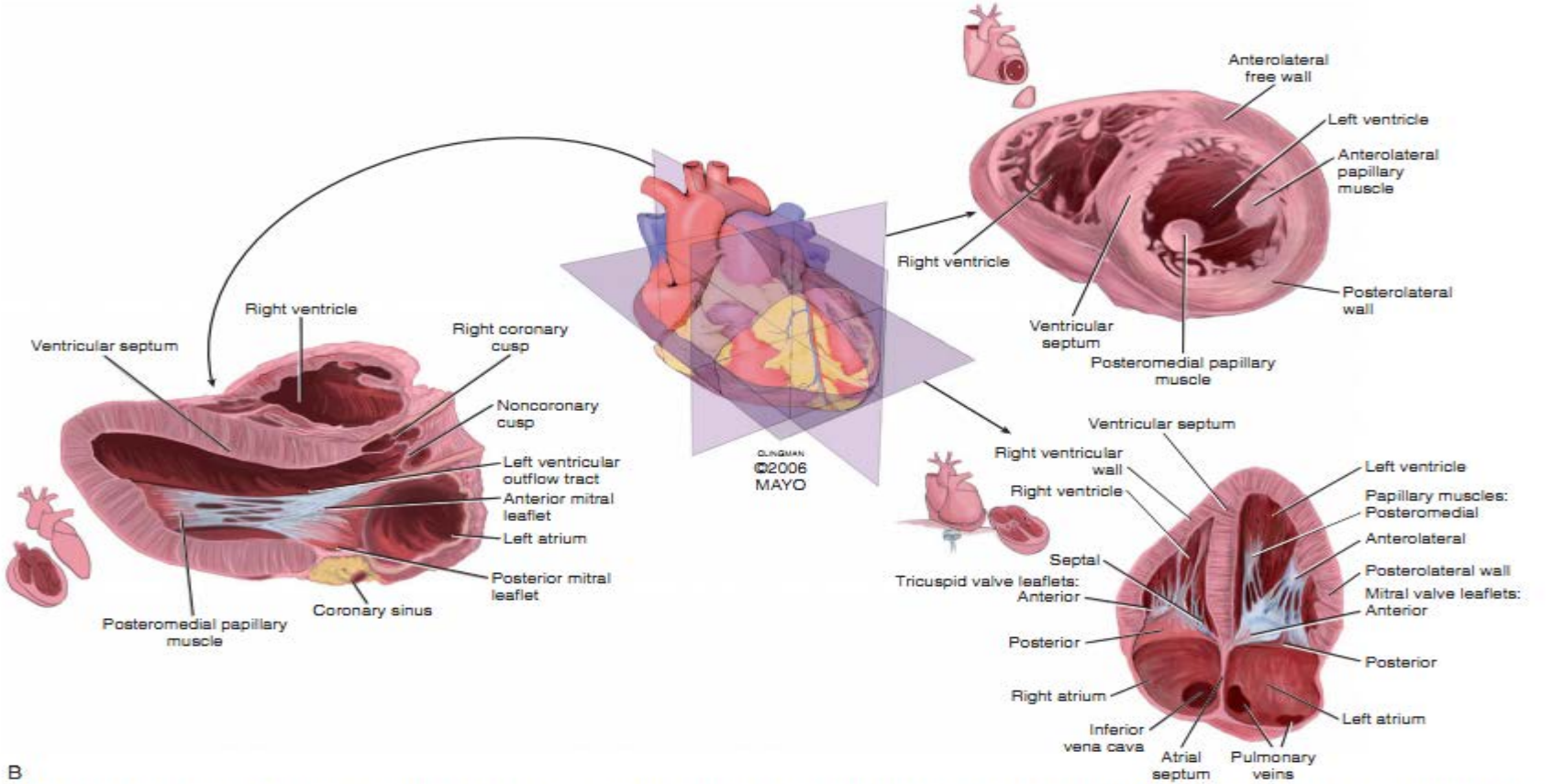

FIGURE 15-1, cont'd **B,** Diagram of cardiac structures from standard tomographic planes: parasternal long-axis view **(left),** parasternal short-axis view **(upper right),** and apical four-chamber view **(lower right).**

Ecocardiograma 2D

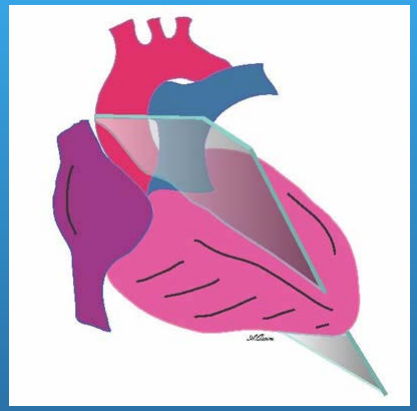

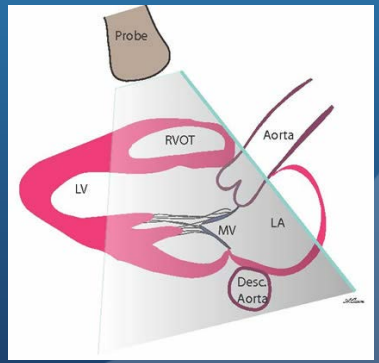

Paraesternal – Eje Largo

Ecocardiograma 2D

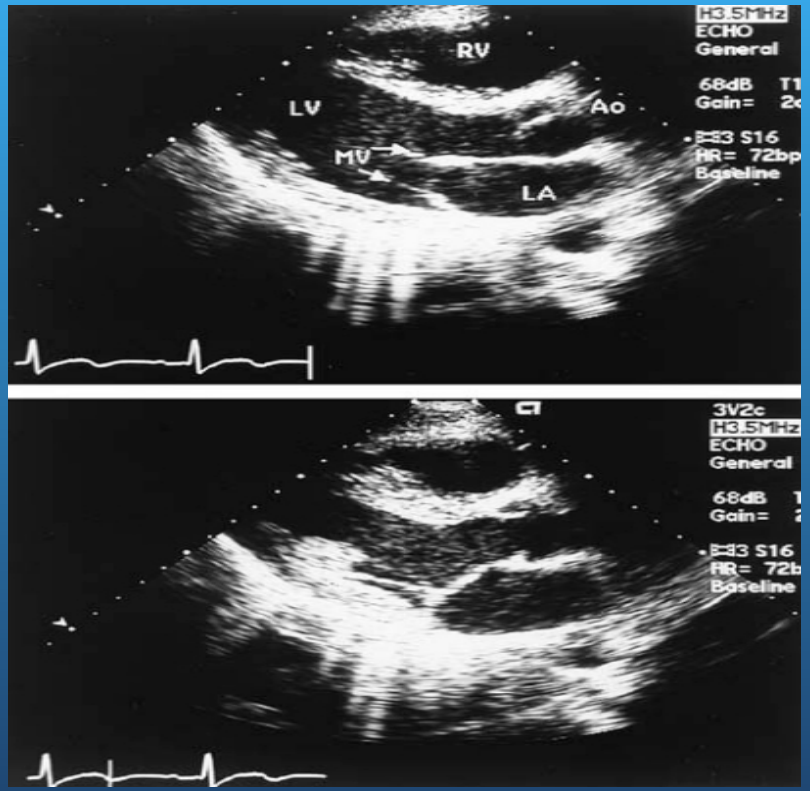

Paraesternal – Eje Largo

Ecocardiograma 2D

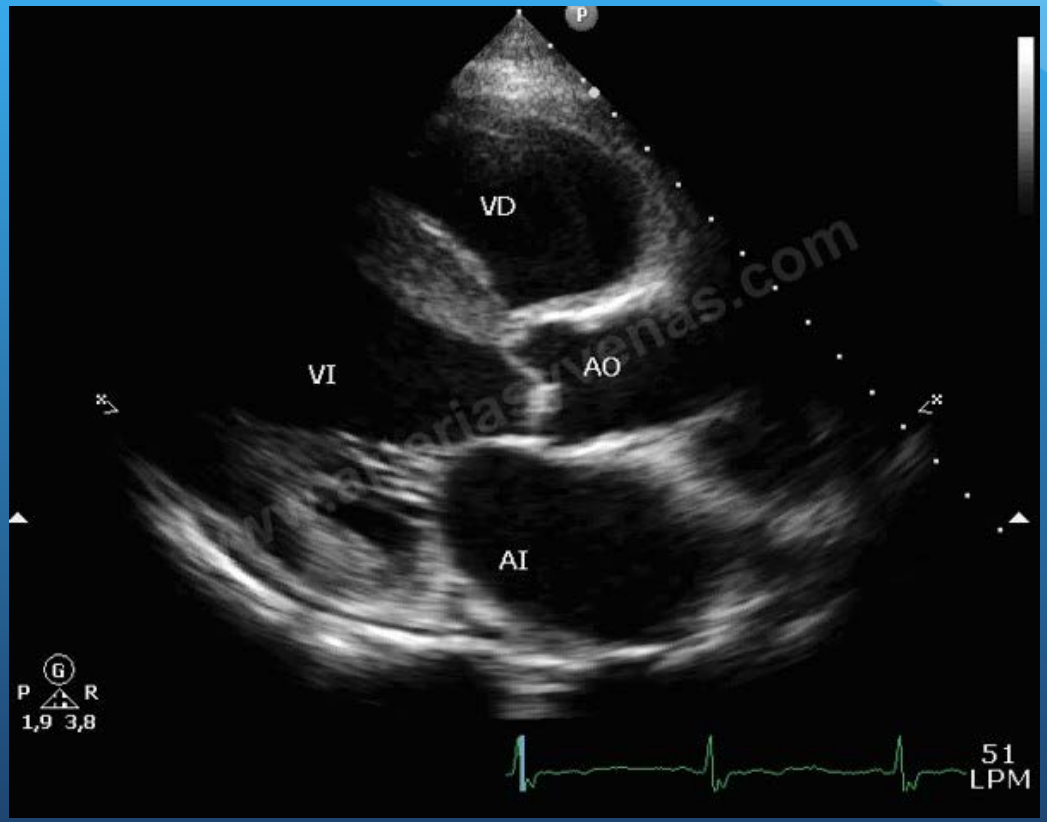

Paraesternal – Eje Largo

Ecocardiograma 2D

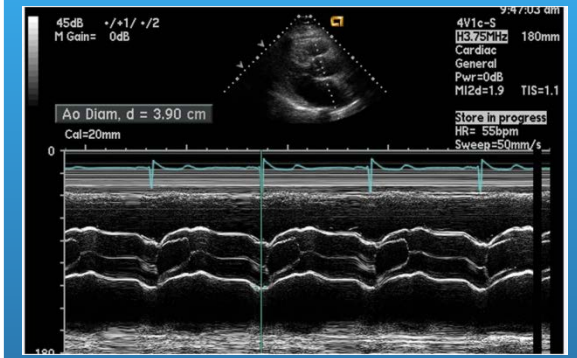

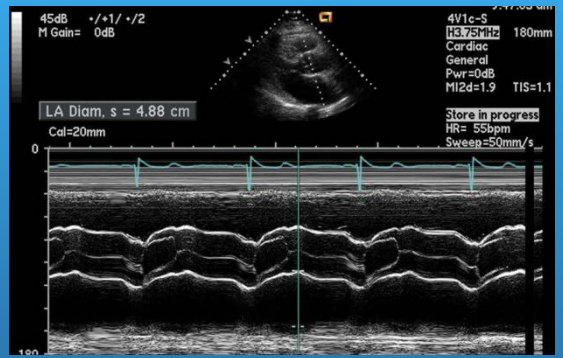

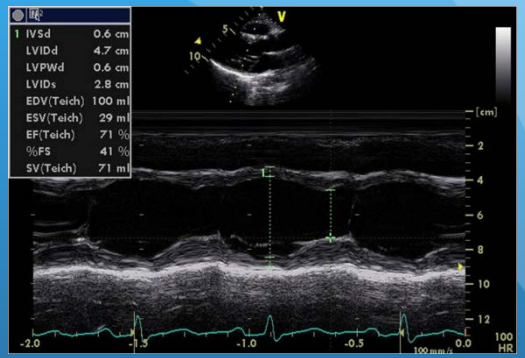

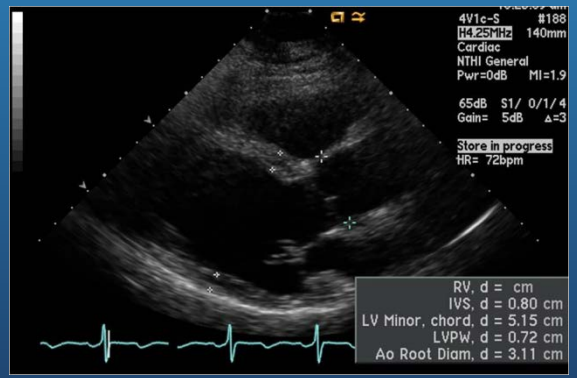

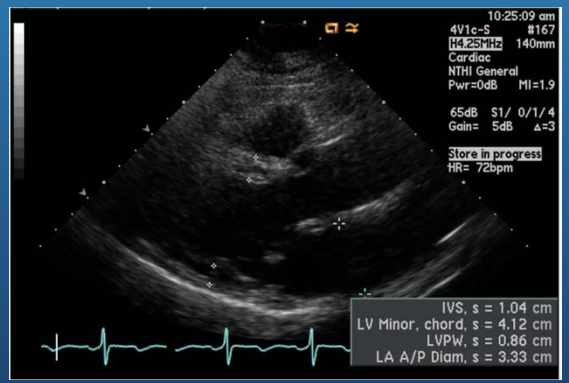

Paraesternal – Eje Largo

Ecocardiograma 2D

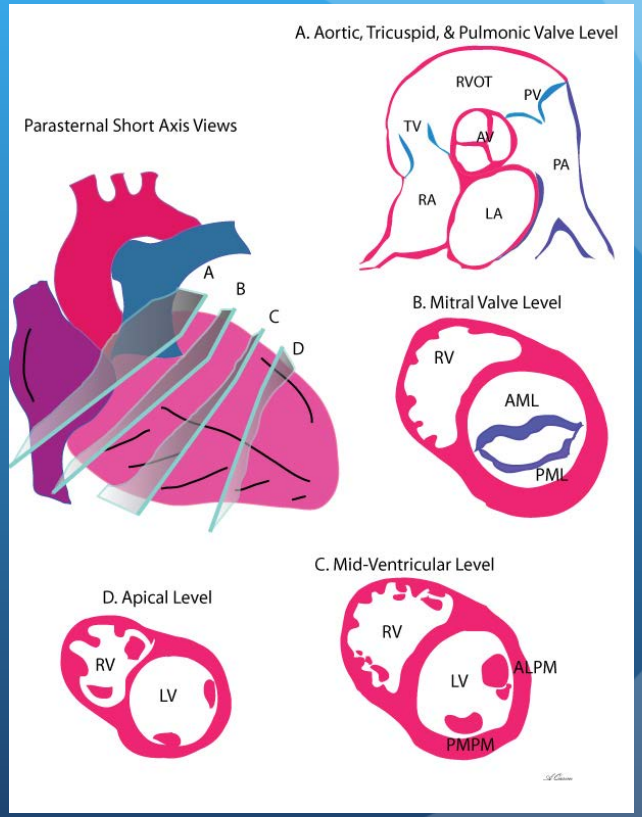

Paraesternal – Eje Corto

Ecocardiograma 2D

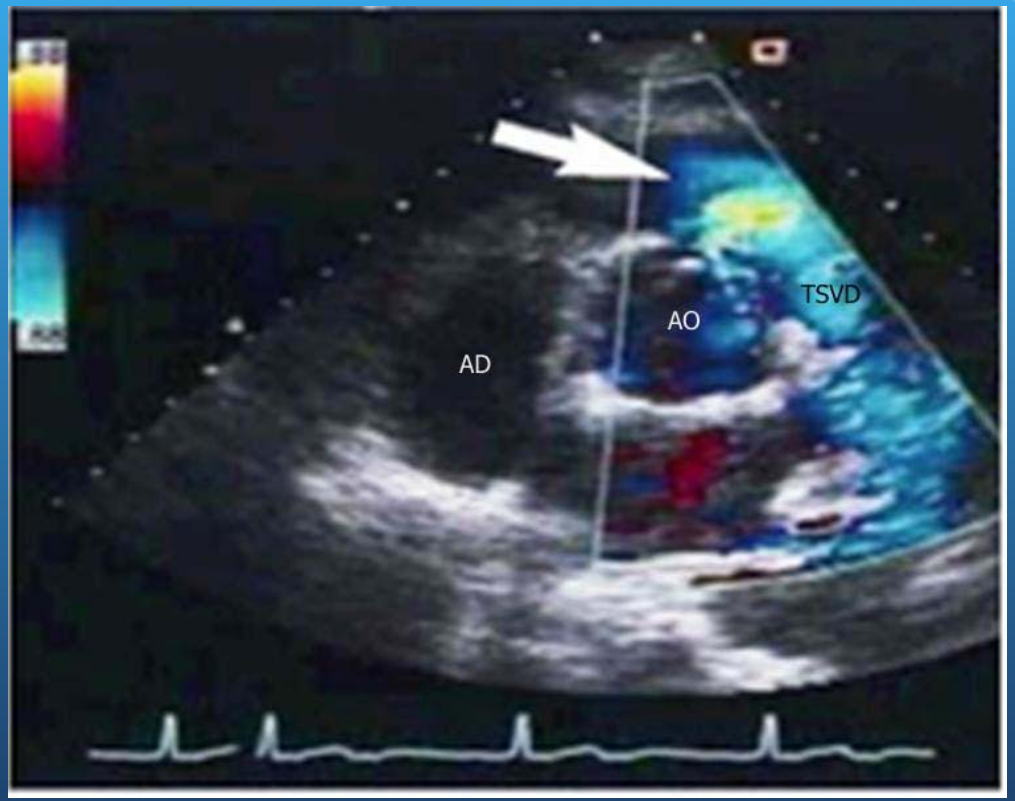

Paraesternal – Eje Corto

Ecocardiograma 2D

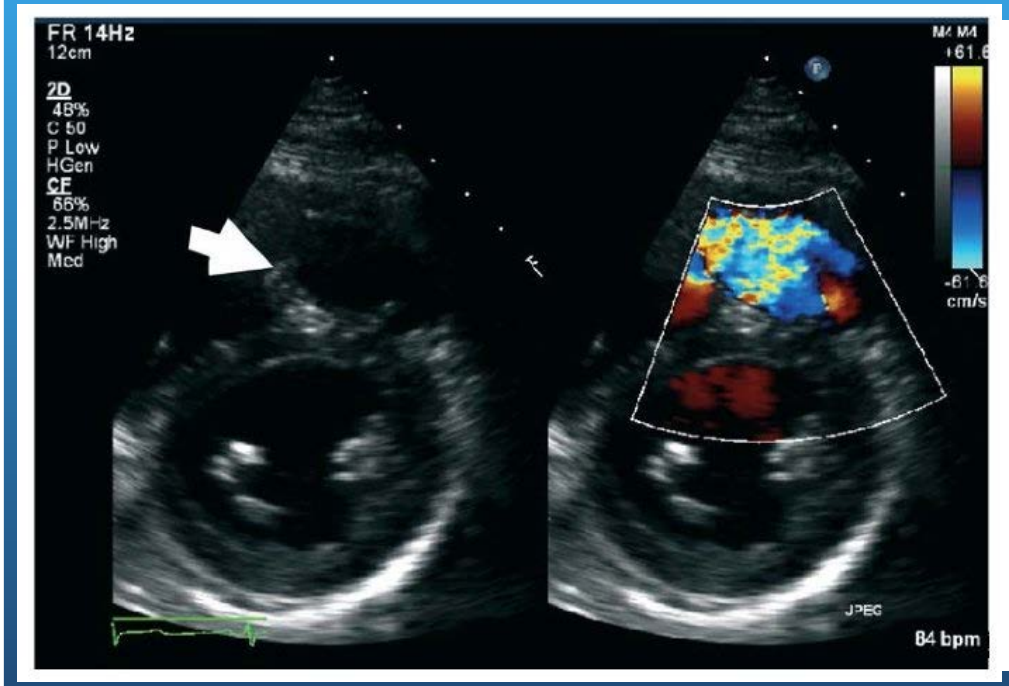

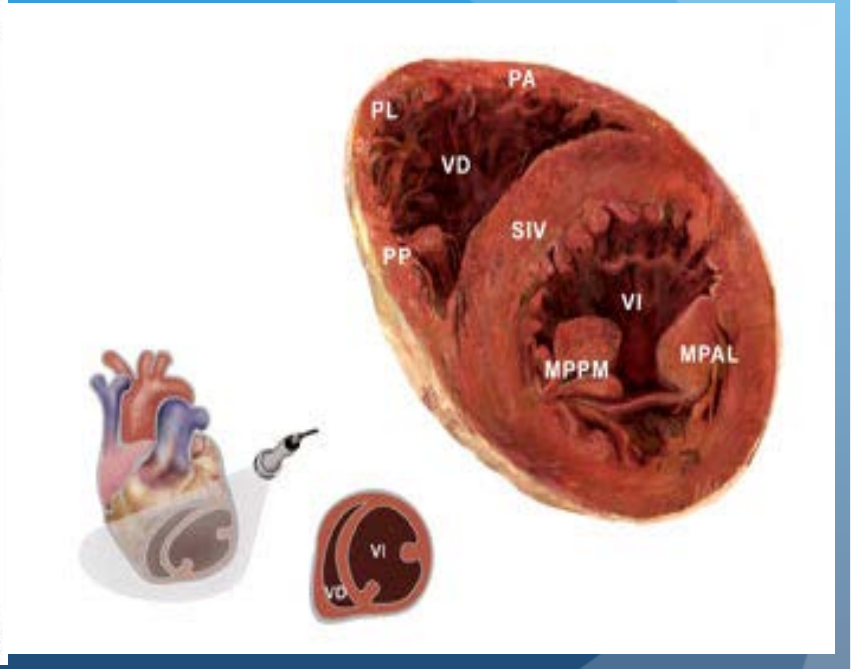

Paraesternal – Eje Corto

Ecocardiograma 2D

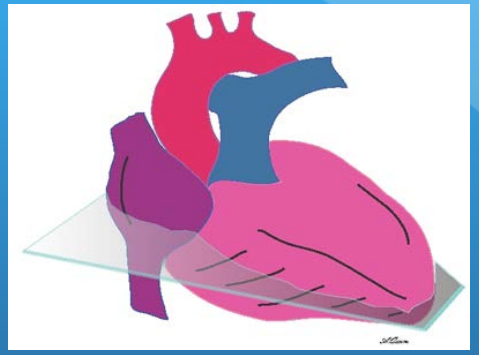

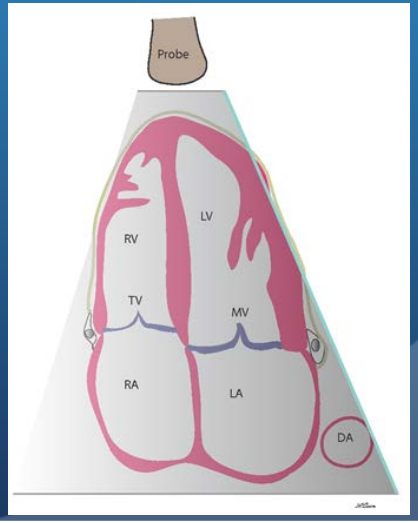

Apical – 4 Cámaras

Ecocardiograma 2D

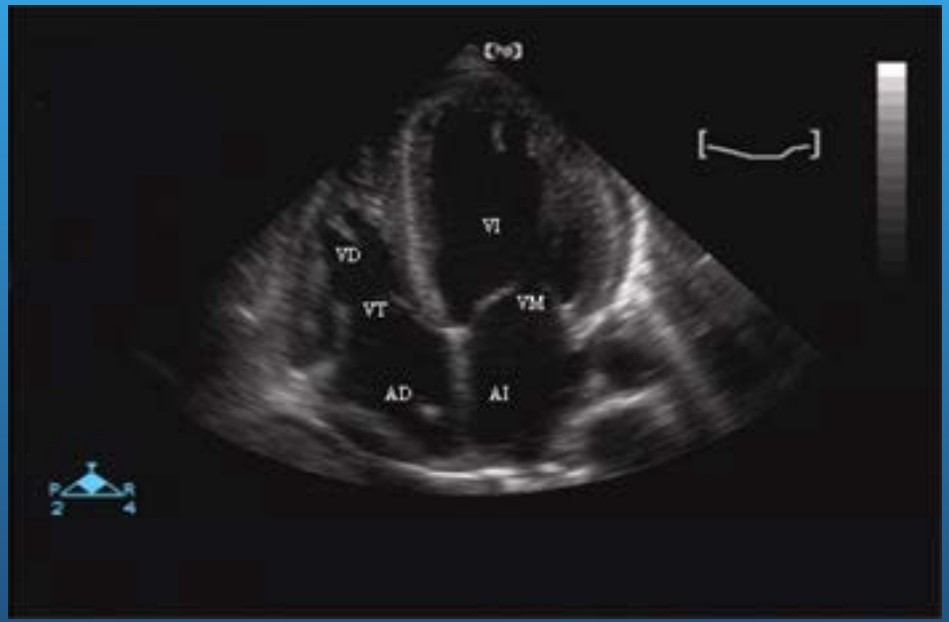

Apical – 4 Cámaras

Ecocardiograma 2D

Posición apical

Proyección del eje largo apical normal

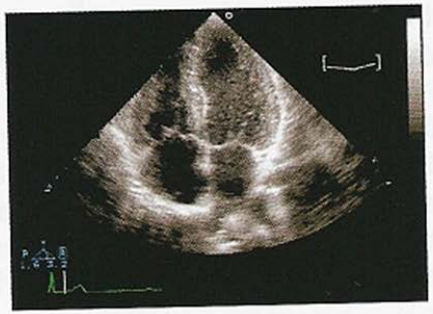

Proyección tetracameral apical normal

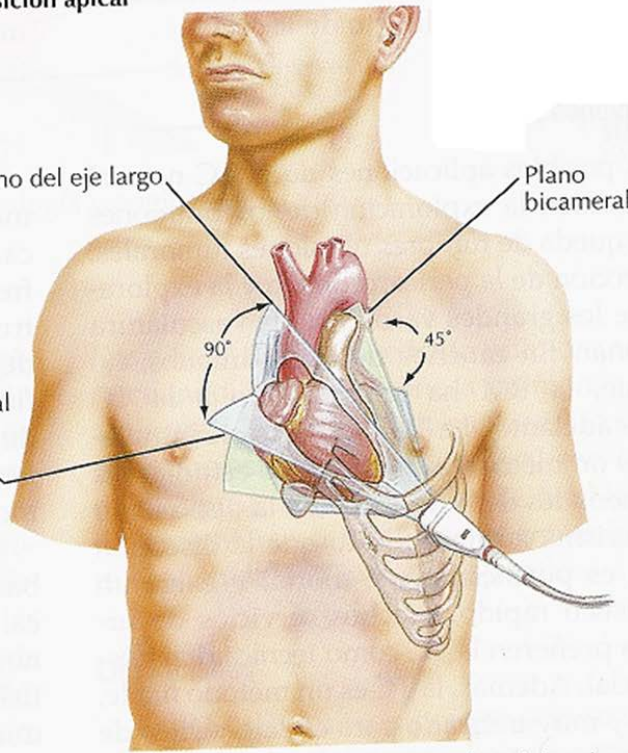

Estudios apicales obtenidos desde el punto de máximo impulso hacia la base. El plano tetracameral atraviesa las válvulas auriculoventriculares; la inclinación hacia arriba proporciona el plano pentacameral. La rotación de 45° en sentido contrario al de las agujas del reloj proporciona el plano bicameral. La rotación de 90° proporciona el plano del eje largo

Ecocardiograma 2D

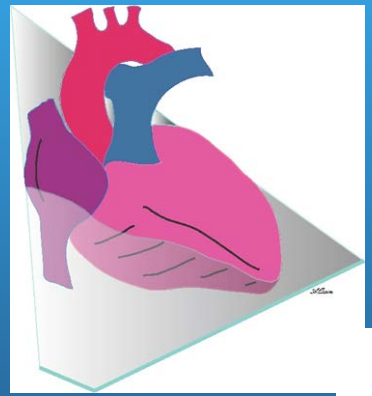

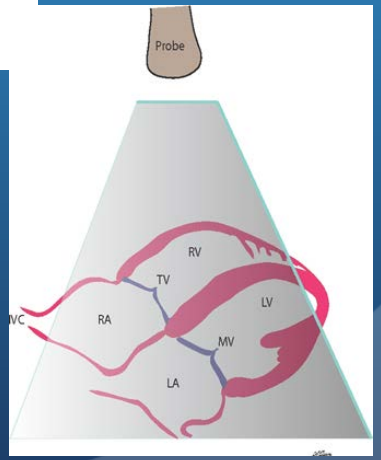

Subcostal

Ecocardiograma 2D

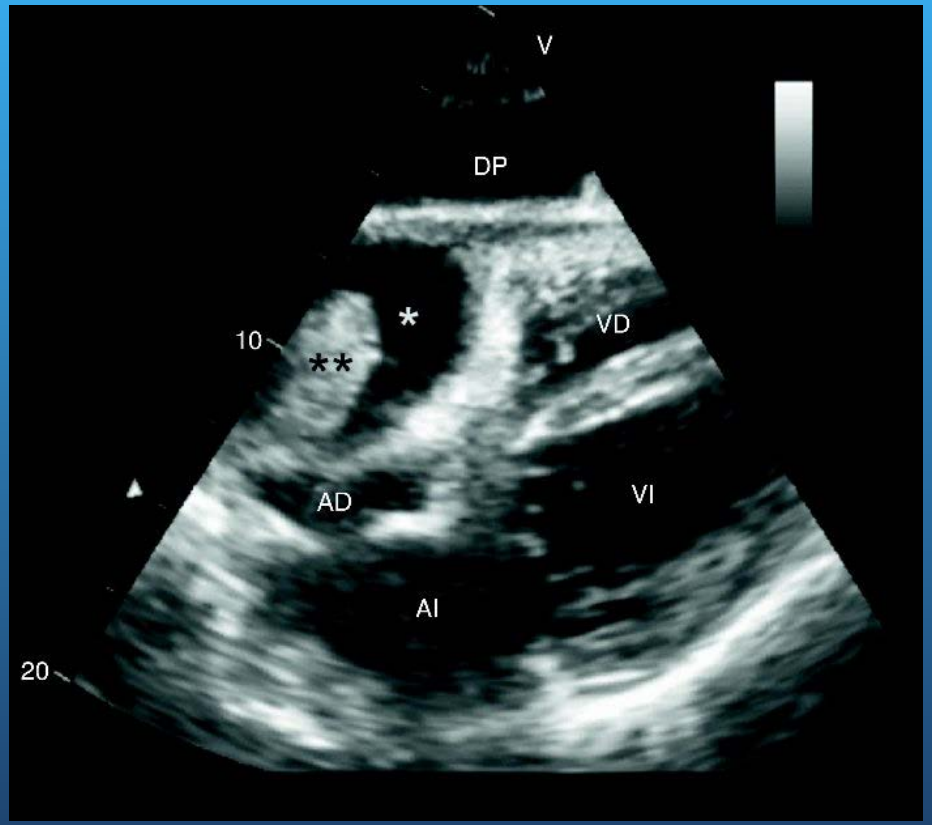

Subcostal

Ecocardiograma 2D

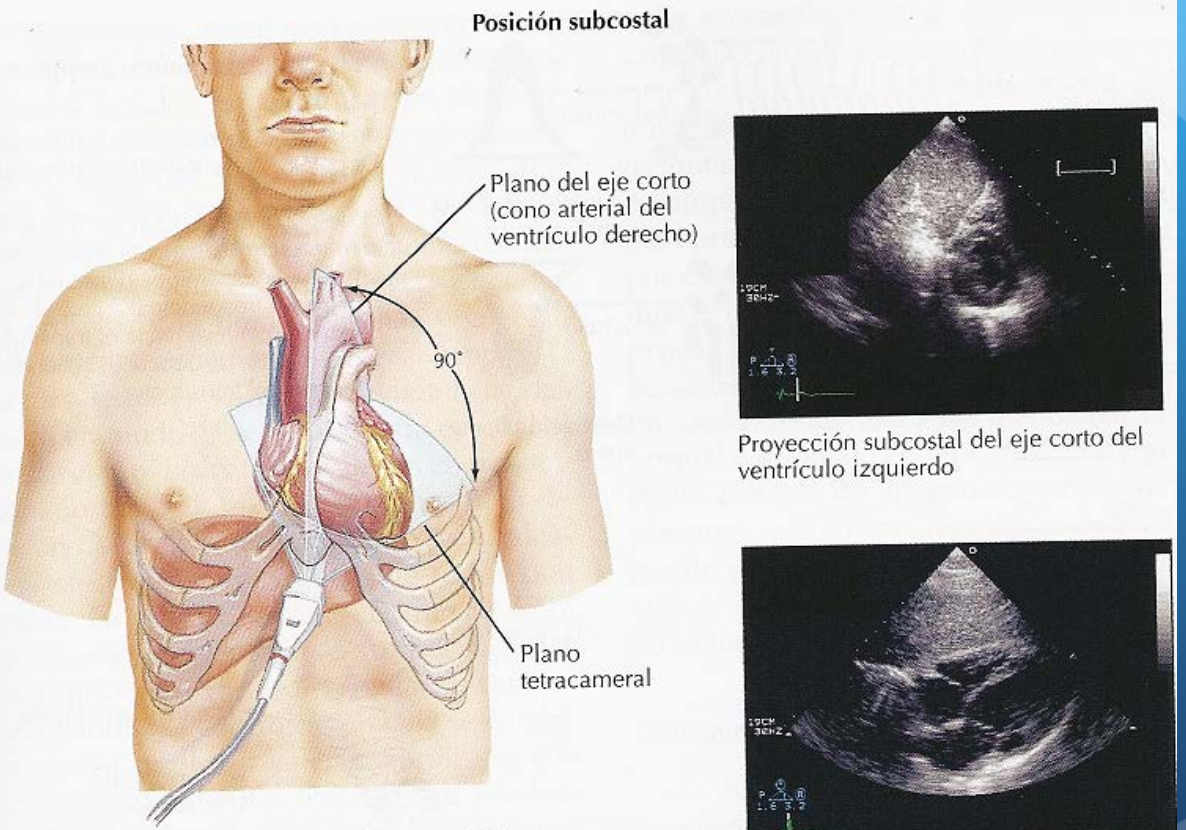

La posición subcostal permite obtener múltiples proyecciones del eje corto; la rotación de 90° proporciona la proyección tetracameral

Proyección subcostal del eje corto del ventrículo izquierdo

Proyección subcostal tetracameral

Ecocardiograma 2D

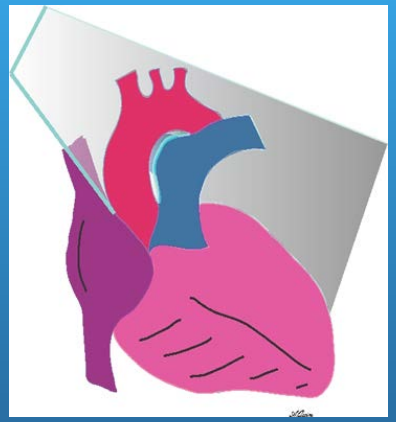

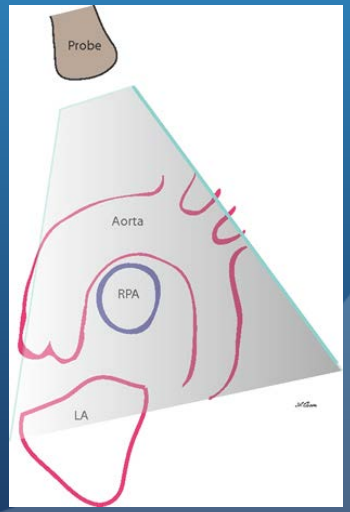

Supraesternal

Ecocardiograma 2D

Supraesternal

Ecocardiograma 2D

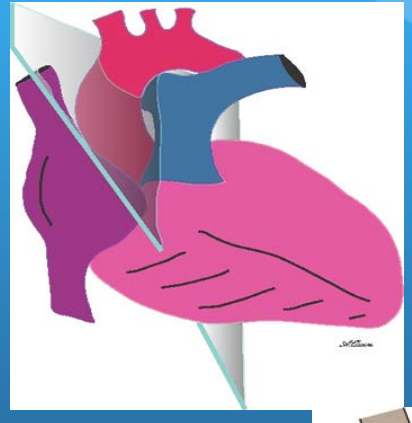

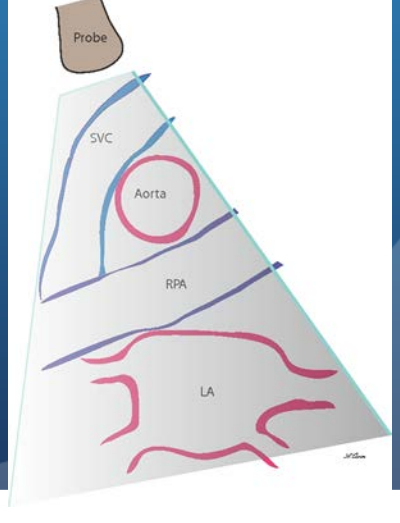

Supraesternal

Ecocardiograma 2D

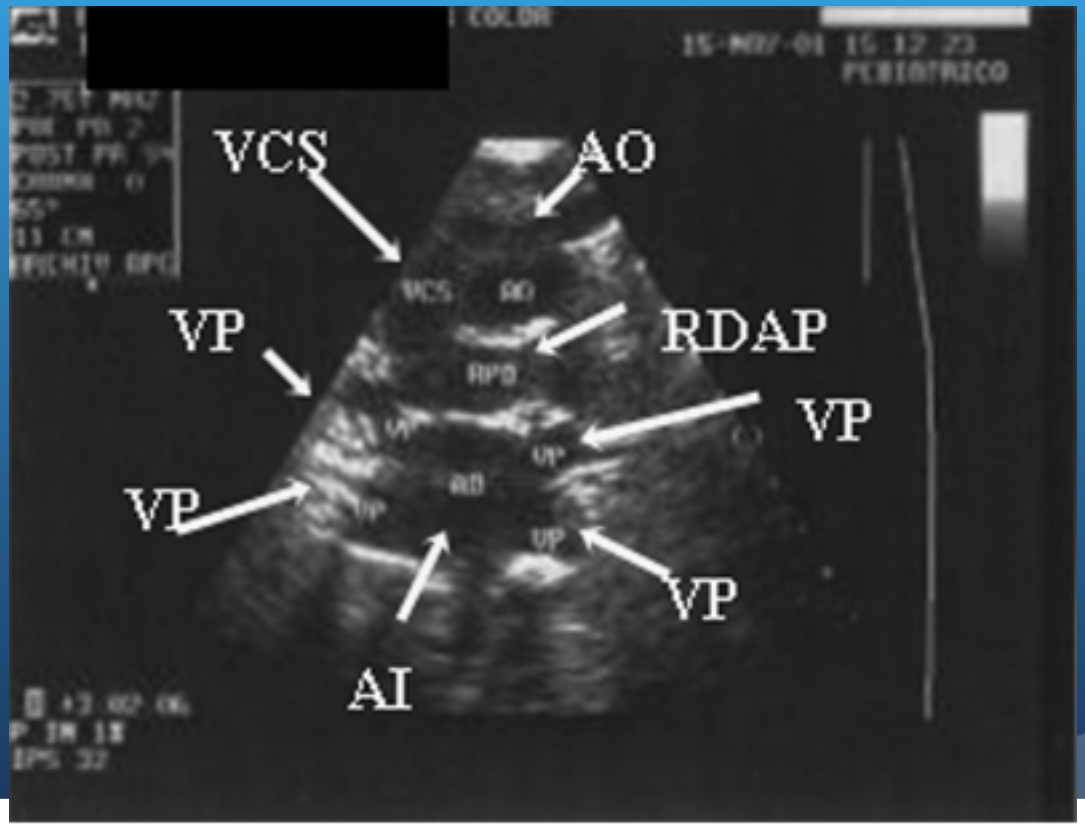

Ecocardiografía Doppler

Efecto Doppler.- El cambio en la frecuencia de la onda, atribuible al movimiento relativo de la fuente y el objeto.

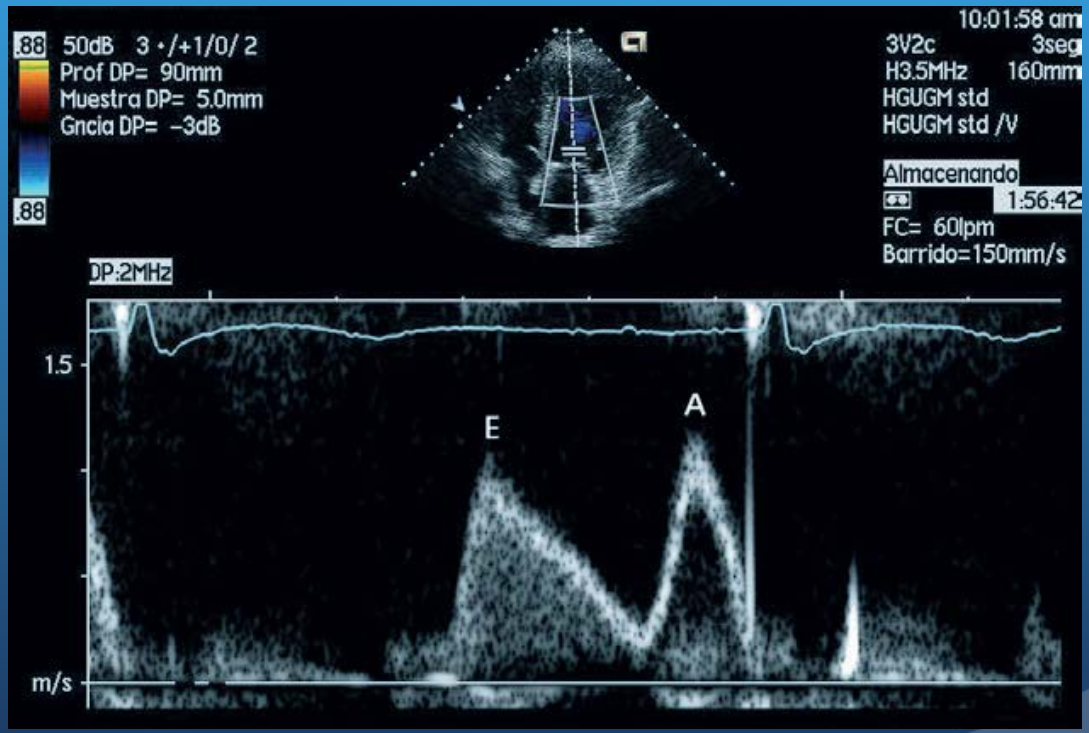

Doppler Color

El Doppler Color codifica la dirección del flujo en 2 colores:

Rojo: Para los que se acercan al transductor

Azul: Para los que se alejan

Además informa sobre velocidades altas con tonos más brillantes por lo que un rojo más intenso, anaranjado o amarillo indican mayor velocidad de flujo

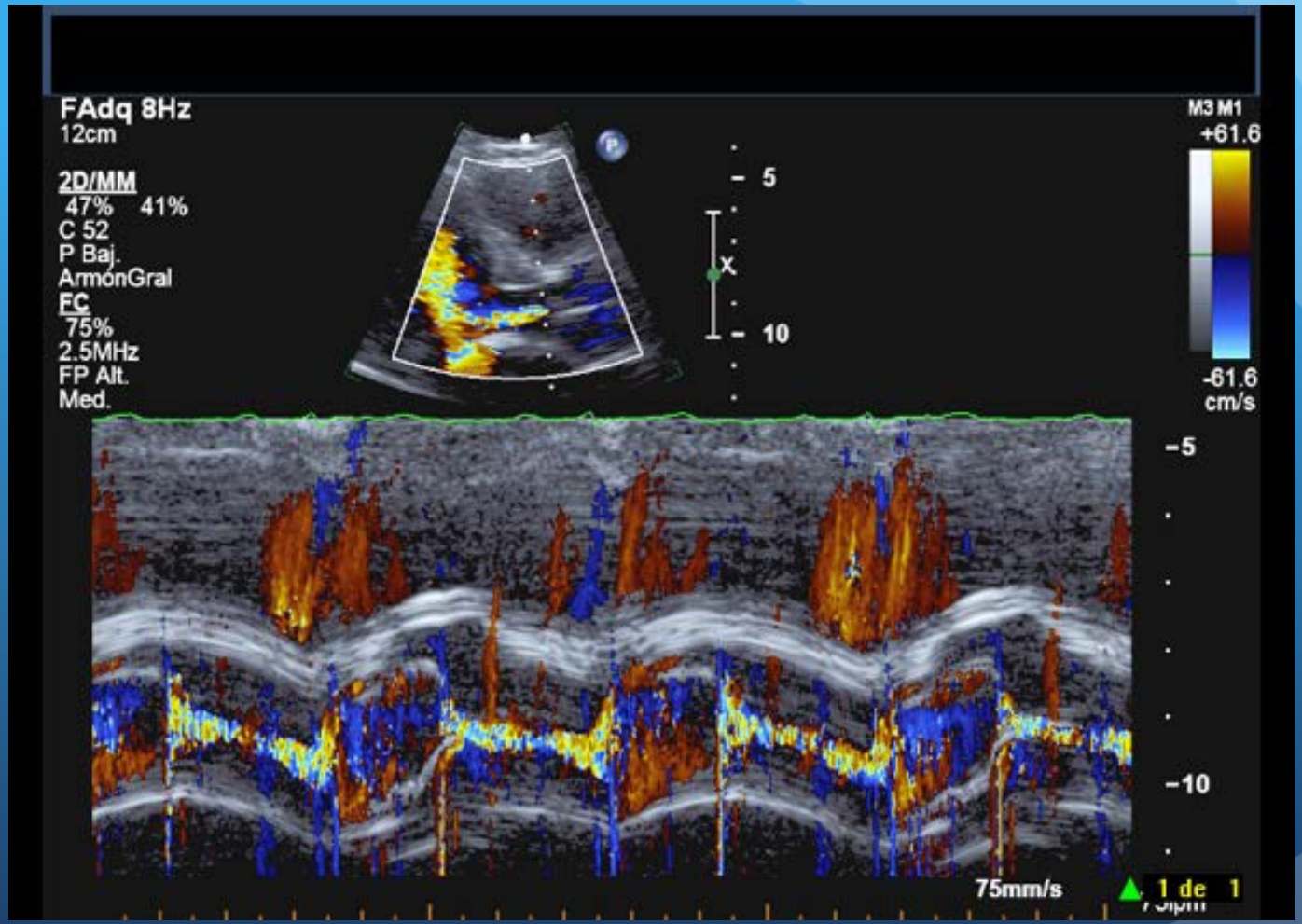
FAdq 8Hz
12cm
2D/MM
47% 41%
C 52
P Baj.
ArmonGral
FC
75%
2.5MHz
FP Alt.
Med.
5
10
M3 M1
+61.6
-61.6
cm/s
-5
-10
75mm/s
1 de 1

Doppler Color

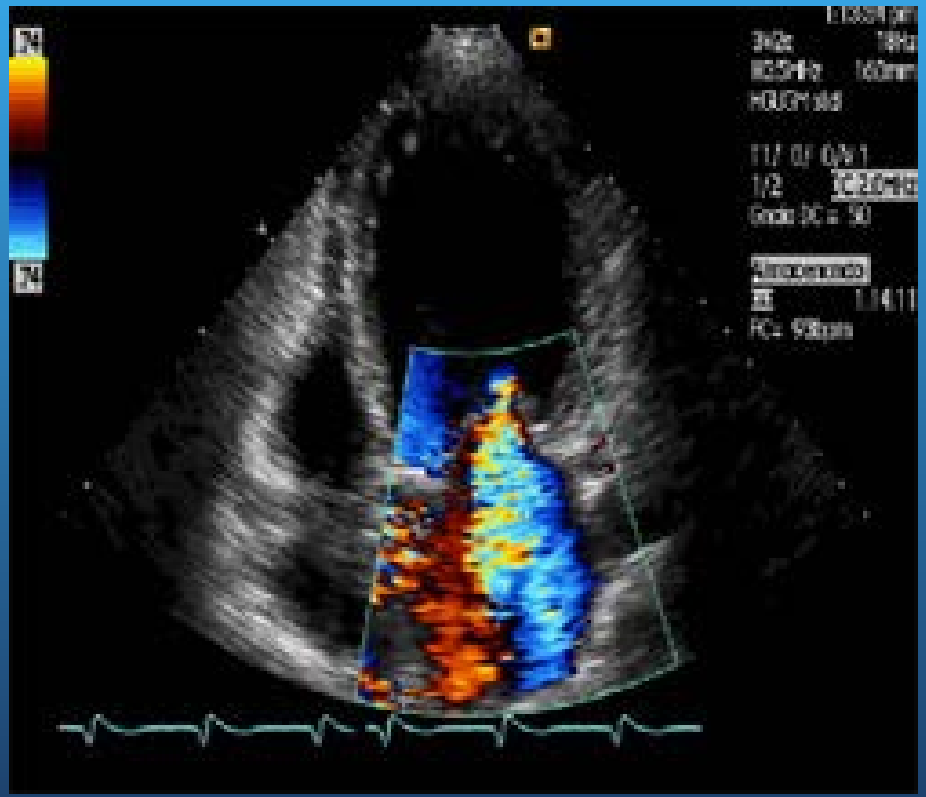

Doppler Color

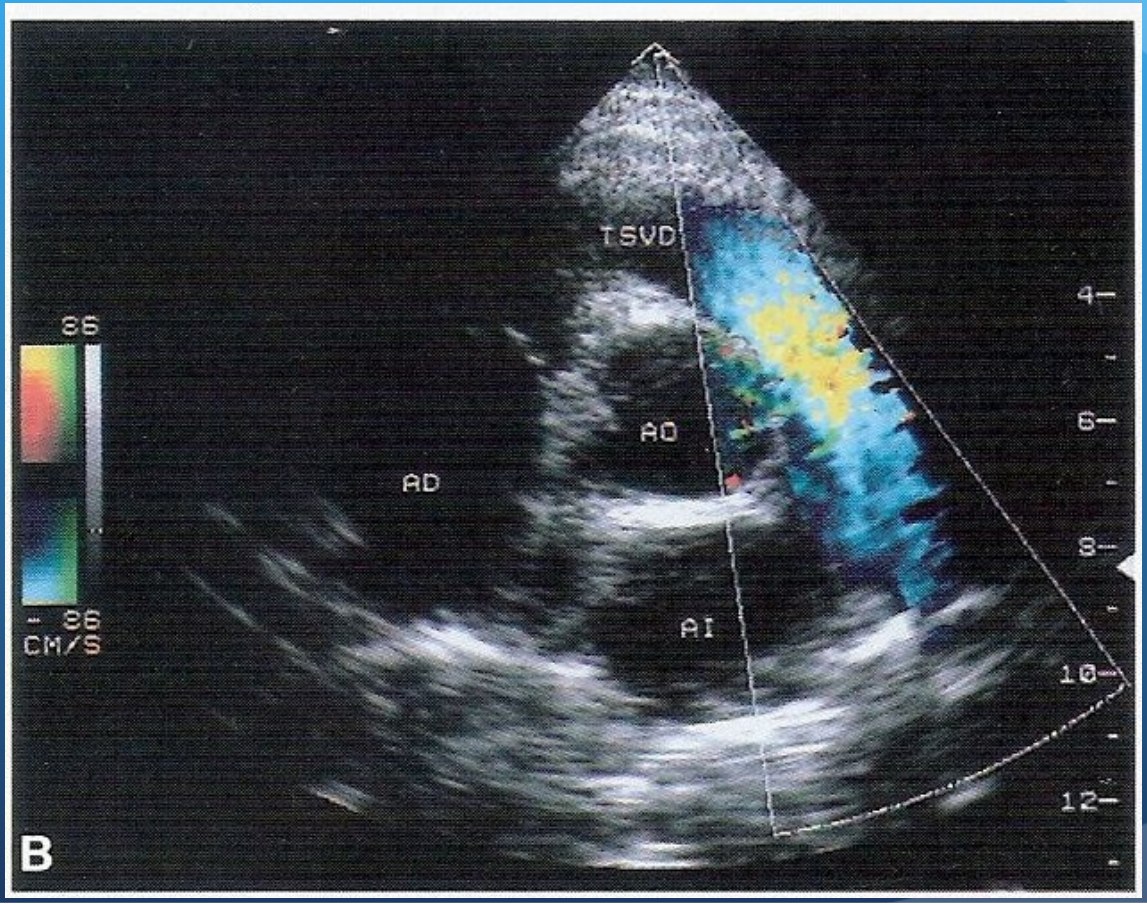

Doppler Color

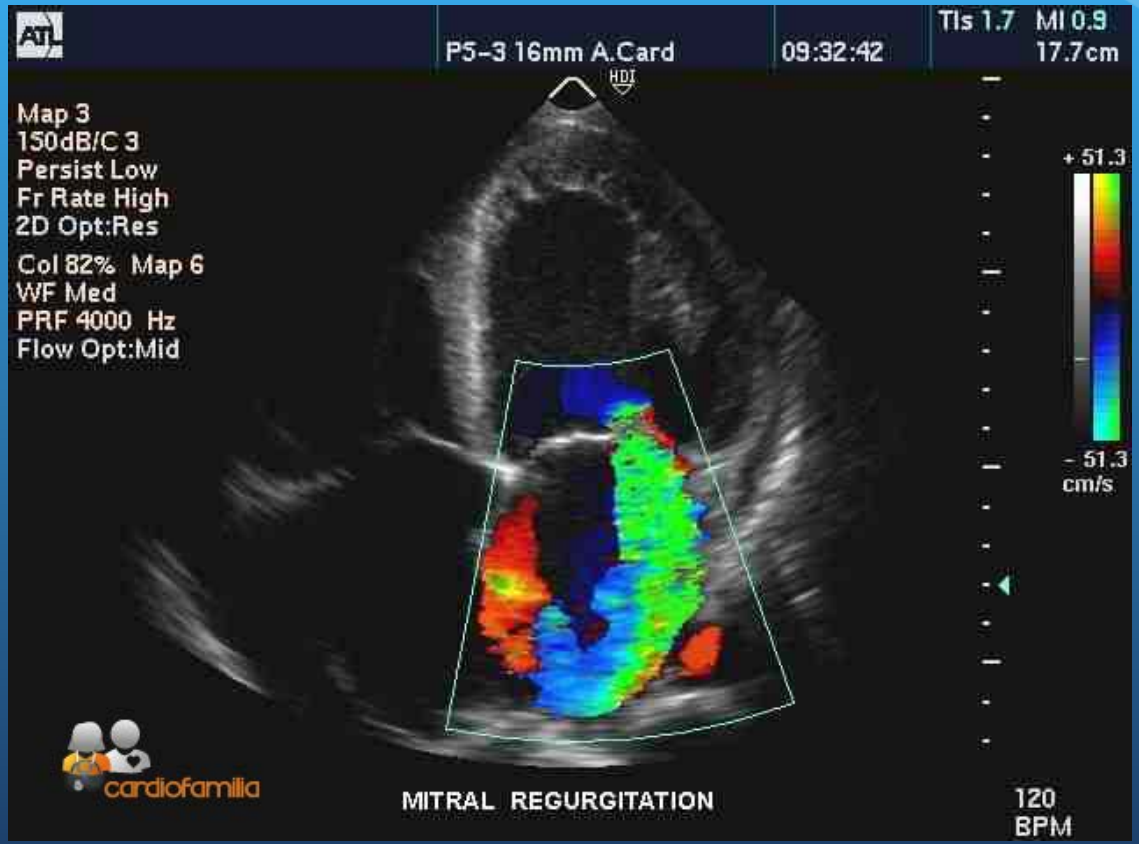

Ecocardiograma 3D

El ultrasonido 3D permite obtener imágenes muy nítidas, con volumen, del corazón y todas sus estructuras anatómicas.

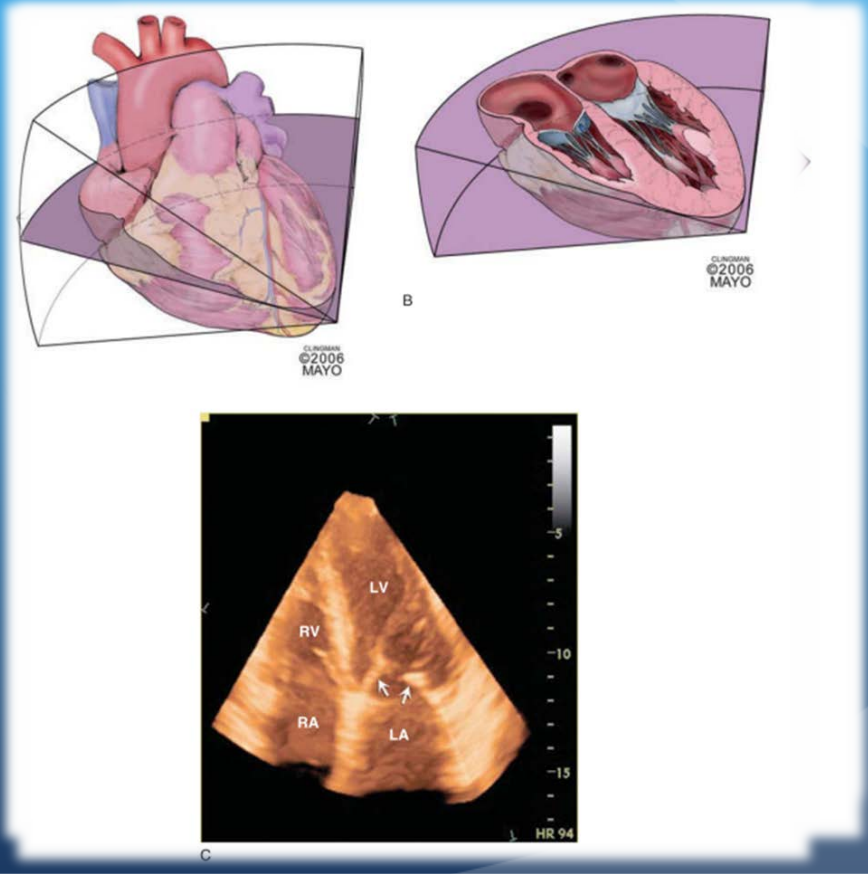

Ecocardiografía Transesofágica

Ecocardiografía Transesofágica

Mejora en muchos aspectos la calidad de la imagen a expensas de ser un procedimiento invasivo.

El transductor se coloca dentro del esófago y el ultrasonido se proyecta hacia las estructuras vecinas.

Ecocardiografía Transesofágica

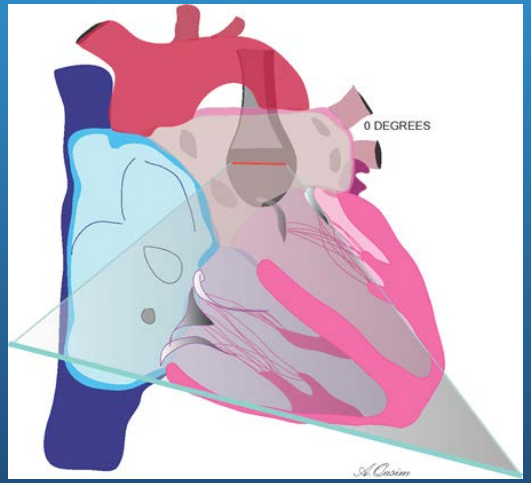

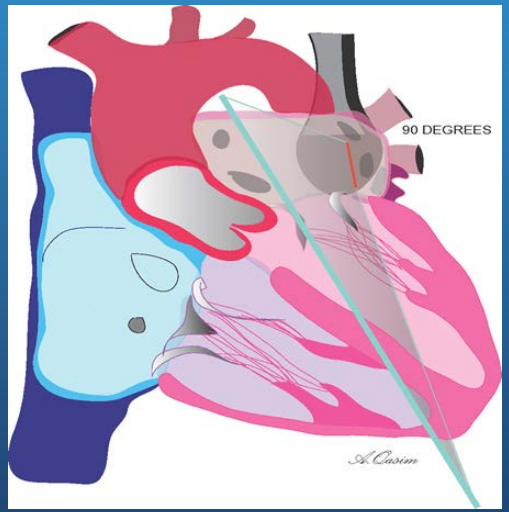

Ecocardiografía Transesofágica

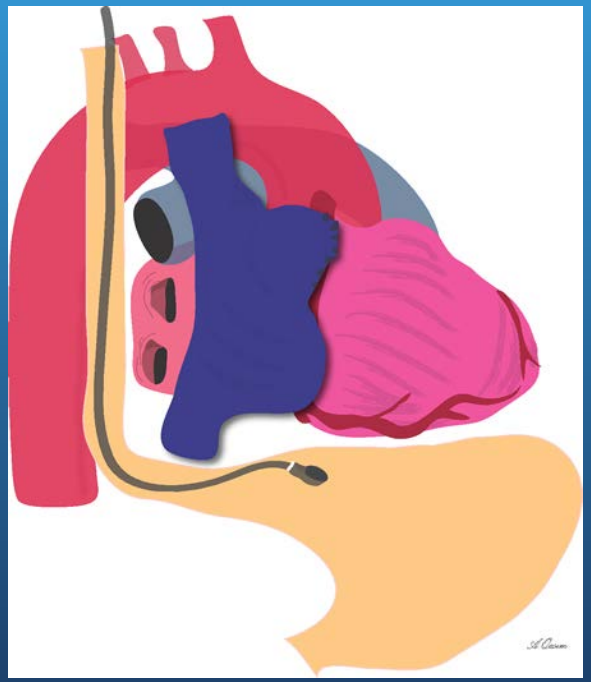

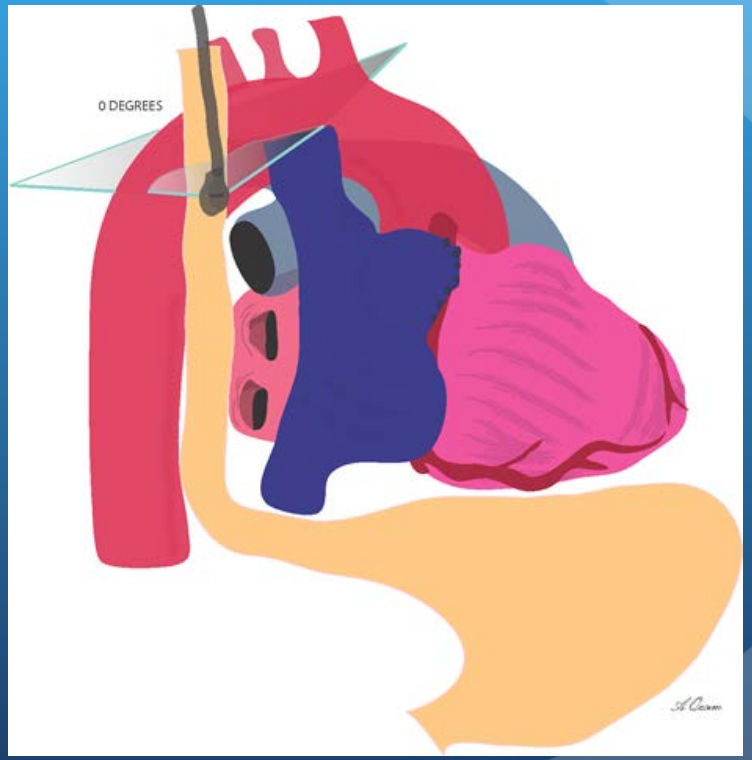

Ecocardiografía Transesofágica

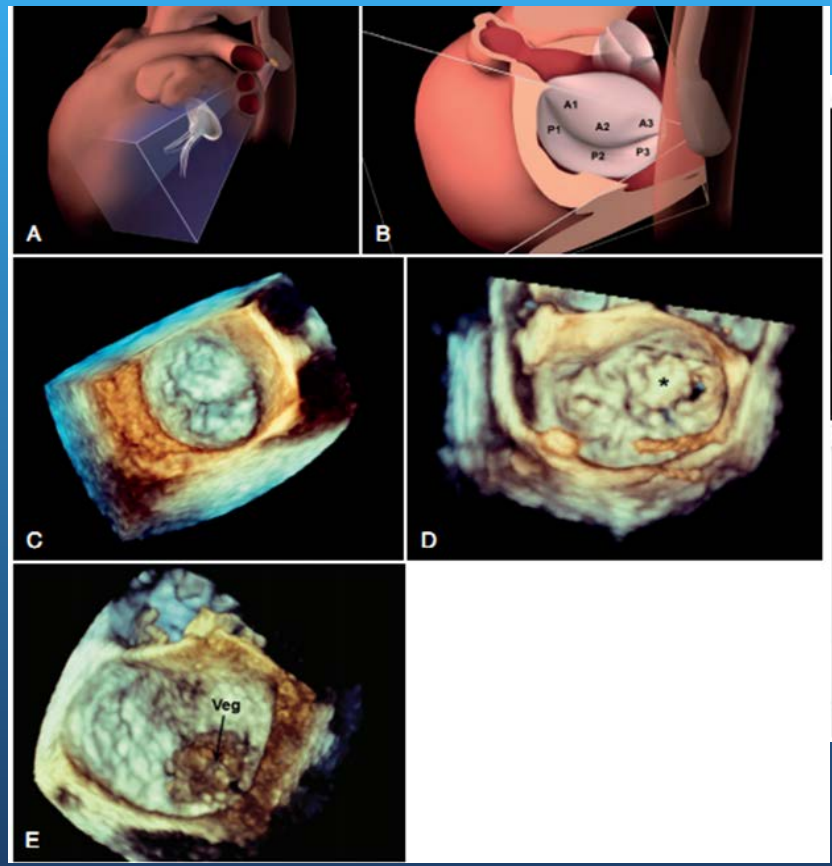

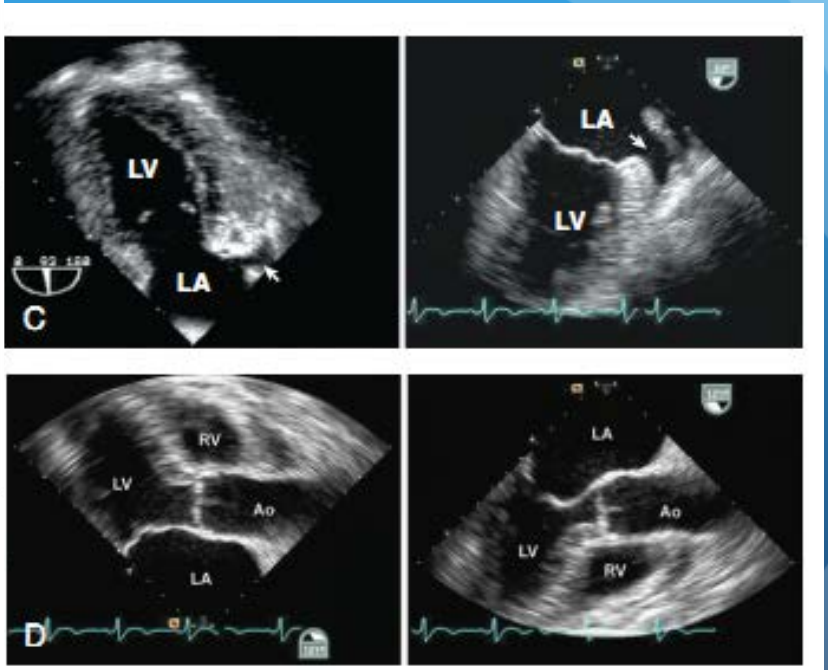

Ecocardiografía Transesofágica

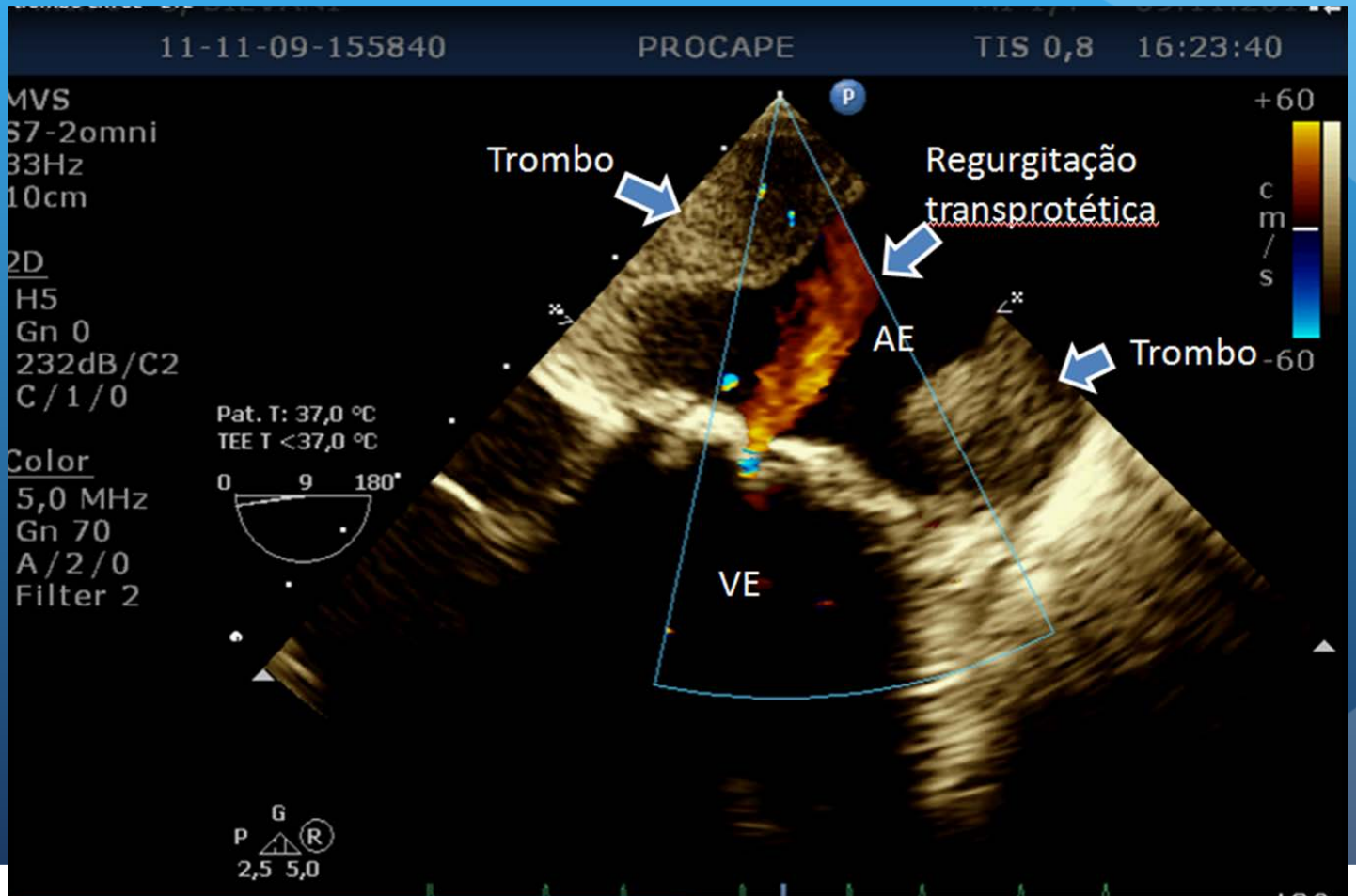

Ecocardiografía Transesofágica

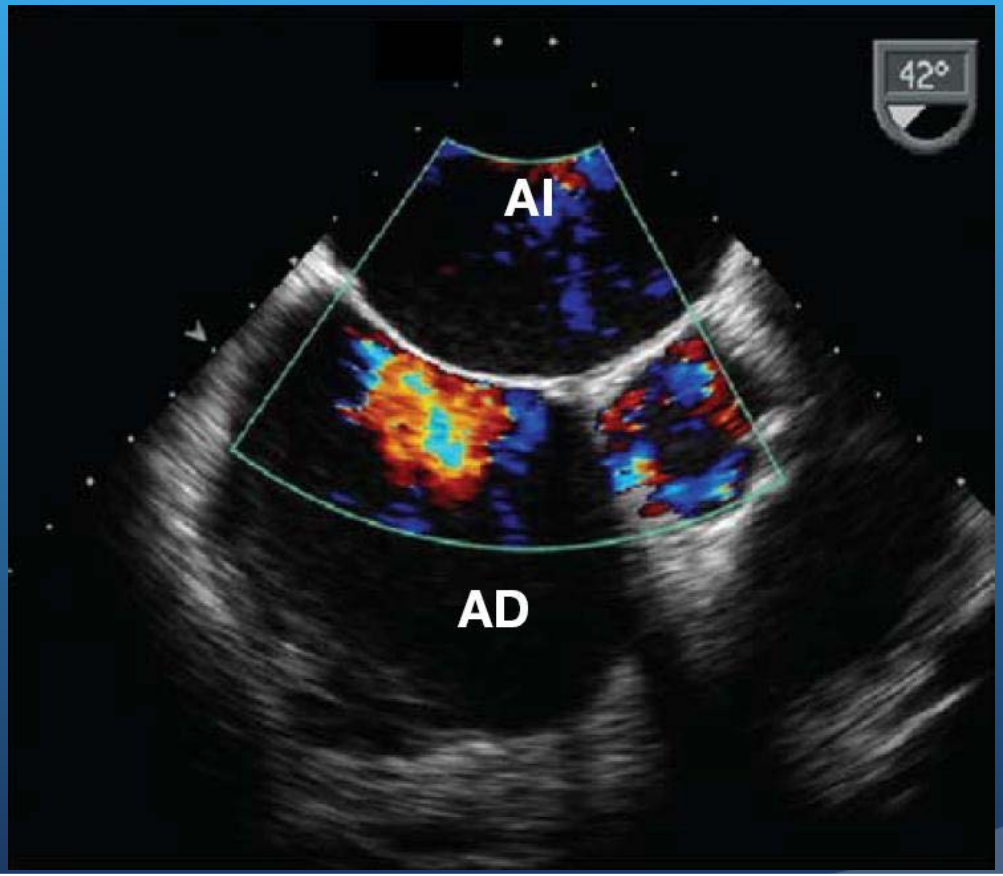

Ecocardiografía Transesofágica

- Buscar fuente cardiaca de un embolo
- Buscar fuente cardiaca de infección
- Evaluar corazón antes, durante y después de una cirugía cardiaca mayor
- Evaluar enfermedades cardiacas congénitas
- Pre cardioversión en pacientes con FA
- Examinación de disección aortica proximal

PATOLOGÍA CARDIACA

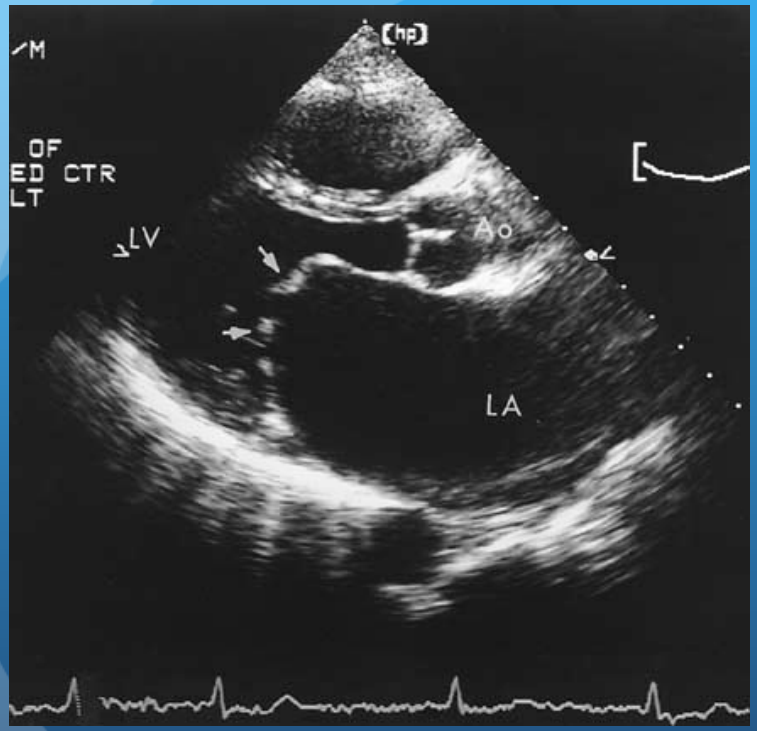

Cardiopatia Reumatica
Estenosis Mitral

Estenosis Mitral

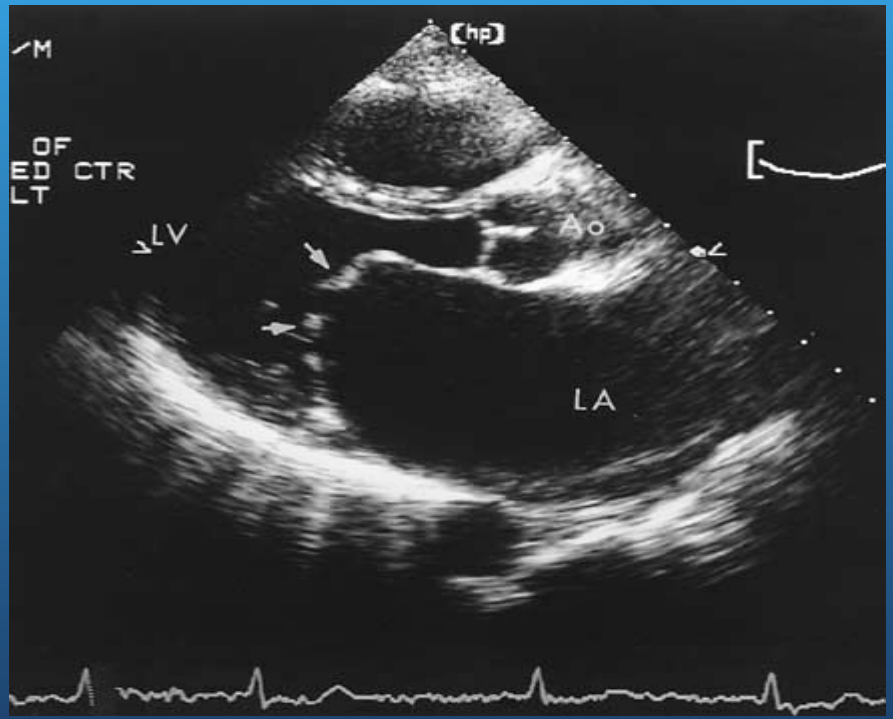

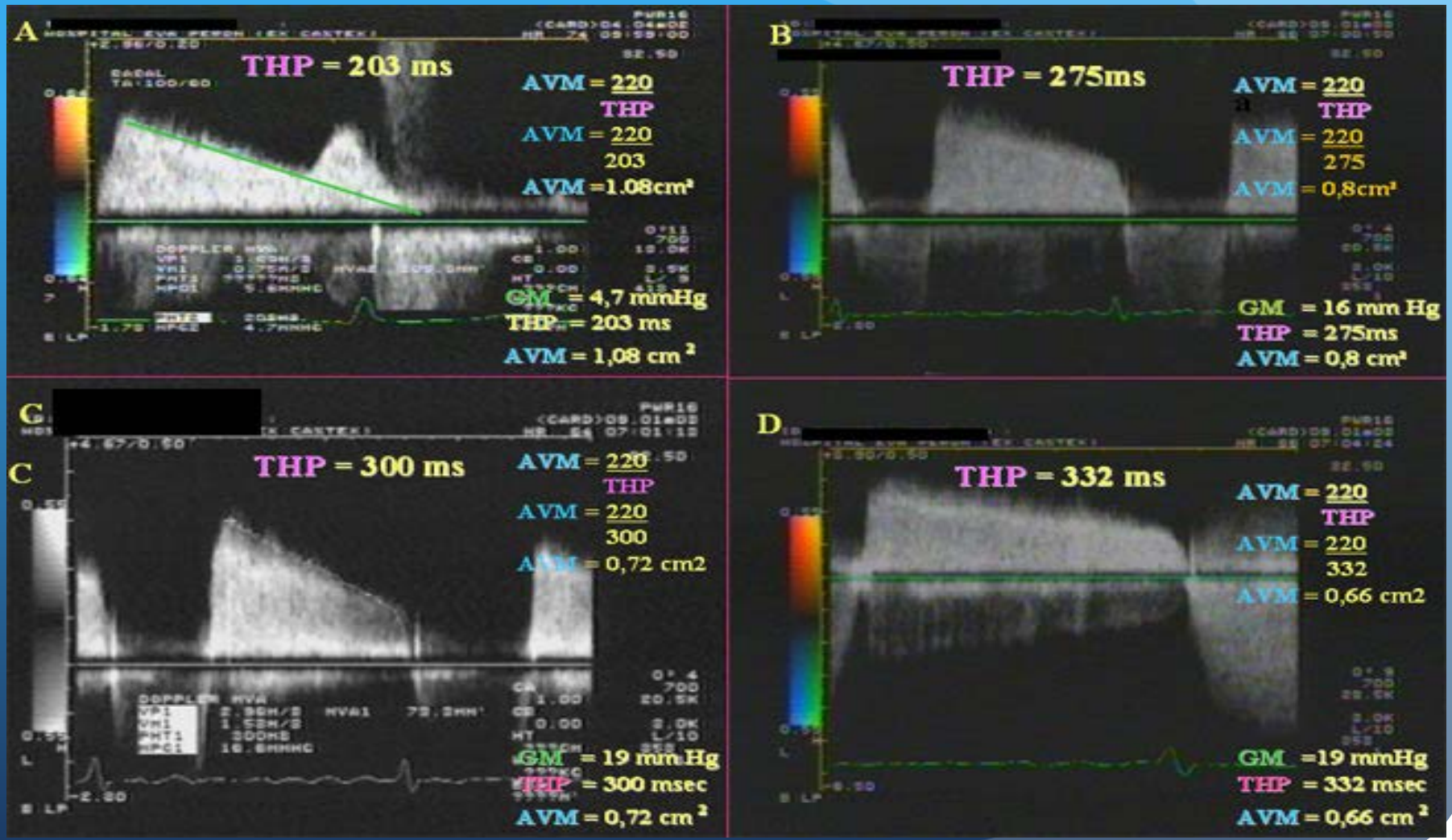
A
THP = 203 ms
AVM = 220
THP
AVM = 220
203
AVM =1.08cm²
GM = 4,7 mmHg
THP = 203 ms
AVM = 1,08 cm²
B
THP = 275ms
AVM = 220
THP
AVM = 220
275
AVM = 0,8cm²
GM = 16 mm Hg
THP = 275ms
AVM = 0,8 cm²
C
THP = 300 ms
AVM = 220
THP
AVM = 220
300
AVM = 0,72 cm2
GM = 19 mm Hg
THP = 300 msec
AVM = 0,72 cm²
D
THP = 332 ms
AVM = 220
THP
AVM = 220
332
AVM = 0,66 cm2
GM =19 mmHg
THP = 332 msec
AVM = 0,66 cm²

Insuficiencia Mitral

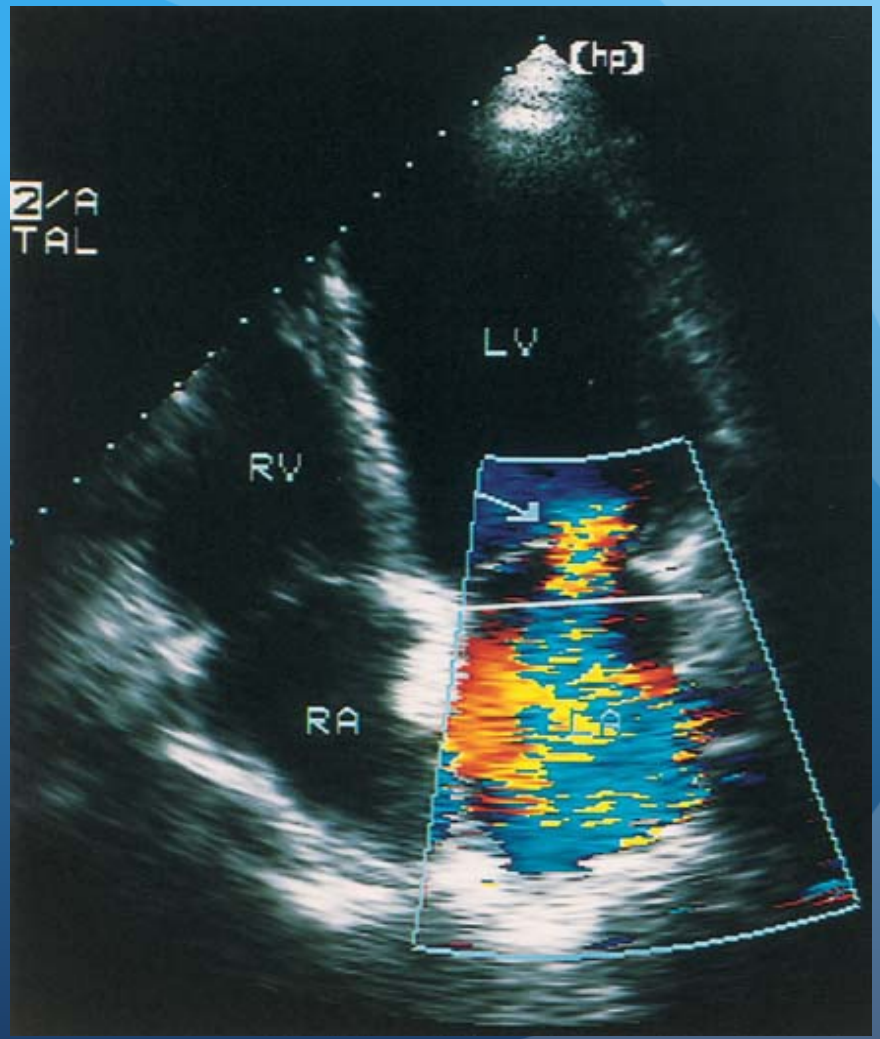

Estenosis aórtica

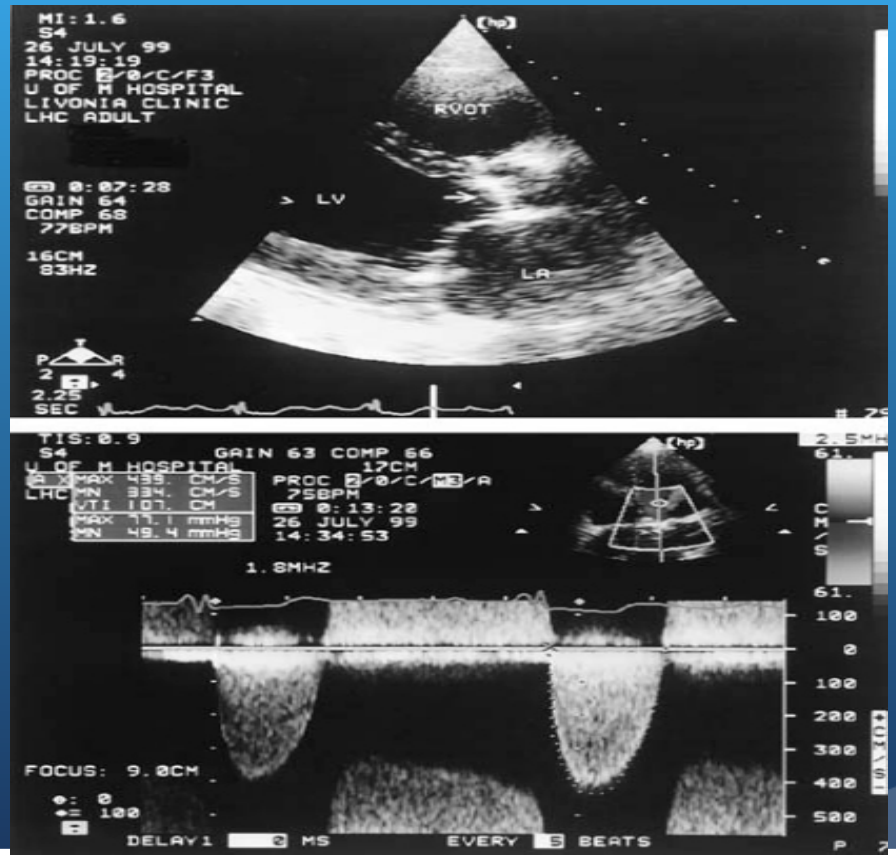

Insuficiencia tricuspídea

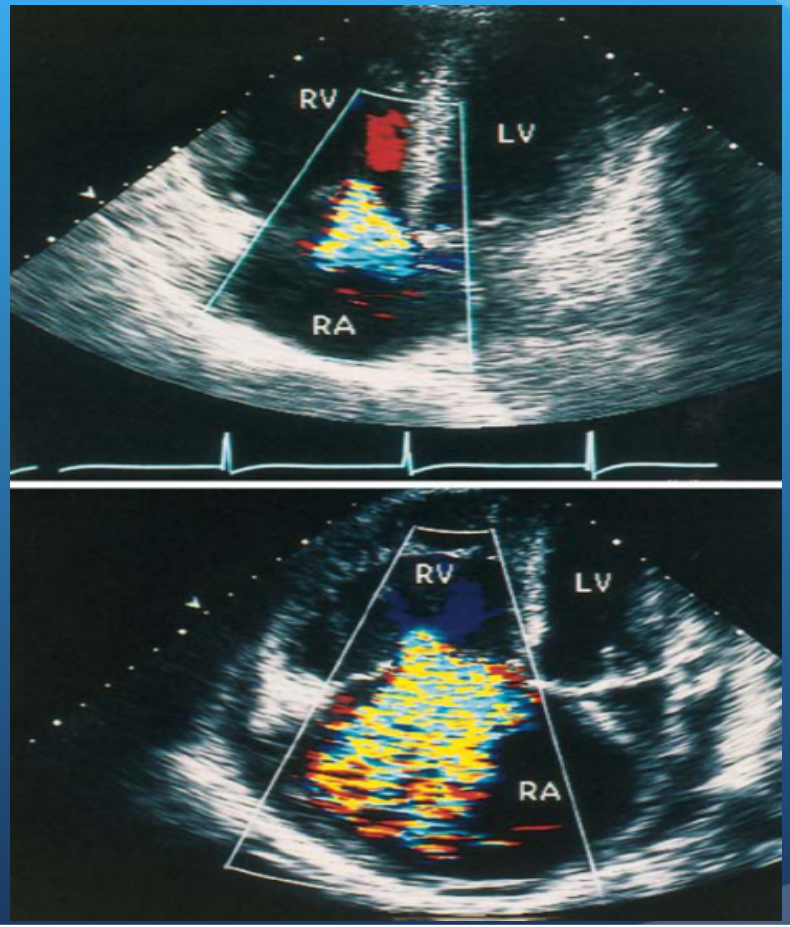

Endocarditis Infecciosa

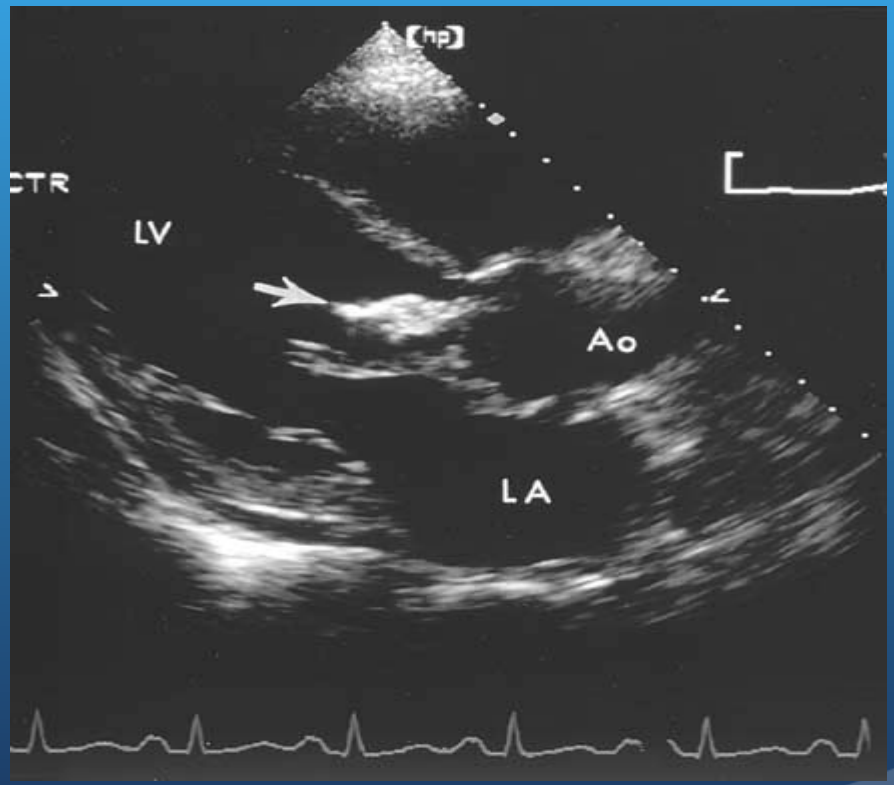

Eco de contraste

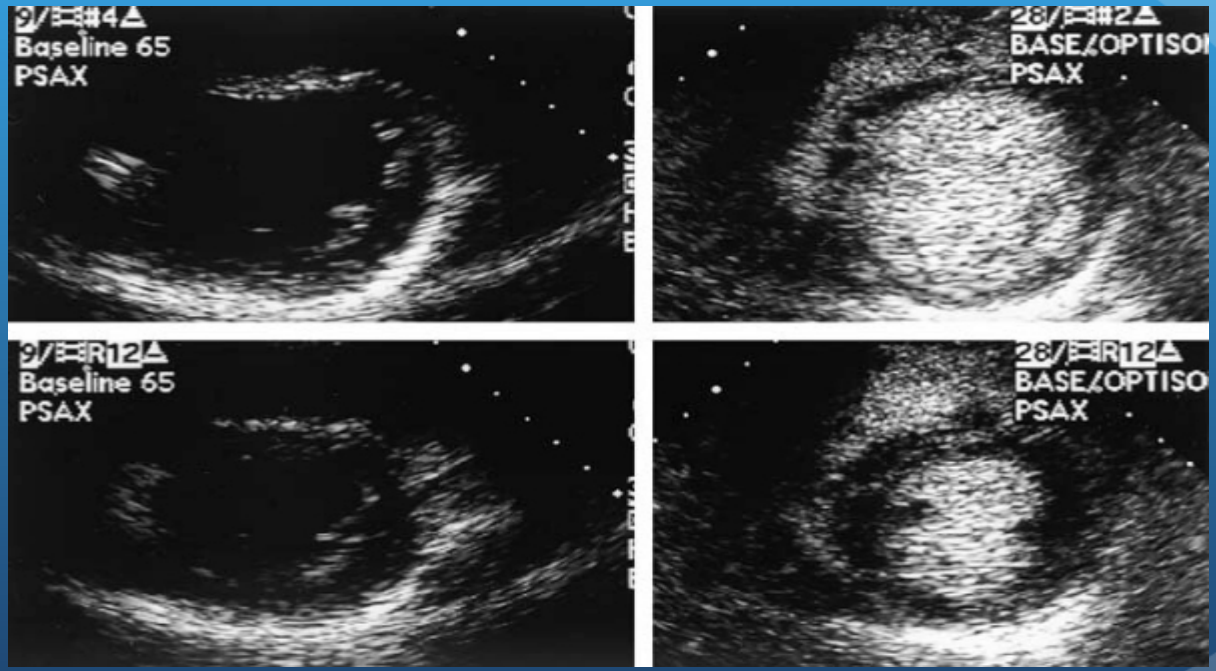

Eco de estrés

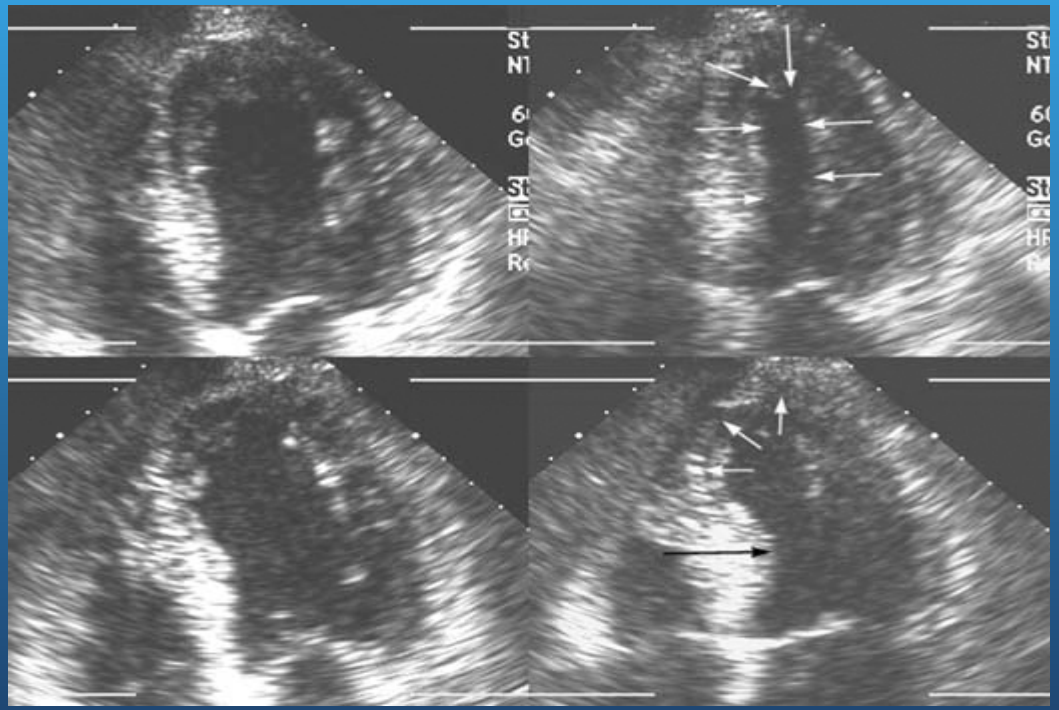

Derrame pericárdico

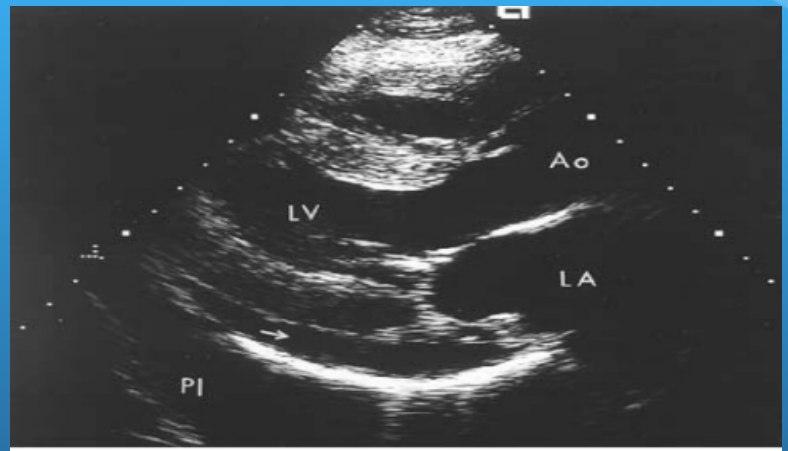

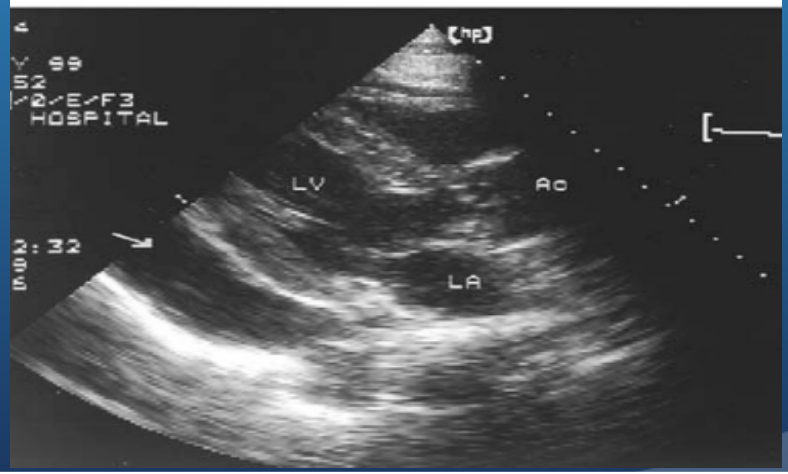

Miocardiopatia Hipertrófica

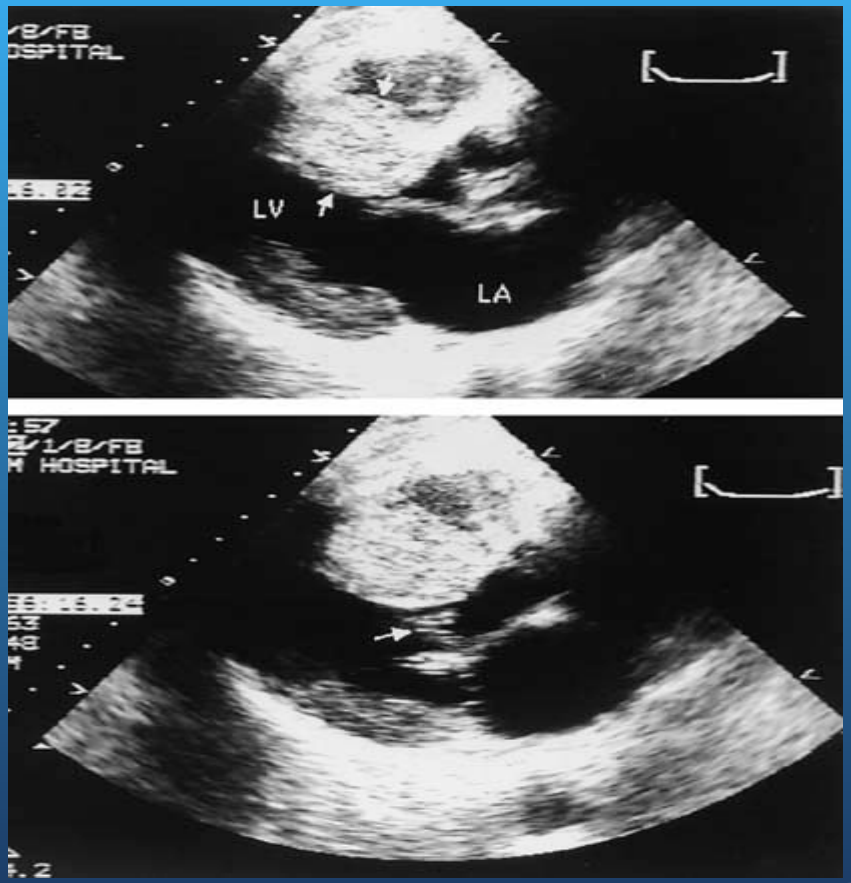

Amiloidosis

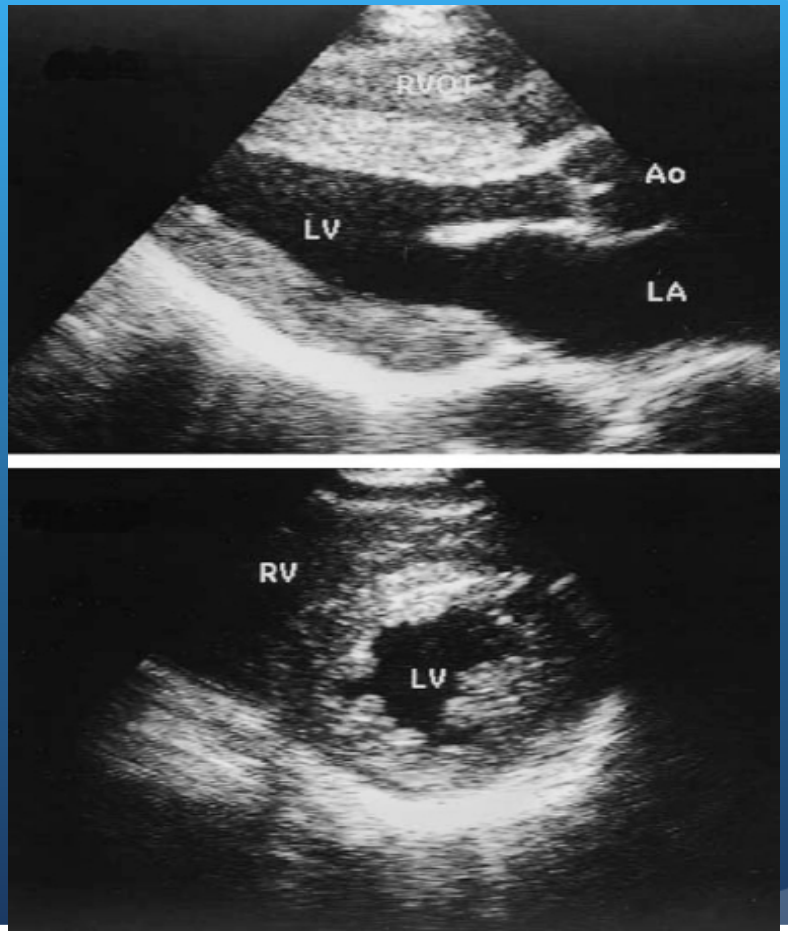

Cardiopatía isquémica

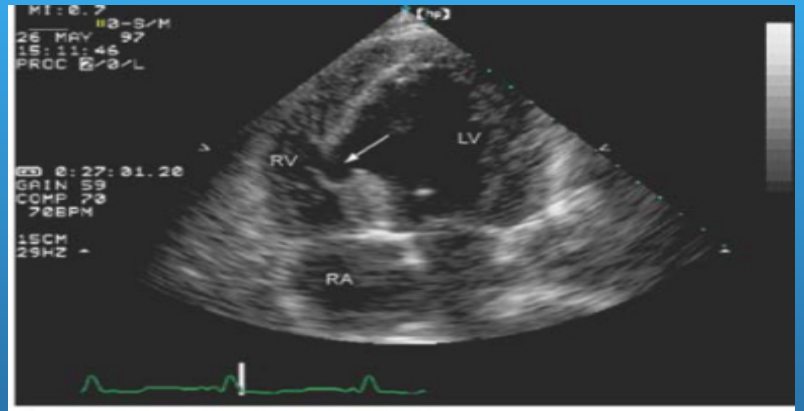

A

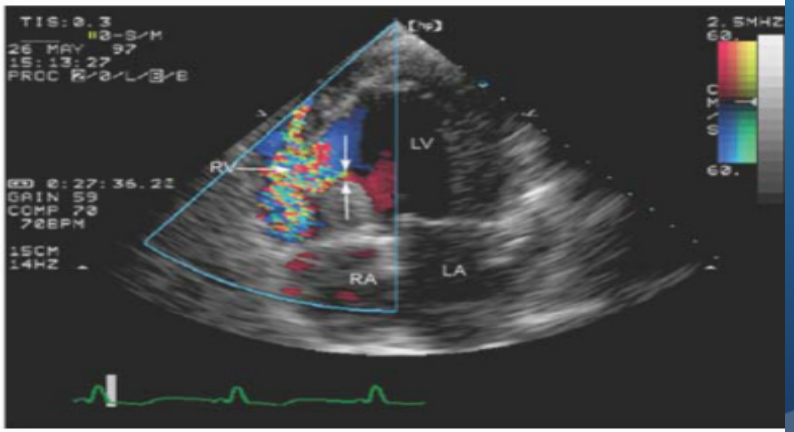

B

Enfermedades aórticas

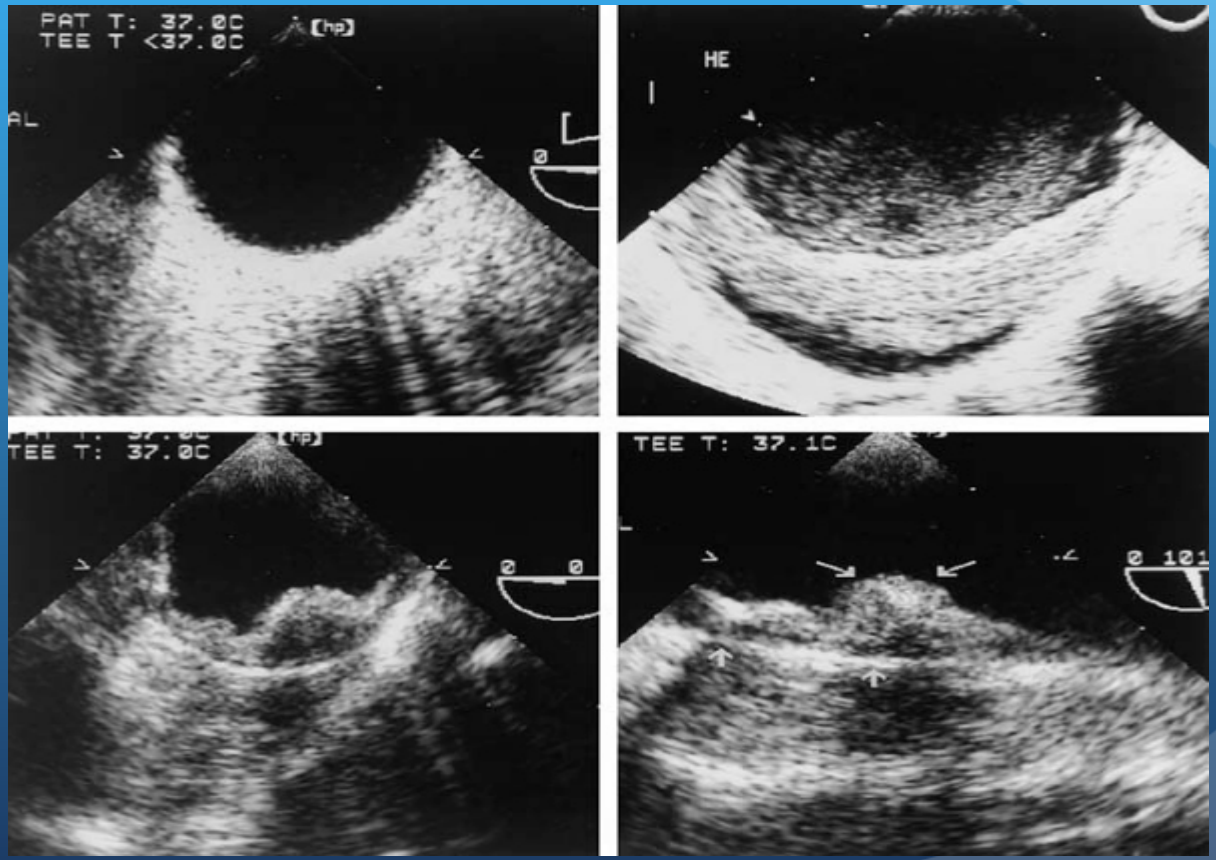

Tumores

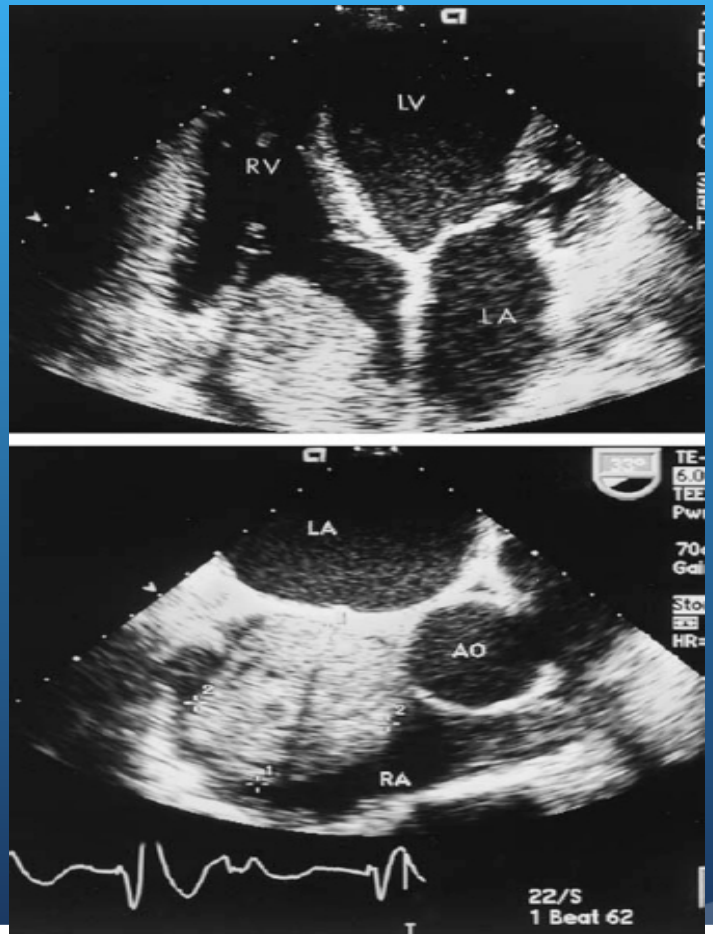

CIA

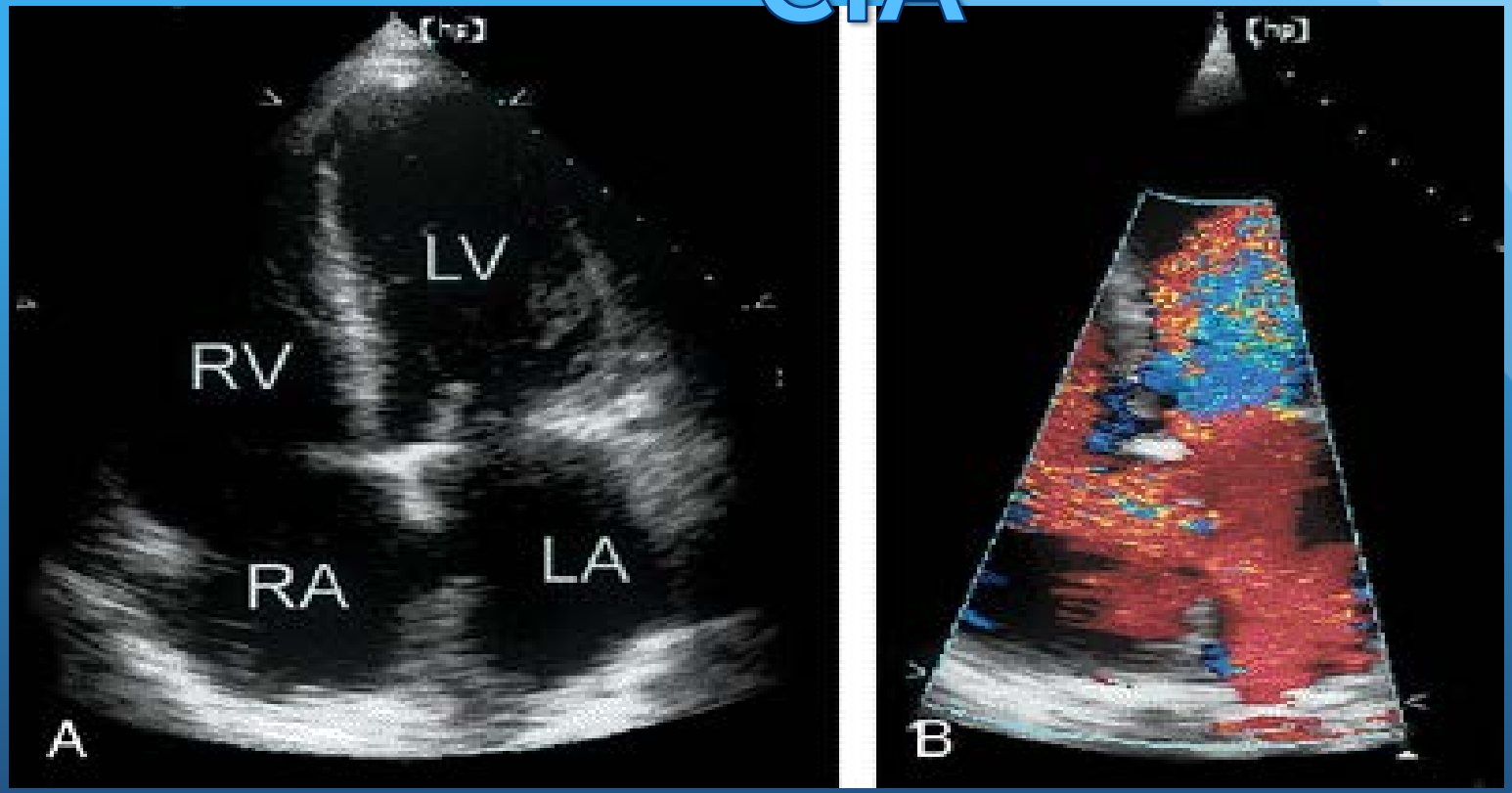

A secundum atrial septal defect is demonstrated from the apical four-chamber view. In this case, the defect is readily apparent on two-dimensional imaging (A). Left-to-right shunting through the defect is confirmed (B) with color Doppler imaging. LA, left atrium; LV, left ventricle; RA, right atrium; RV, right ventricle.

Ecocariograma CIV

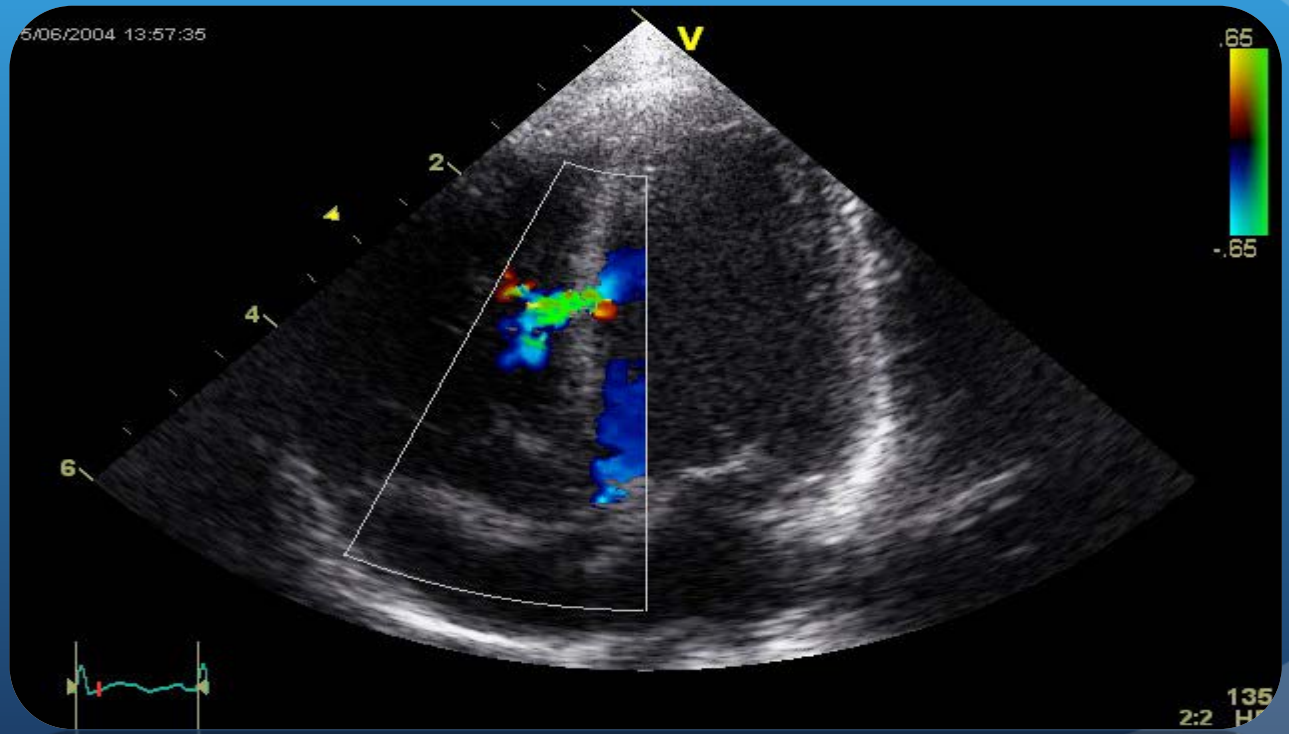

PCA

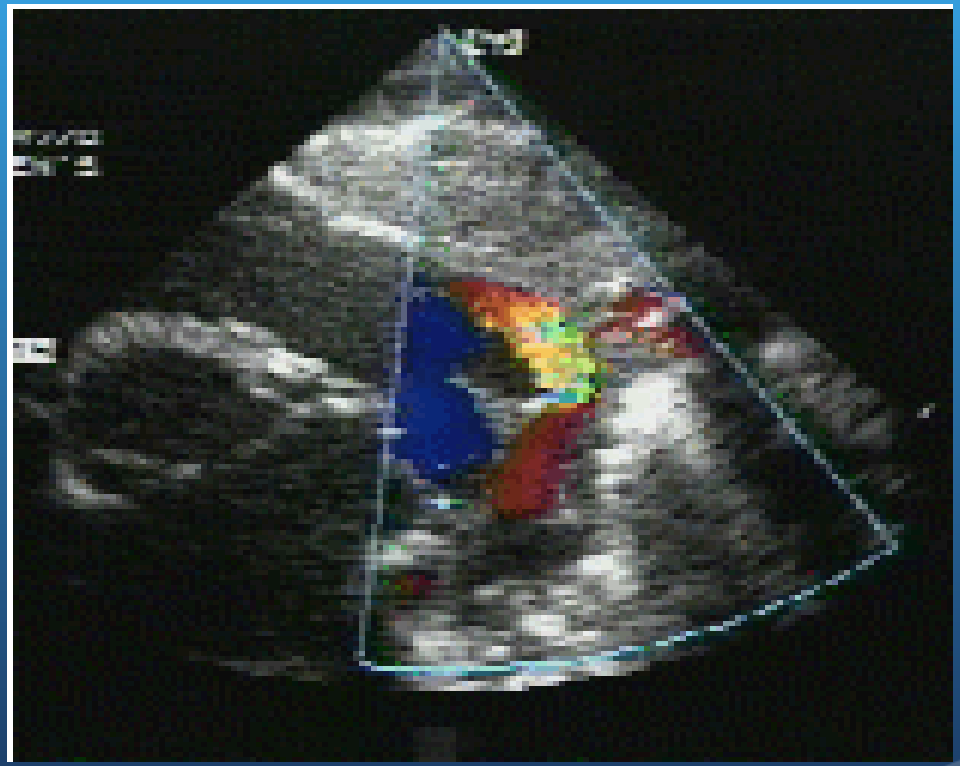

ECO TRIDIMENCIONAL CIA

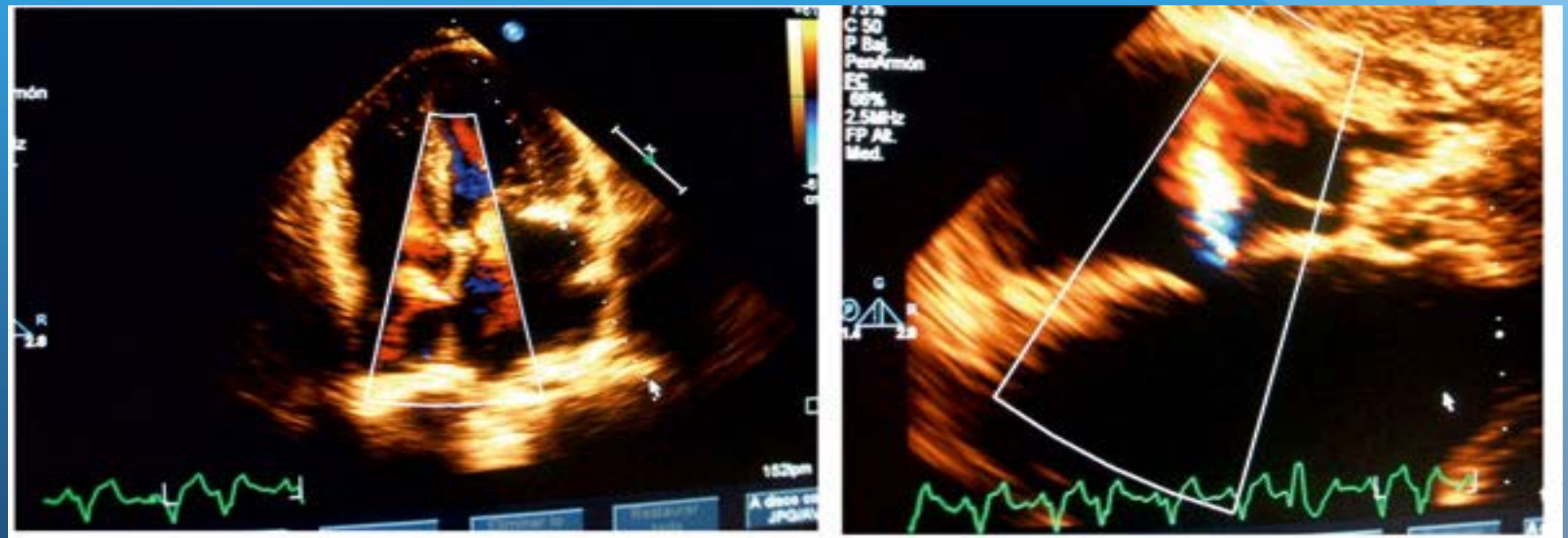

Fig. 4. Comunicación interauricular tipo foramen oval permeable desde vista de 4C apical y subcostal.

ECOCARDIOGRAMA FALLOT:

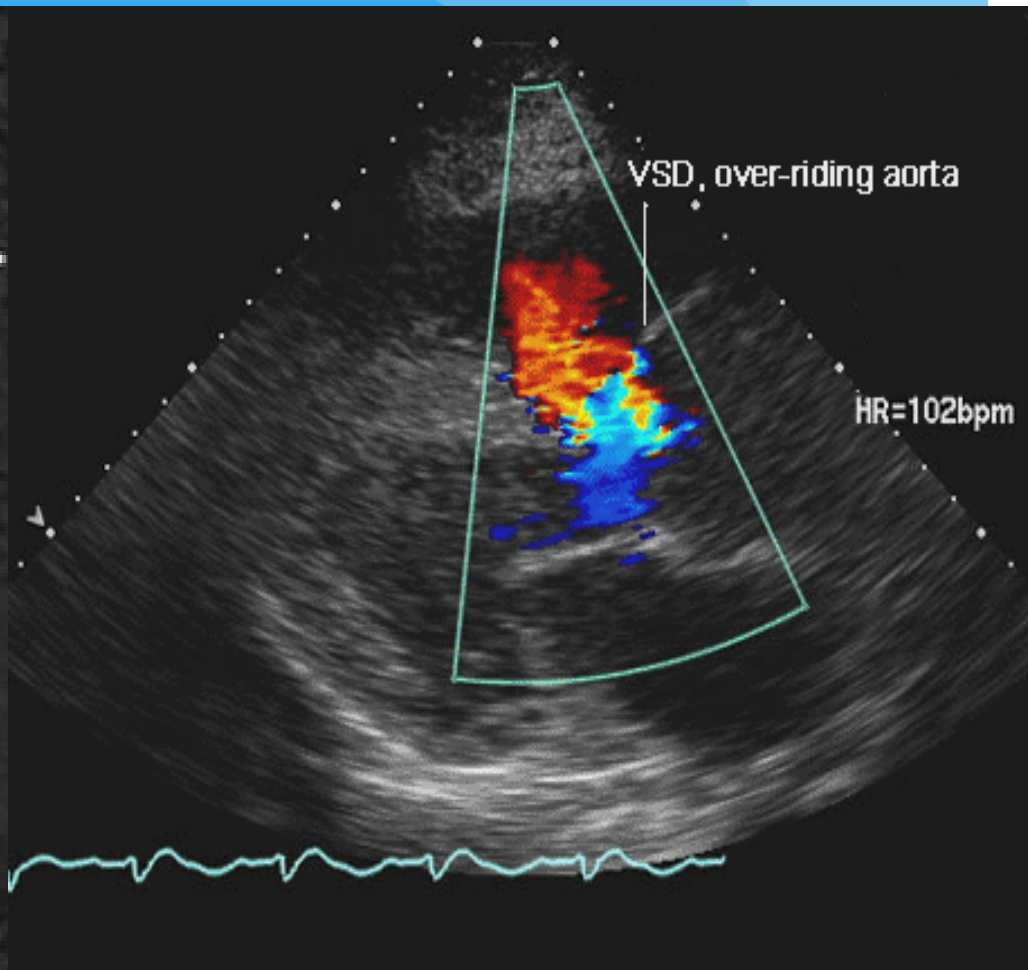

E.EBSTEIN

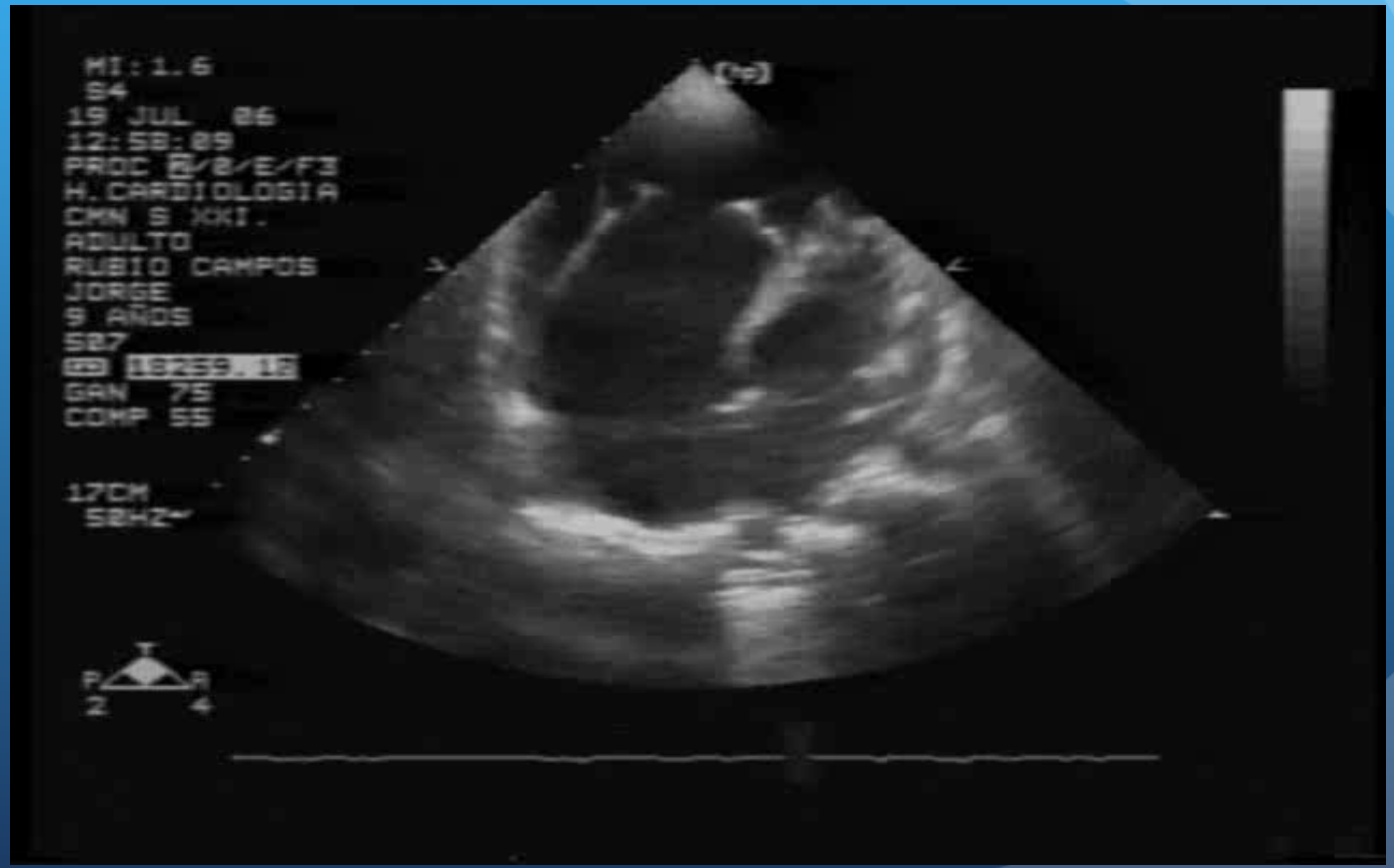
MI:1.6
S4
19 JUL 06
12:58:09
PROC
H.CARDIOLOGIA
CMN S XXI.
ADULTO
RUBIO CAMPOS
JORGE
9 AÑOS
527
GAIN 75
COMP 55
17CM
52HZ
P
A
2
4
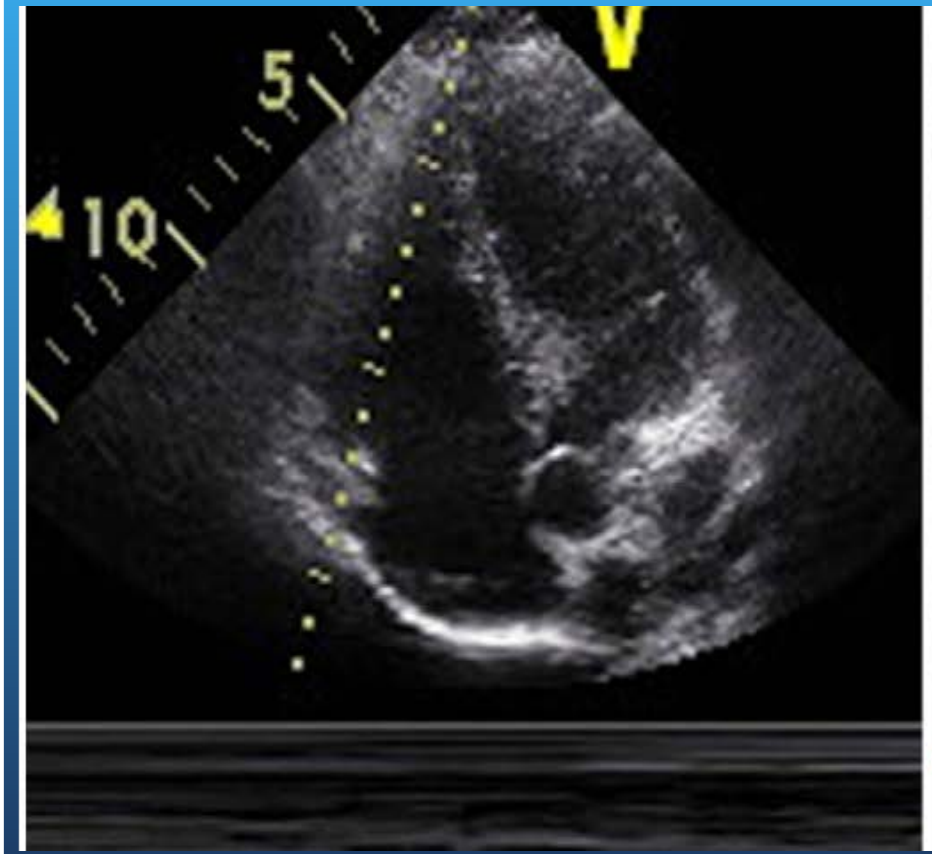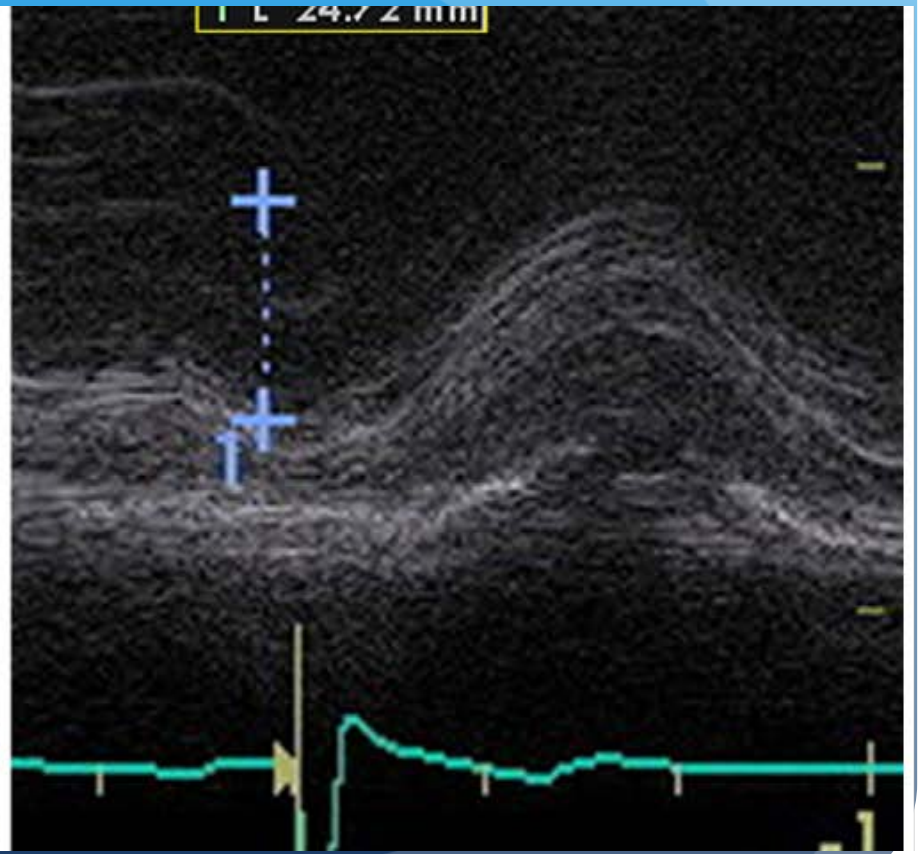
TAPSE